

Crown Fracture of an Unerupted Incisor in a Young Child: Case Report and Restorative Protocol

Deise Kamanski¹, Julieta G Tavares², Joao BB Weber³, Carlos A Feldens⁴, Eduardo G Reston⁵, Patrícia FJS da Cunha⁶, Paulo F Kramer⁷

ABSTRACT

Aim: This case report describes a protocol for restoring a crown fracture of an unerupted permanent incisor in a child.

Background: Crown fractures are an important concern in pediatric dentistry due to the negative impact on oral health-related quality of life (OHRQoL) in children and adolescents resulting from functional limitations as well as consequences related to social and emotional well-being.

Case description: An enamel and dentin fracture of the crown of unerupted tooth 11 due to direct trauma is being presented in a 7-year-old girl. The restorative treatment involved minimally invasive dentistry, including computer-aided design (CAD)/computer-aided manufacturing (CAM) technology and direct resin restoration.

Conclusion: The treatment decision was essential for maintaining pulp vitality and continued root development, as well as ensuring esthetic and functional results.

Clinical significance: Crown fracture of an unerupted incisor may occur in childhood, requiring a long-term clinical and radiographic follow-up. Predictable, positive, and reliable esthetic outcomes can be achieved using CAD/CAM technology combined with adhesive protocols.

Keywords: Case report, Composite resins, Computer-aided design, Tooth, Tooth injuries, Unerupted.

International Journal of Clinical Pediatric Dentistry (2022); 10.5005/jp-journals-10005-2437

BACKGROUND

Traumatic dental injuries (TDIs) are the fifth most prevalent adverse health condition in the world, have a negative impact on OHRQoL, and are associated with high treatment costs for individuals and society.¹⁻⁴ Crown fractures are the most frequent type of injury in the permanent dentition and are usually the result of direct trauma, in which the tooth was struck by the impacting object.^{5,6}

Although rare, crown fracture of a permanent incisor may occur before the eruption of the tooth.^{7,8} Such injuries are more likely the result of direct trauma to the unerupted tooth rather than indirect trauma stemming from damage to the primary tooth. Andreasen's classification of anatomical and histological deviations of developing teeth does not include injuries that may occur as a result of an impacting object directly striking the developing tooth itself.⁹

There is a growing consensus that outcomes need to be relevant not only to clinicians and policymakers but also to patients. Crown fractures are associated with difficulty eating and smiling as well as episodes of pain and/or sensitivity and can exert a negative impact on certain domains of OHRQoL, such as functional limitations and emotional and social well-being.¹⁰⁻¹² Studies have also shown that restorative treatment for crown fractures in children and adolescents can contribute to improvements in oral health outcomes.^{13,14}

A minimally invasive dental practice is a more conservative approach that preserves natural tooth structure and ensures a fast, tolerable procedure for pediatric patients. Moreover, digital techniques have become increasingly integrated into restorative procedures.¹⁵

The aim of this report is to present the conservative restoration on an unerupted central incisor with a crown fracture using

^{1-3,6}Department of Pediatric Dentistry, School of Health and Life Science, Pontifícia Universidade Católica do Rio Grande do Sul, Porto Alegre, Rio Grande do Sul, Brazil

^{4,5}Department of Pediatric Dentistry, School of Dentistry, Universidade Luterana do Brasil (ULBRA), Canoas, Rio Grande do Sul, Brazil

⁷Department of Pediatric Dentistry, School of Health and Life Science, Pontifícia Universidade Católica do Rio Grande do Sul, Porto Alegre, Rio Grande do Sul, Brazil; Department of Pediatric Dentistry, School of Dentistry, Universidade Luterana do Brasil (ULBRA), Canoas, Rio Grande do Sul, Brazil

Corresponding Author: Joao BB Weber, Department of Pediatric Dentistry, School of Health and Life Science, Pontifícia Universidade Católica do Rio Grande do Sul, Porto Alegre, Rio Grande do Sul, Brazil, Phone: +5551992860758, e-mail: joaoblessmann@gmail.com

How to cite this article: Kamanski D, Tavares JG, Weber JBB, et al. Crown Fracture of an Unerupted Incisor in a Young Child: Case Report and Restorative Protocol. *Int J Clin Pediatr Dent* 2022;15(5):636-641.

Source of support: Nil

Conflict of interest: None

CAD/CAM technology to achieve optimal long-term functional and esthetic outcomes.

CASE DESCRIPTION

A 7-year-old girl was examined at the pediatric dental clinic of the School of Health, and Life Science of the Pontifical Catholic University of Rio Grande do Sul, Brazil, due to a traumatic dental injury that occurred the day before. The patient reported having fallen from a slide and suffering an injury in the anterior maxillary, which caused immediate bleeding. The patient's mother reported

that the child had no primary anterior teeth at the time of the accident and could not recall the occurrence of any TDI during the time of the primary dentition. No medication or any type of symptomatic treatment was prescribed to the affected area.

The extraoral examination showed a small abrasion on the lower lip. The intraoral examination revealed a hematoma and laceration in the region of the right maxillary central incisor (unerupted tooth 11). Through the periapical radiographic exam was possible to observe a crown fracture in the incisal third and the incomplete root formation of tooth 11 (Fig. 1). The initial diagnosis was enamel and dentin fracture of the crown of unerupted tooth 11 due to direct trauma. The tooth fragment was not recovered from the accident environment.

The treatment strategy involved clinical and radiographic follow-up with an emphasis on the eruption process and root formation of the maxillary central incisors. The patient and mother were counseled to clean the affected area with a soft toothbrush and use an alcohol-free 0.12% chlorhexidine gluconate mouth rinse applied topically twice a day for 1 week. Each follow-up session involved asking the patient about any signs or symptoms, as well as clinical and radiographic examinations and pulp sensitivity testing. Photographic documentation was also performed.

On the second visit (1 week after the first visit), tooth 11 had erupted, revealing a noncomplicated enamel and dentin fracture with no pulp exposure. The patient reported no sensitivity, and after a discussion on the immediate treatment options, the family decided against a temporary restoration. Further follow-up sessions were held 21, 60, and 120 days as well as 6 months after the occurrence of the injury (Fig. 2).

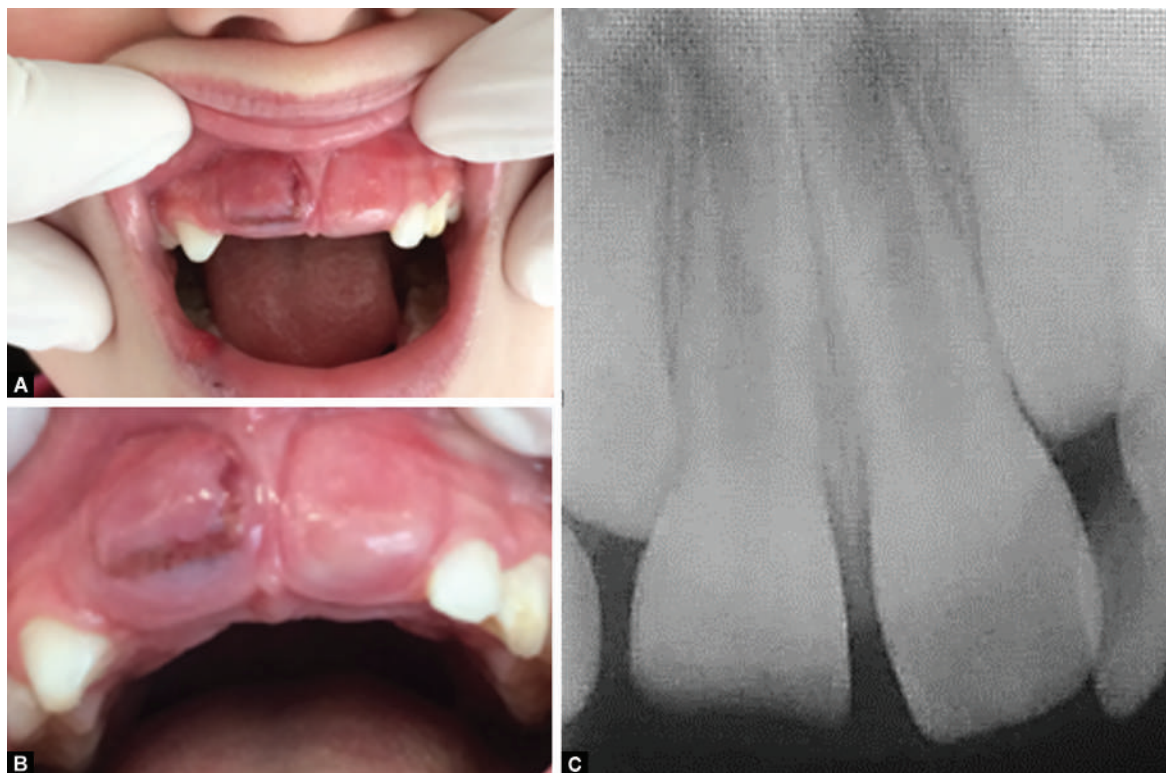
After 1 year, the continuity of the eruption process was verified, and the pulp sensitivity test (Endo Ice Spray, Maquira, Maringá,

Paraná, Brazil) was positive. The periapical radiographic exam revealed no signs of root resorption, apical inflammatory lesion, or obliteration of the root canal. Moreover, normal root formation was observed (Fig. 3). The patient reported being dissatisfied with her appearance, especially in comparison to her twin sister. This dissatisfaction and the favorable prognosis influenced the decision for esthetic-functional rehabilitation.

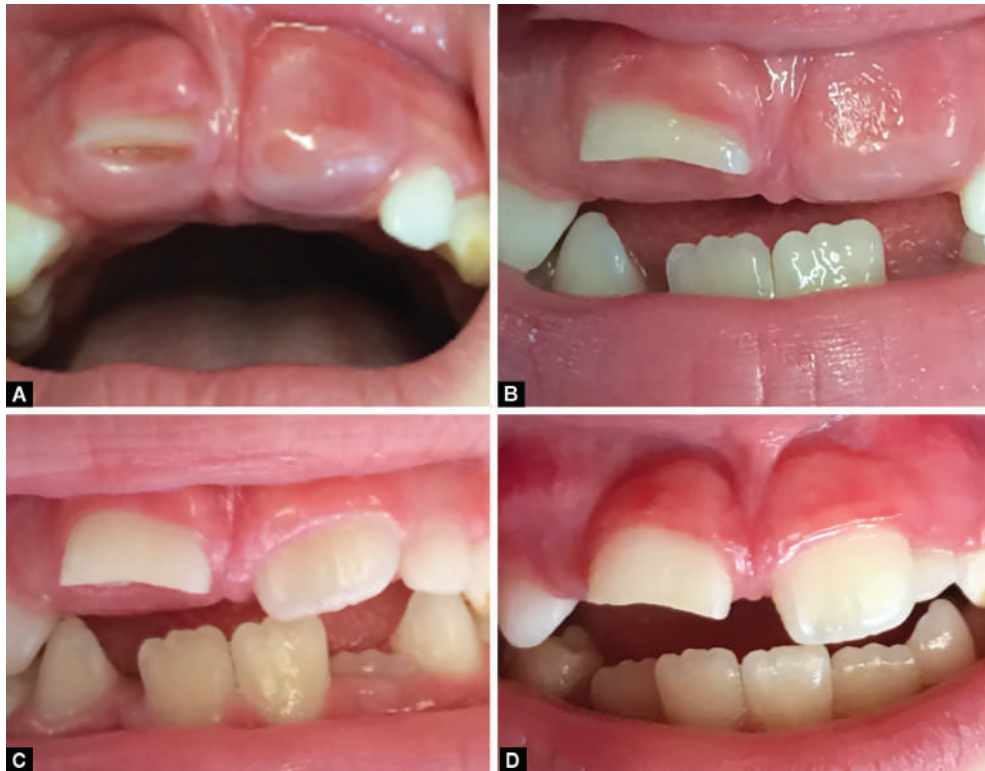Computer-assisted design/computer-assisted manufacturing (CAD/CAM) was used to enhance the precision of the restorative procedure based on the similarity between identical twins, including identical tooth anatomy. The scanning of the oral structures of the patient and her twin sister was performed by using Cerec Primescan (Dentisply Sirona, Bensheim, Germany) to obtain a biogeneric copy of the sister as the anatomic reference for the creation of the digital model. A guide was made with Exaflex addition silicone (GC America Inc., Alsip, Illinois, United States of America) from the digital model (Fig. 4).

After selecting the shades of the composite resin, absolute rubber dam isolation of the operating field was performed, followed by etching the surface with 37% phosphoric acid (Ultra-Etch, Ultradent Products Inc, Salt Lake City, Utah, United States of America) for 15 seconds on the enamel and dentin, then washing-off for 1 minute, and strategic drying of the dentin (and enamel) with air and a cotton ball. Next, two layers of Adper Single Bond Plus (3M ESPE, Saint Paul, Minnesota, United States of America) were applied and air-blown for the volatilization of the solvent and spreading of the adhesive. Light-curing was then performed for 20 seconds.

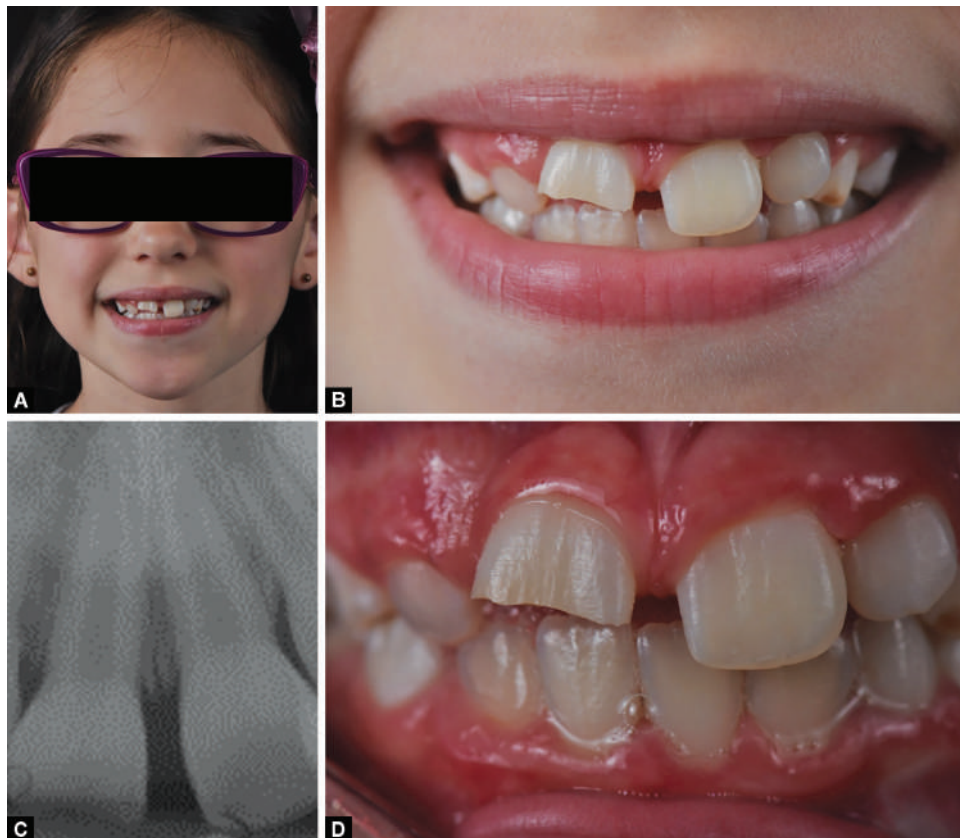
The reproduction of the enamel of the lingual surface was then initiated with a thin layer of Filtek Z350 XT resin (3M ESPE, Saint Paul, Minnesota, United States of America) (color: XWE) applied to the guide and positioned on the tooth. After photoactivation



Figs 1A to C: (A) Clinical aspect 24 hours after trauma, showing hematoma on the alveolar ridge in the region of unerupted tooth 11; (B) Clinical aspect of the alveolar ridge laceration; (C) Periapical radiograph, revealing incomplete root formation and crown fracture on tooth 11



Figs 2A to D: Clinical aspect of the eruption of teeth 11 and 21. (A) 7 days follow-up; (B) 21 days follow-up; (C) 60 days follow-up; (D) 6 months follow-up



Figs 3A to D: (A) 8-year-old girl; (B) Clinical aspect 12 months after trauma, revealing eruption of teeth 11 and 21; (C) Radiographic aspect 12 months after trauma, revealing root formation of teeth 11 and 21 and (D) Clinical close-up image

of the lingual enamel, the dentinal area was built with Filtek Z350 XT resin (3M ESPE) (color: WB). Translucent resin (Iridescent Blue da Vit-I-essence, Ultradent, South Jordan, Utah, United States of America) was used to create the incisal edge, and Filtek Z350 XT resin (3M ESPE) (color: XWB) was used for the opaque white incisal edge. For the last layer, XWE and B1E Filtek Z350 XT resins (3M ESPE) were applied with a flat, thin spatula (SafiDent; Cosmedent, Chicago, Illinois, United States of America) and burnished with a flat brush, reproducing the vestibular enamel (Fig. 5).

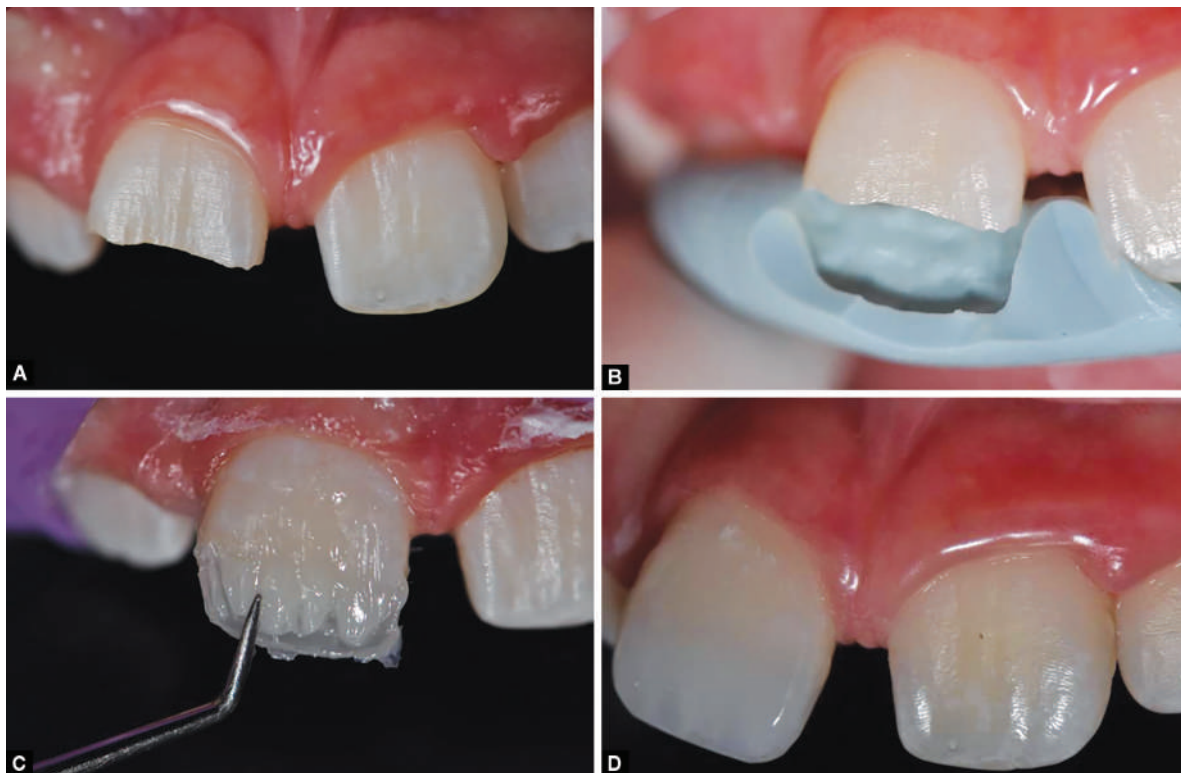
The contact points were verified using extra-thin double-sided carbon paper (AccuFilm, Wilcos, Petrópolis, Rio De Janeiro, Brazil) in the centric relation position, right and left excursion and

protrusion. Sof-Lex finishing disks (3M ESPE, Saint Paul, Minnesota, United States of America), a multifaceted Komet bur for composite resin (H375RH018; Santo André, São Paulo, Brazil), and Enamelize polishing paste (Cosmedent, Chicago, Illinois, United States of America) were used for finishing and polishing the restoration. The patient was extremely satisfied with the result (Fig. 6).

At a visit 1 year after treatment, function and esthetics remained satisfactory, the pulp test was recorded as positive, and the periapical radiograph showed continued root development with no pathological findings. Patient compliance with follow-up visits and home care contributes to the longevity and success of restorative treatment for crown fractures (Fig. 7).



Figs 4A to C: (A) Scanning of oral structures of the patient; (B) Twin sisters and (C) Scanning of oral structures of her sister



Figs 5A to D: (A) Initial clinical aspect; (B) Silicone guide positioned on the tooth; (C) Incremental insertion of composite resin and (D) Final clinical aspect of restoration of crown fracture of tooth 11

Informed consent was signed authorizing all stages of the treatment and the use of all information, including data and photographs, for publication and lectures. This study received approval from the University Ethics Committee (CAAE: 20274219.9.0000.5336).

DISCUSSION

Crown fractures play a considerable challenge to pediatric dentists, as affected individuals experience pain and discomfort and may undergo feelings of inferiority that affect their daily lives and academic performance.^{1,2} The effective restoration of these teeth, with the re-establishment of form, function, and esthetics, is the major purpose of the dental profession. The present clinical case differs in that minimally invasive dentistry was applied with CAD/CAM technology and a restorative adhesive protocol so that a predictable long-term esthetic outcome could be achieved in a young child.

Several factors influence the management and long-term prognosis of crown fractures, such as the extent of the fracture, as

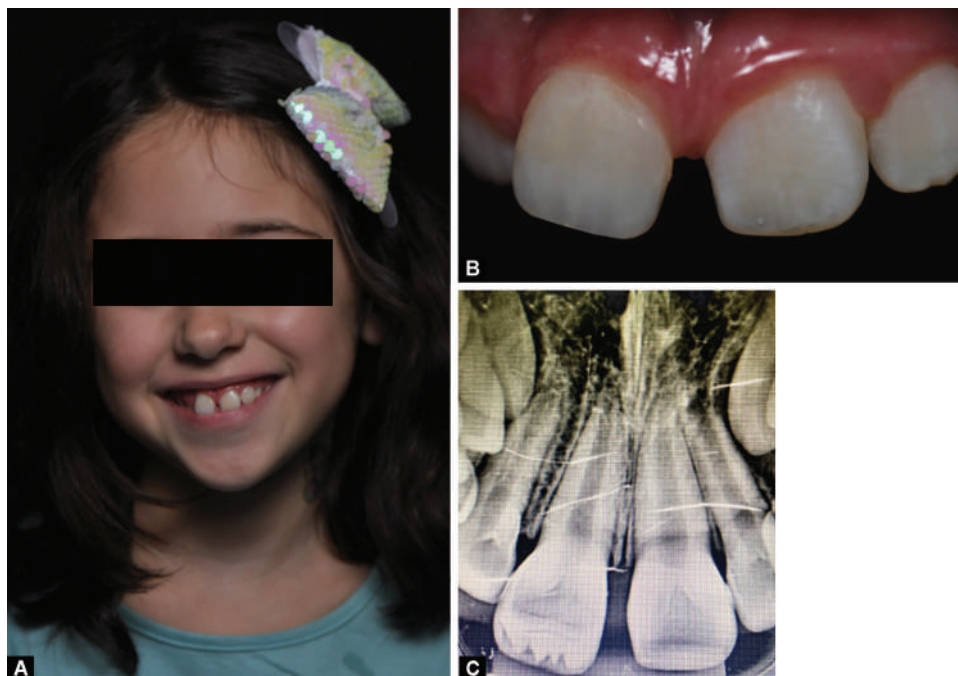
well as the presence and adaptation of the tooth fragment.^{16–18} The International Association of Dental Traumatology guidelines are the best source of scientific evidence on the diagnosis, treatment, and prognosis of TDIs.⁵ However, there is limited evidence to support many of the treatment options, especially for the variations that characterize TDIs, such as the direction of impact, severity, and stage of tooth formation.¹⁹ The present clinical case involved an unusual crown fracture on an unerupted maxillary central incisor for which the fractured fragment was not recovered. After discussing the treatment options with the parents, the decision was made to allow the complete eruption of the injured tooth prior to restorative treatment, aiming to simplify the rehabilitative procedures.

Every effort should be made to preserve the pulpal integrity in immature teeth to enable continued root development and apex formation. It is also important to point out that the general principle for the healing of crown fractures (sealing off exposed dentinal tubules as soon as possible with lining material and/or restoration to ensure pulp survival) is not an evidence-based procedure.^{9,19} Pulp sensitivity testing should be performed initially and at each follow-up appointment to determine if changes occur over time. Initial testing is also a good predictor of long-term prognosis for the pulp. However, the temporary loss of sensitivity is a frequent finding during post-trauma pulp healing, and a lack of a response is, therefore, not a conclusive finding of pulp necrosis in injured teeth.⁵ Pulp sensitivity tests were usually positive in this case report.

Accelerated dentin apposition with subsequent pulp canal obliteration (PCO) is a well-known complication in permanent teeth following direct trauma.^{5,9} Although the underlying mechanism of PCO is still unclear; it is associated with pulpal revascularization in teeth with open apices and usually indicates ongoing pulpal vitality. Moreover, PCO occurs more frequently in teeth that have suffered luxation.^{5,20,21} PCO was described in two case reports involving crown fracture of an unerupted permanent tooth.^{7,8} In the present case, however, there were no signs of root resorption, apical

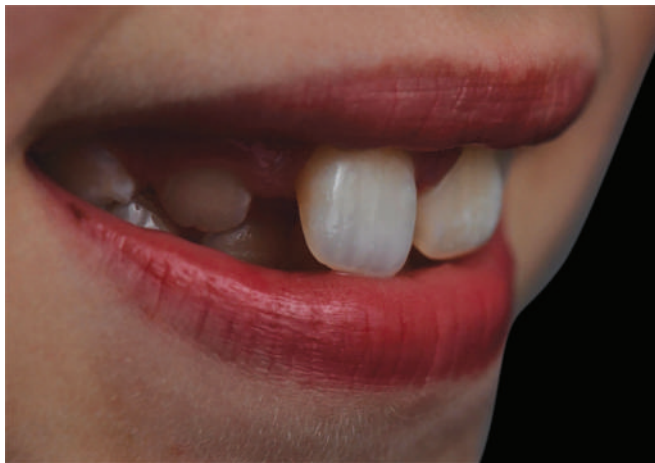

Fig. 6: Final result



Figs 7A to C: (A) Clinical follow-up 2 years after the trauma; (B) Clinical follow-up of tooth 11 after 2 years; (C) Radiographic follow-up of tooth 11 after 2 years

inflammatory lesion, or obliteration of the root canal. Moreover, root formation was observed, indicating the maintenance of pulp vitality.

Different methods have been described to restore fracture crowns, ranging from less invasive procedures to esthetic restorations, such as indirect ceramic crowns. Although some options provide excellent functional and esthetic results, such methods can be expensive and may require the removal of sound tooth structure as well as extending the length of the treatment. Techniques that can be completed in a timely, efficient manner are important in pediatric dentistry.

The incorporation of CAD/CAM in dentistry has facilitated treatment options for dental rehabilitation. Digital scanners are at least as exacting and reliable as more traditional impression techniques.¹⁵ Moreover, the use of CAD/CAM technology enables modern restorative treatment options to be more conservative than some traditional approaches. In the present clinical case, a biogenetic copy of the tooth anatomy of the twin sister was used to superimpose the scan of the fractured tooth and obtain a digital model for the restoration guide.

Direct composite restorations are effective for the restoration of crown fractures due to their good long-term clinical performance.²² Several factors may influence the success or failure of the restoration of crown fractures, such as the adequate isolation of the operating field, the strength of the resin bonding agents, shrinkage of the restorative material during polymerization, and the child's behavior. In the present clinical case, the silicone guide technique combined with the anatomic stratification of the composite resin facilitated the obtainment of the dental contours and convexities and ensured optical mimicking, enabling a satisfactory esthetic-functional outcome. This report has the purpose of demonstrating how and why clinicians should be aware of the different treatment options for restorative needs, especially in view of the challenges imposed regarding the esthetic and functional rehabilitation of TDIs in children and adolescents.

CONCLUSION

In the present case report, an unusual case of crown fracture of an unerupted permanent tooth has been described. The development of adhesive dentistry allied with computerized techniques enabled minimally invasive treatment with excellent esthetic results.

Clinical Significance

Crown fracture of an unerupted incisor may occur in childhood, requiring a long-term clinical and radiographic follow-up. Predictable, positive, and reliable esthetic outcomes can be achieved using CAD/CAM technology combined with adhesive protocols.

ORCID

Joao BB Weber  <https://orcid.org/0000-0002-9561-9767>

REFERENCES

1. Borges TS, Vargas-Ferreira F, Kramer PF, et al. Impact of traumatic dental injuries on oral health-related quality of life of preschool children: a systematic review and meta-analysis. *PLoS One* 2017;12(2):e0172235. DOI: 10.1371/journal.pone.0172235
2. Zaror C, Martinez-Zapata MJ, Abarca J, et al. Impact of traumatic dental injuries on quality of life in preschoolers and schoolchildren:

- a systematic review and meta-analysis. *Community Dent Oral Epidemiol* 2018;46(1):88–101. DOI: 10.1111/cdoe.12333
3. Abbott P. Traumatic dental injuries are now the 5th most prevalent disease/injury in the world—but they are being neglected!! *Dent Traumatol* 2018;34(6):383. DOI: 10.1111/edt.12451
4. Bani-hani TGH, Olegário IC, O'Connell AC. The cost of dental trauma management: a one-year prospective study in children. *Dent Traumatol* 2020;36(5):526–532. DOI: 10.1111/edt.12561
5. Bourguignon C, Cohenca N, Lauridsen E, et al. International Association of Dental Traumatology guidelines for the management of traumatic dental injuries: 1. fractures and luxations. *Dent Traumatol* 2020;36(4):314–330. DOI: 10.1111/edt.12578
6. Güngör HC. Management of crown-related fractures in children: an update review. *Dent Traumatol* 2014;30(2):88–99. DOI: 10.1111/edt.12079
7. Mackie IC. Coronal fracture of an unerupted incisor. *Endod Dent Traumatol* 1987;3(1):41–42. DOI: 10.1111/j.1600-9657.1987.tb00171.x
8. Abbott PV, Gregory PJ. Complicated crown fracture of an unerupted permanent tooth—a case report. *Dent Traumatol* 1998;14(1):48–56. DOI: 10.1111/j.1600-9657.1998.tb00808.x
9. Andreasen JE, Andreasen FM, Andersson L. (2007) Textbook and color atlas of traumatic injuries to the teeth 4th ed. Copenhagen: Munksgaard International Publishers
10. Soares JP, Barasuol JC, Torres FM, et al. The impact of crown fracture in the permanent dentition on children's quality of life. *Dent Traumatol* 2018;34(3):158–163. DOI: 10.1111/edt.12400
11. Feldens CA, Senna RA, Vargas-Ferreira F, et al. The effect of enamel fractures on oral health-related quality of life in adolescents. *Dent Traumatol* 2019;36(3):247–252. DOI: 10.1111/edt.12526
12. Rajab LD, Al Huda DA. Impact of treated and untreated traumatic dental injuries on oral health-related quality of life among 12-year-old schoolchildren in Amman. *Dent Traumatol* 2019;35(3):153–162. DOI: 10.1111/edt.12466
13. Ramos-Jorge J, Paiva SM, Tataounoff J, et al. Impact of treated/untreated traumatic dental injuries on quality of life among Brazilian schoolchildren. *Dent Traumatol* 2014;30(1):27–31. DOI: 10.1111/edt.12048.
14. Magno MB, Jural LA, Nogueira AV, et al. Impact of crown fracture treatment on oral-related quality of life of children, adolescents, and their families: a prospective clinical study. *Int J Paediatr Dent* 2019;29(1):86–93. DOI: 10.1111/ipd.12437
15. May JT. Conservative anterior partial coverage cad/cam restoration. *Oper Dent* 2017;42(2):117–121. DOI: 10.2341/16-117-5
16. Olsburgh S, Jacoby T, Kejci I. Crown fractures in the permanent dentition: pulp and restorative considerations. *Dent Traumatol* 2002;18(3):103–115. DOI: 10.1034/j.1600-9657.2002.00004.x.
17. Reis A, Loguercio AD, Kraul A, et al. Reattachment of fracture teeth: a review of literature regarding techniques and materials. *Oper Dent* 2004;29(2):226–233.
18. Oh S, Jang JH, Kim HJ, et al. Long-term follow-up of complicated crown fracture with fragment reattachment: two case reports. *Oper Dent* 2019;44(6):574–580. DOI: 10.2341/18-201-T
19. Andreasen JO, Lauridsen E, Andreasen FM. Contradictions in the treatment of traumatic dental injuries and ways to proceed in dental trauma research. *Dent Traumatol* 2010;26(1):16–22. DOI: 10.1111/j.1600-9657.2009.00818.x
20. Robertson A, Andreasen FM, Andreasen JO, et al. Long-term prognosis of crown-fracture permanent incisors. The effect of stage of root development and associated luxation injury. *Int J Paediatr Dent* 2000;10(3):191–199. DOI: 10.1046/j.1365-263x.2000.00191.x
21. Bastos JV, Côrtes MIS. Pulpal canal obliteration after traumatic injuries in permanent teeth – scientific fact or fiction? *Brazilian Oral Res* 2018;32(1):159–168. DOI: 10.1590/1807-3107bor-2018.vol32.0075
22. Demarco FF, Collares K, Coelho-de-Souza FH, et al. Anterior composite restorations. A systematic review on long-term survival and reasons for failure. *Dent Mater* 2015;31(10):1214–1224. DOI: 10.1016/j.dental.2015.07.005