

DENTAL TECHNIQUE

Size, shape, alignment, and arrangement—4 steps to optimize dentofacial composition in smile design by using the patient-centered concept: A dental technique

Ruy Teichert-Filho, DDS, MSc,^a Maximiliano S. Gomes, DDS, MSc, PhD,^b and Márcio L. Grossi, DDS, MSc, PhD^c

One of the main goals of dental treatment is to restore the natural smile esthetics by considering the specific needs of each patient.¹ The application of dental prosthetic techniques² combined with adhesive dentistry³ and smile design^{4,5} has united scientific and artistic principles in the search for the most harmonious relationship between dental and dentofacial composition,⁵ or the recent concept of the “unity of the whole.”⁶

An efficient combination of artistic and scientific principles and their application in the diagnosis and planning of esthetic rehabilitation can be seen in the esthetic checklist proposed by Magne and Belser,⁷ who classified and divided the esthetic criteria into objective and subjective. Designing a pleasing smile by applying the fundamental objective criteria is relatively straightforward and practical, but applying the fundamental subjective criteria, also known as the principles of esthetic integration, is not so straightforward in practice. It is often difficult to define precisely which components of total esthetic integration will affect the overall harmony of the results. The main components are related to changes in tooth shape, design, and position relative to crown length and negative space, which, in turn, can be

ABSTRACT

A technique derived from patient-based outcomes is described for planning and determination of dental morphology in esthetic rehabilitation by direct evaluation in the mouth, with the help of the patient, and based on the definitive simulation results. The technique is focused on identification of a tooth arrangement to provide the most harmonious dentofacial composition based on size, shape, alignment, and arrangement, with input from the patient. A clinical treatment is presented to illustrate the use of the technique. Dental selection before smile design provided a comprehensive approach to the complex art of giving each patient’s smile individuality and personality. (J Prosthet Dent 2022;■:■-■)

related to the range of options in tooth size, shape, and arrangement.⁷

The characteristics that render a smile esthetically acceptable in the eyes of laypersons have not been clearly defined.⁸ Despite advances that have improved patient-clinician communication, such as smile design systems and trial restoration techniques,^{9,10} the patient typically remains unable to participate actively in the choice of tooth arrangement. The role of the patient has been limited to approving or rejecting the tooth arrangement, with this important step depending exclusively on the personal, technical, artistic, or even intuitive ability of the dentist or dental laboratory technician⁶⁻¹⁰ to understand a patient’s personality and wishes and to translate them into the definitive outcome.⁸

Patient-centered care is a concept in which patients are evaluated beyond biological needs,^{11,12} with psychological needs also being considered. This is achieved

Supported in part by the Coordenação de Aperfeiçoamento de Pessoal de Nível Superior—Brasil (CAPES)—Finance Code 001.

^aPhD student, Post-Graduate Program in Dentistry, School of Health and Life Sciences, Pontifícia Universidade Católica do Rio Grande do Sul (PUCRS), Porto Alegre, Brazil; and Dentist (Major), Medical and Dental Center of the Military Police of Rio Grande do Sul, Porto Alegre, Brazil.

^bAssociate Professor, Post-Graduate Program in Dentistry, School of Health and Life Sciences, Pontifícia Universidade Católica do Rio Grande do Sul (PUCRS), Porto Alegre, Brazil; and Dentist (Major), Medical and Dental Center of the Military Police of Rio Grande do Sul, Porto Alegre, Brazil.

^cProfessor, Post-Graduate Program in Dentistry, School of Health and Life Sciences, Pontifícia Universidade Católica do Rio Grande do Sul (PUCRS), Porto Alegre, Rio Grande do Sul, Brazil.

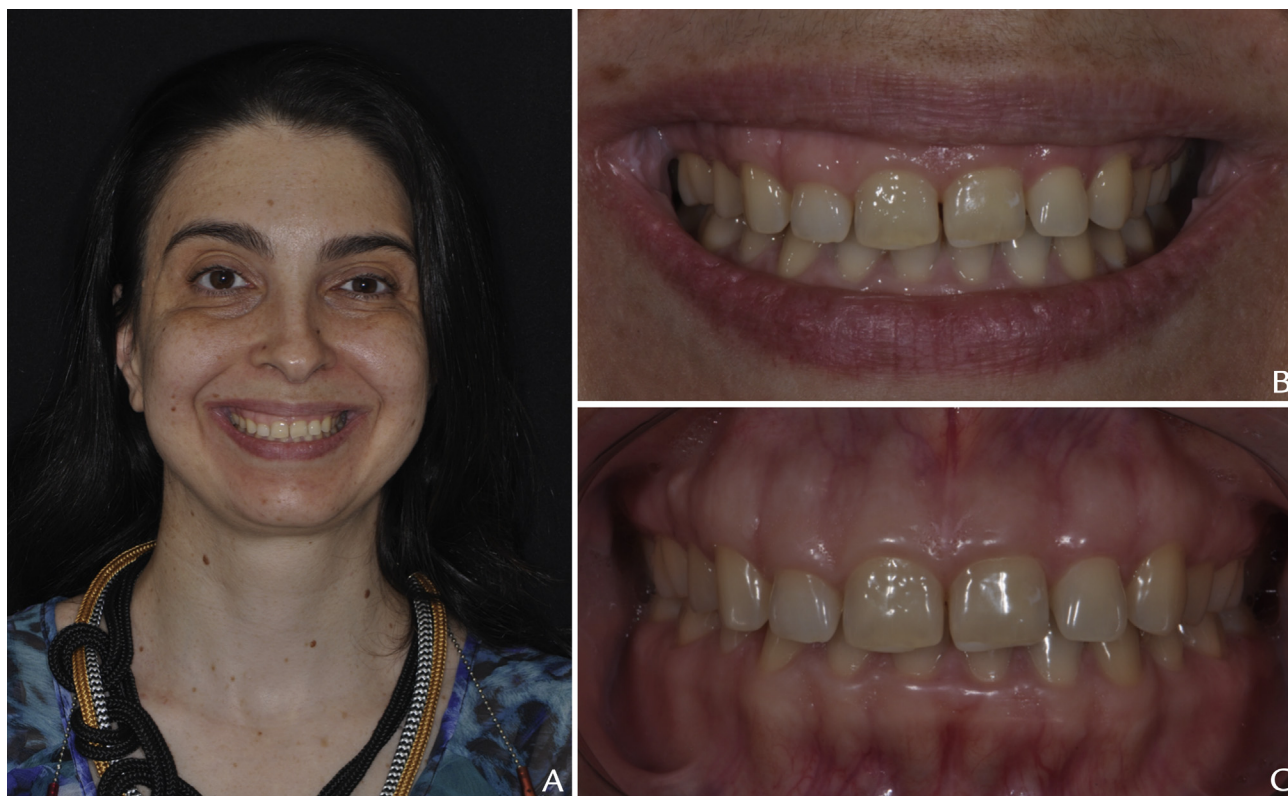

Figure 1. Initial diagnostic photography. A, Facial analysis. B, Initial smile. C, Intraoral view.

by understanding the uniqueness of patients, their place in society, and the way they view their condition.¹³⁻¹⁵ The establishment of a doctor-patient relationship based on a therapeutic alliance, where power and responsibility are shared with the patient, could benefit the treatment outcome.¹⁶

The described technique is illustrated in a clinical report that allowed the participation of the patient in both treatment planning and determination of the tooth arrangement for the esthetic rehabilitation in a patient-centered care model. Moreover, the described technique may improve esthetics by optimizing dentofacial composition. This is obtained by directly evaluating the effect of each tooth arrangement on the patient's face, along with their individual characteristics.

TECHNIQUE

The technique consists of directly evaluating which tooth arrangement will provide the most harmonious dentofacial composition with the help of the patient and based on the definitive simulation results. It involves the 4 domains of size, shape, alignment, and arrangement and begins by evaluating the impact of size and tooth dimensions of each tooth arrangement on the patient's face. The suitability and choice of the optimal shape will depend on the previously chosen

dimensions. Then, personalization and individualization are determined by aligning the teeth according to the horizontal lines of the smile curve and the extent of tooth exposure. Finally, the tooth arrangement is established, and the smile is customized by incorporating slight axial inclinations and rotations to obtain a beautiful natural smile.

To illustrate this dental technique, the treatment of a 40-year-old woman who was dissatisfied with her smile is described. She was unhappy with her tooth color, tooth shape, and the presence of diastema. She stated that she had a childlike smile that did not match her personality. Her treatment was planned and conducted based on the esthetic results achieved by using the principles and domains proposed by the size, shape, alignment, and arrangement concept.

1. Make impressions (Variotime Dynamix Putty Refill and Variotime Light Flow; Kulzer GmbH) or scans (CEREC Omnicam; Dentsply Sirona) for the initial diagnostic steps for esthetic rehabilitation and make the pretreatment photographs (D-90, AF-S VR Micro-Nikkor 105mm f/2.8G lens, SB-R200 Wireless Remote Speedlight flash; Nikon Corp) (Fig. 1).
2. Use a dental planning software program (Smile Designer Pro; Tasty Tech Ltd)¹¹ to determine treatment options.

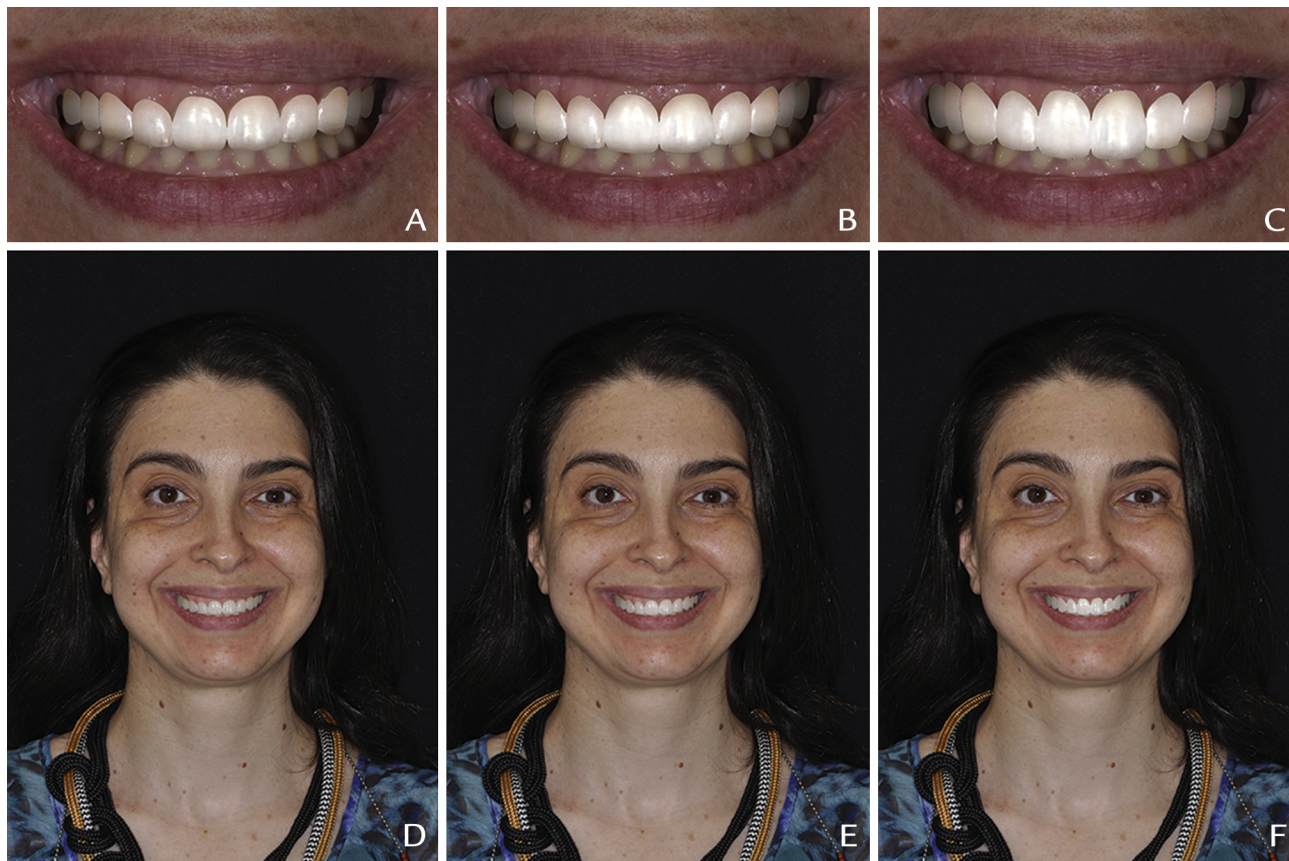

Figure 2. First step: size. Analyze impact of each tooth dimension on patient's face. A, Intraoral small size. B, Intraoral medium size. C, Intraoral large size. D, Facial analysis of extraoral small size. E, Facial analysis of extraoral medium size. F, Facial analysis of extraoral large size.

3. Assemble 3 smile options of varying sizes (small, medium, and large) (Fig. 2A-C). Start with the smallest possible size and draw the cervical margins and incisal edges focusing on achieving tooth harmony without extensive changes in dimensions. Following the same principles, increase the dimensions by slightly raising the cervical margin and increasing the incisal lengths according to the lower lip line to obtain a midrange size. For large sizes, slightly increase the dimensions. Remember that the objective at this stage is to determine the impact of these tooth dimensions on the patient's face.
4. Capture these images by making screenshots and transfer them to a presentation software program (PowerPoint; Microsoft Corp, Keynote; Apple Inc) by placing them side by side (Fig. 2D-F). Another option is to use the computer's image tools (Preview; Apple Inc). After making a screenshot of the planned smile, use both the "markup toolbar" and "instant alpha" to obtain templates that can be superimposed on the photographs. In conjunction with the patient, evaluate which set of teeth has dimensions that match the patient's preference. In the present situation, although the patient had first expressed a preference for large teeth, after looking at the photographs, she chose midrange teeth (Fig. 2B, 2E).
5. In the dental planning software program (Smile Designer Pro; Tasty Tech Ltd),¹¹ assemble a smile proposal with 3 or more shape variations based on the previously chosen tooth dimensions. In the present treatment, based on a set of midrange teeth, 1 tooth was chosen from each of the 3 fundamental shapes: square, triangular, and ovoid (Fig. 3A-C). As in the previous domain (size selection), capture these images and assemble them side by side in an image to select the shape with the patient (Fig. 3D-F). Although the patient had initially reported that she would like a smile with a rounded outline, after seeing the images, she selected the triangular shape.
6. Start the individualization of the smile by using alignment (Fig. 4) based on the ideal dimensions and shape previously chosen and then determine the amount of tooth exposure to create harmony with the lips and other horizontal lines (bipupillary line and high smile line).
7. Customize the tooth arrangement by incorporating slight inclinations and rotations along the axial axis of the teeth (Fig. 5); the customization can be

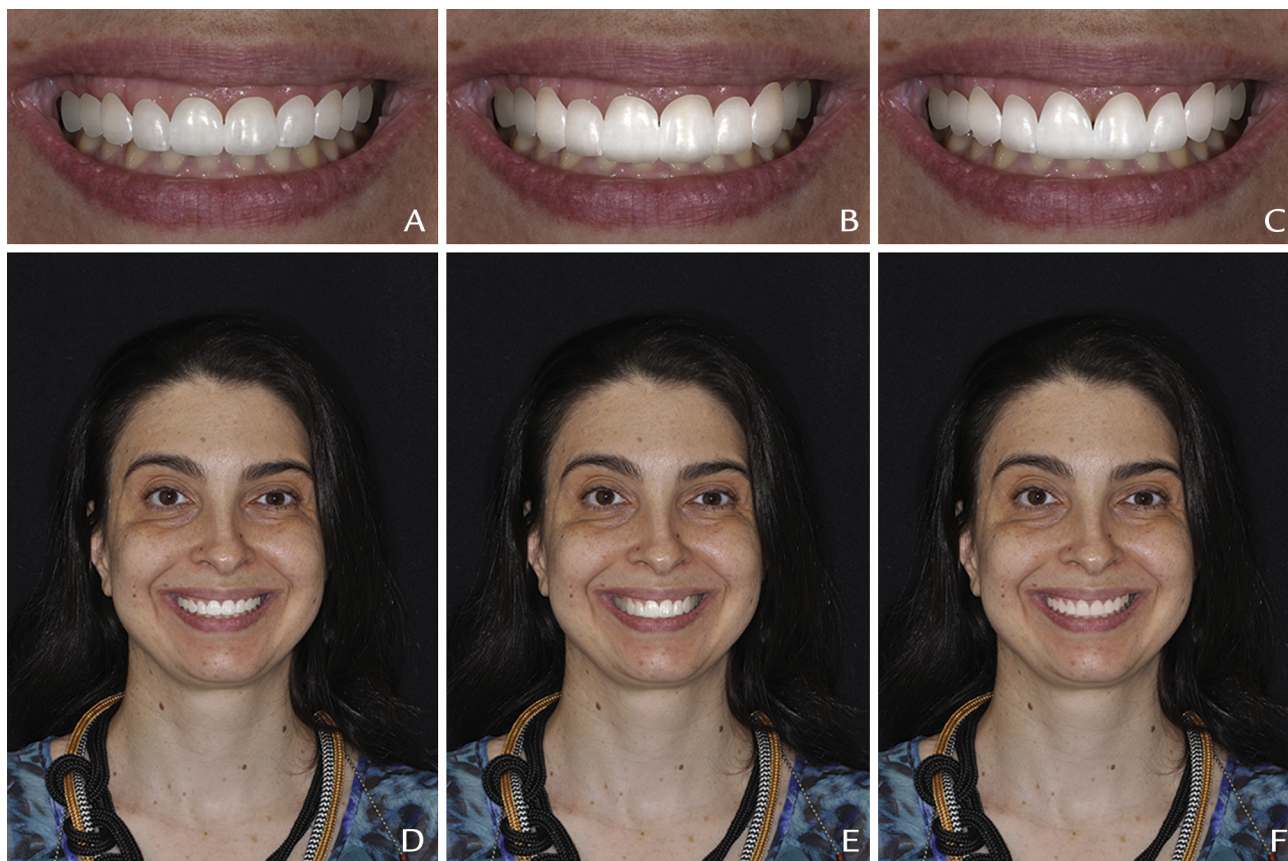

Figure 3. Second step: shape. Choose best tooth shape of chosen size that provides most pleasant esthetic results. A, Intraoral rounded shape. B, Intraoral square shape. C, Intraoral triangular shape. D, Facial analysis of extraoral rounded shape. E, Facial analysis of extraoral square shape. F, Facial analysis of extraoral triangular shape.

performed in the dental planning software program (Smile Designer Pro; Tasty Tech Ltd)¹¹ or at the wax pattern stage.

8. Render the 2-dimensional image on a 3-dimensional cast by using a free software program (Meshmixer; Autodesk Inc).¹⁷ Another option is to send all information, photographs, and articulated models to a dental laboratory technician for diagnostic waxing or diagnostically wax the cast yourself.
9. From the 3D cast obtained, make intraoral trial restorations by using a silicone matrix (Variotime Dynamix Putty Refill and Variotime Light Flow; Kulzer GmbH) filled with bis-acrylic resin (Structur 2 SC, B1 color; Voco GmbH) for photographs and dynamic diagnostic procedures: evaluating the rest position and fricative sounds and making a video to obtain the definitive patient- and dentist-approved diagnosis (Fig. 6).

Once the dental morphology and clinical treatment were approved, periodontal surgery was performed to increase the cervical margin by approximately 1.5 mm (Supplementary material, available online). After 1 month, home bleaching was performed with carbamide

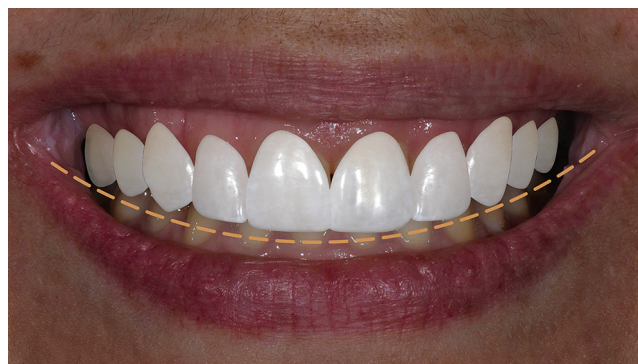

Figure 4. Third step: alignment. Align teeth according to horizontal lines, smile curve, and determine amount of tooth exposure.

peroxide (Opalescence PF; Ultradent Products, Inc) at increasing concentrations of 10%, 15%, and 20%. The teeth were prepared 3 months after surgery after scanning the trial restorations and then the prepared teeth. The overlap of the scans (CEREC Omnicam; Dentsply Sirona) enabled the planning to be precisely transferred to the definitive restorations by using a tool (Biogeneric Copy) in the software program (CEREC software SW 4.6;

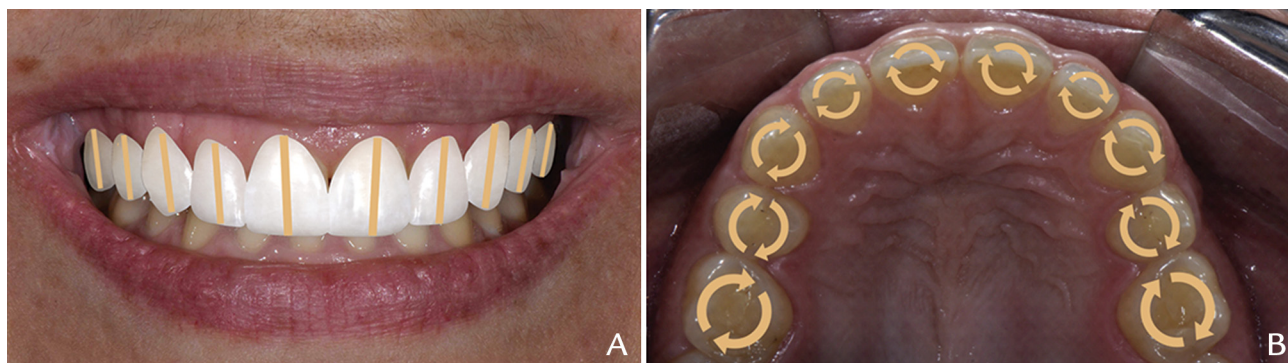


Figure 5. Fourth step: arrangement. Personalize and individualize smile. A, Long axis of teeth. B, Adding small rotations.

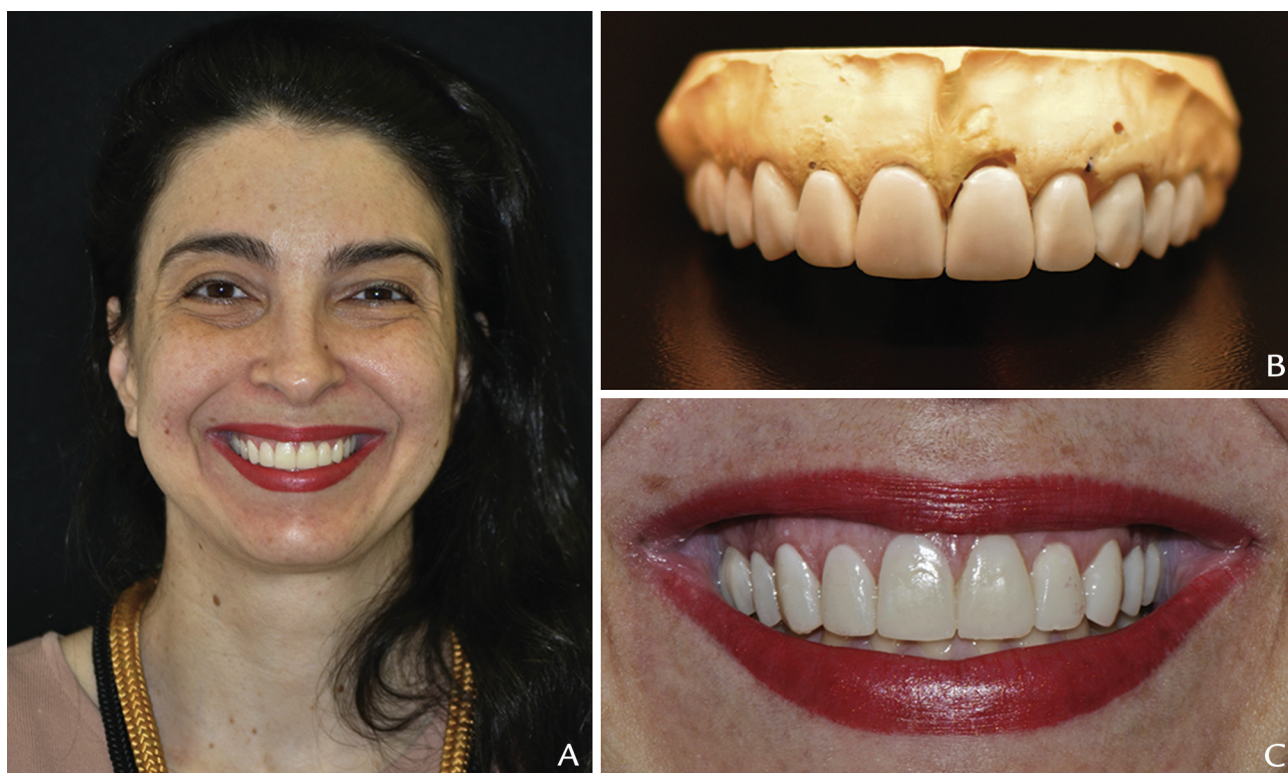

Figure 6. Analysis of size, shape, alignment, and arrangement as guided by trial restoration. A, Facial appearance. B, Waxing size, shape, alignment, and arrangement guided. C, Smile approved.

Dentsply Sirona). The restorations (IPS Empress CAD Multi, BL3 color; Ivoclar AG) were completed with external surface staining and characterization (IPS Empress Universal Shade A-D, B2/B3/B4, I1, I2 shades and IPS Ivocolor Glaze Paste FLUO; Ivoclar AG) (Fig. 7). Additionally, they were cemented with a neutral color luting agent according to the manufacturer's instructions: color cement selection (Variolink Esthetic Try-In; Ivoclar AG); restorations prepared with hydrofluoric acid, silane, and adhesive (IPS Ceramic Etching Gel KIT, Monobond Plus, and ExciTE F; Ivoclar AG); teeth cleaned; teeth etched with phosphoric acid (Total Etch; Ivoclar AG); adhesive applied (ExciTE F; Ivoclar AG); restorations

cemented (Variolink Esthetic LC, neutral color; Ivoclar AG) and photopolymerized (VALO Grand; Ultradent Products, Inc); excess cement removed; oxygen blocker applied (Liquid Strip; Ivoclar AG); and light polymerization performed. The different phases of the treatment are presented in Figure 8.

DISCUSSION

Advantages of the present technique include the active participation of the patient in the dental selection process, promoting patient empowerment, shared responsibility, and mutual trust.¹² The technique facilitates dentist-

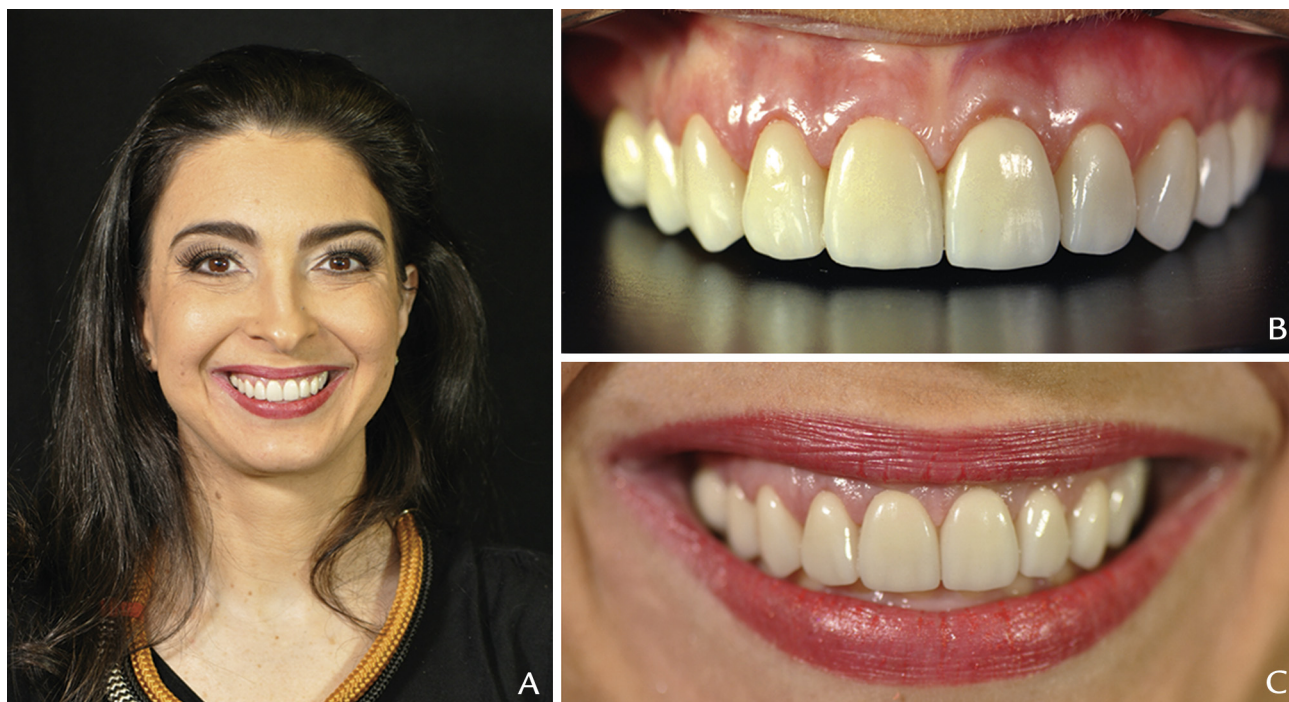

Figure 7. Result. A, Smile view. B, Intraoral view. C, Final smile.

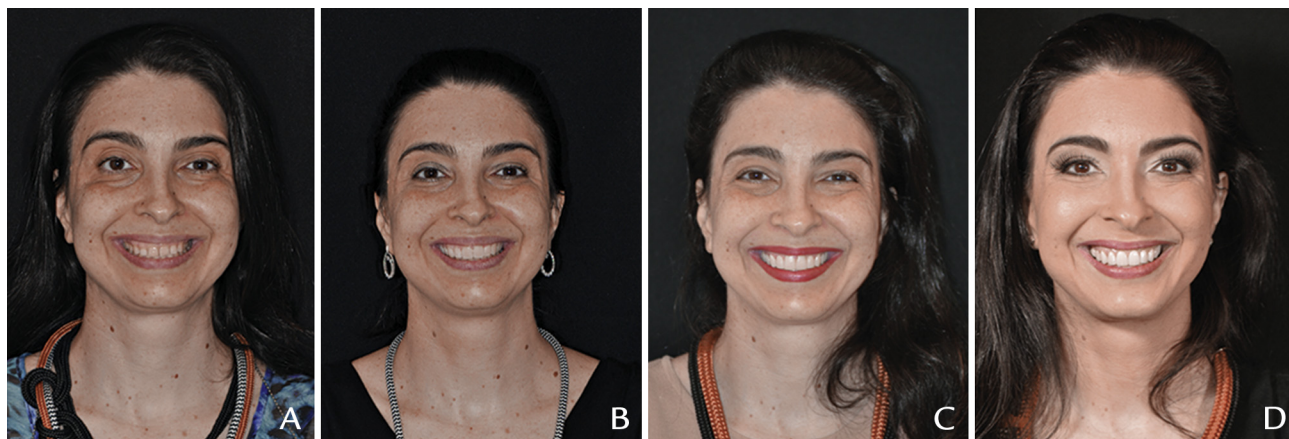

Figure 8. Comparative photography of different phases of clinical treatment with patient goals achieved. A, Initial smile. B, First evaluation. C, Evaluation guided by size, shape, alignment, and arrangement waxing. D, Result.

patient communication by standardizing and simplifying the procedures involved in oral rehabilitation. Dental selection performed before smile design optimizes dentofacial composition. The technique enables a systematic integration of the objective and subjective criteria⁷ involved in esthetic rehabilitations, favoring the construction of a smile with personality and individuality.

The present technique is indicated for any kind of oral rehabilitation, functional or esthetic, that includes reshaping the dental morphology. To the best of the authors' knowledge, this technique has no contraindications once the operator has learned the procedure.

Although it seems a challenge to plan 3 or more designs, the use of the recommended 4-domain sequence usually results in a single smile design option. For some patients, additional trial restorations will be required, especially where esthetic expectations are high. The need to simulate more than 1 prototype is usually restricted to doubts regarding size. For the steps of shape, alignment, and arrangement, acceptance is typically straightforward. However, the results may compensate for the possible increase in time and cost of this technique and may prevent patient dissatisfaction.

Studies are needed to evaluate the accessibility and reproducibility of this technique by different professionals, and future randomized controlled clinical trials should compare the results of this new technique with those of the conventional smile design approach.

SUMMARY

A new method of tooth selection before smile design based on the determination of tooth size, shape, alignment, and arrangement in a patient-centered care model is presented.

REFERENCES

- Blatz MB, Chiche G, Bahat O, Roblee R, Coachman C, Heymann HO. Evolution of aesthetic dentistry. *J Dent Res* 2019;98:1294-304.
- Sellen PN, Jagger DC, Harrison A. Methods used to select artificial anterior teeth for the edentulous patient: A historical overview. *Int J Prosthodontics* 1999;12:51-7.
- Buonocore M. A simple method of increasing the adhesion of acrylic filling materials to enamel surfaces. *J Dent Res* 1955;34:849-53.
- Levine JB. Esthetic diagnosis. *Curr Opin Cosmet Dent* 1995;9-17.
- Nicholas CD. Smile Design. *Dent Clin N Am* 2007;51:299-318.
- Gürel G, Paolucci B, Iliev G, Filtchev D, Schayder A. The fifth dimension in esthetic dentistry. *Int J Esthet Dent* 2021;16:10-32.
- Magne P, Belser U. Bonded porcelain restorations in the anterior dentition: A biomimetic approach. 1 ed. Chicago: Quintessence; 2002. p. 57-96.
- Montero J, Gómez Polo C, Rosel E, Barrios R, Albaladejo A, López-Valverde A. The role of personality traits in self-rated oral health and preferences for different types of flawed smiles. *J Oral Rehabil* 2016;43:39-50.
- Magne P, Magne M, Belser U. The diagnostic template: a key element to the comprehensive esthetic treatment concept. *Int J Perio Rest Dent* 1996;16:561-9.
- Zimmermann M, Mehl A. Virtual smile design systems: a current review. *Int J Comput Dent* 2015;18:303-17.
- Alrawai S, Asimakopoulou K, Scambler S. Patient-centred care in dentistry: Definitions and models-commentary. *Eur J Dent Educ* 2020;00:1-4.
- National Institute for Clinical Excellence. Patient experience in adult NHS services: improving the experience of care for people using adult NHS services: Clinical Guidelines. London: NICE; 2012.
- Scambler S, Asimakopoulou K. A model of patient-centred care – turning good practice into patient centred care. *Br Dent J* 2014;217:225-8.
- Balint E. The possibilities of patient-centered medicine. *J R Coll Gen Pract* 1969;17:269-76.
- Balint M. The doctor, his patient, and the illness. *Lancet* 1955;268:683-8.
- Mead N, Bower P. Patient-centredness: a conceptual framework and review of the empirical literature. *Social Sci Med* 2000;51:1087-110.
- Galibourg A, Brenes C. Virtual smile design tip: From 2D to 3D design with free software. *J Prosthet Dent* 2019;121:863-4.

Corresponding author:

Dr Ruy Teichert Filho
 Post-Graduate Program in Dentistry
 School of Health and Life Sciences
 Pontifícia Universidade Católica do Rio Grande do Sul
 Avenida Ipiranga 6681, prédio 6
 Porto Alegre RS 90619-900
 BRAZIL
 Email: ruy.teichert@edu.pucrs.br

Acknowledgments

The authors wish to thank the voluntary participation of the patient, who kindly accepted to provide the images used to illustrate the technique described.

Copyright © 2022 by the Editorial Council for The Journal of Prosthetic Dentistry.
<https://doi.org/10.1016/j.prosdent.2022.04.010>