




Contents lists available at ScienceDirect

Journal of Cranio-Maxillo-Facial Surgery

journal homepage: www.jcmfs.com

Minimally invasive surgical and miniscrew-assisted rapid palatal expansion (MISMARPE) in adult patients



Orion L. Haas Junior ^{a, e, 1, *}, Paulo R.B. Matje ^{b, 1}, Bibiana M. Rosa ^a, Carolina Rojo-Sanchis ^c, Raquel Guijarro-Martínez ^d, Adaia Valls-Ontañón ^e, Luciane M. Menezes ^b, Federico Hernández-Alfaro ^e, Rogério B. de Oliveira ^a

^a Department of Oral and Maxillofacial Surgery, Pontifical Catholic University of Rio Grande do Sul and São Lucas Hospital of PUCRS, Porto Alegre, Brazil

^b Department of Orthodontics, Pontifical Catholic University of Rio Grande do Sul, Porto Alegre, Brazil

^c Department of Orthodontics, Universidad de Valencia, Valencia, Spain

^d Department of Orthodontics, Cardenal Herrera-CEU Universidad de Valencia, Valencia, Spain

^e Department of Oral and Maxillofacial Surgery, Universitat Internacional de Catalunya, Sant Cugat del Vallès and Institute of Maxillofacial Surgery, Teknon Medical Centre, Barcelona, Spain

ARTICLE INFO

Article history:

Paper received 10 March 2021

Received in revised form

8 October 2021

Accepted 22 December 2021

Available online 27 December 2021

Keywords:

Minimally invasive surgery

MARPE

SARPE

Maxillary hypoplasia

Orthognathic surgery

Dentofacial deformity

ABSTRACT

The purpose of this study was to evaluate maxillary expansion, operative time and pain associated with a new minimally invasive surgical technique to treat maxillary hypoplasia in adult patients. Consecutive patients were included and prospectively analyzed. The technique consists in miniscrew-assisted rapid palatal expansion (MARPE), minimally invasive approach to maxillary osteotomies, latency period and activation period until the desired expansion. The parameters evaluated included operative time, treatment-related pain by the visual analog scale (VAS), and transverse maxillary expansion. The Shapiro–Wilk test was used to assess the normality of data distribution. A paired *t*-test was used to compare the data between T0 (preoperative) and T1 (postoperative – end of activation). The significance level was set at 5%. Eleven patients were included. Mean operative time was 24.11 min (14.4–32 min) and overall postoperative VAS score was 2.81 (0–9). A comparative analysis showed significant increases in maxillary width at the skeletal, alveolar, and dental levels ($p < 0.0001$ for all), with a mean range of 1.8 (SD 0.3) mm to 4.7 (SD 0.5) mm. The present minimally invasive surgical MARPE (MISMARPE) technique appears to yield good skeletal outcomes with minimal trauma. It might have potential for clinical use, but larger comparative studies are needed to confirm the clinical relevance of the approach.

© 2022 European Association for Cranio-Maxillo-Facial Surgery. Published by Elsevier Ltd. All rights reserved.

1. Introduction

Surgically assisted rapid palatal expansion (SARPE) and segmental Le Fort I osteotomy were the only options to correct transverse maxillary deficiency in adults until relatively recently (Williams et al., 2012; Zandi et al., 2014; Asscherickx et al., 2016). However, with the introduction of skeletal anchorage, reports of nonsurgical disjunction of the midpalatal suture in skeletally mature patients using temporary anchorage devices have been

published, what is known today as microimplant-assisted rapid palatal expansion (MARPE) (Carlson et al., 2016; Brunetto et al., 2017; Cantarella et al., 2017; Abedini et al., 2018; Jesus et al., 2021; Oliveira et al., 2021). Nevertheless, the indications for this technique are still poorly defined, and the risk factors for failure are unknown. Furthermore, transverse expansion is not as predictable as it is with SARPE, which has been shown to provide stable transverse expansion in adults (Vilani et al., 2012; Zandi et al., 2014; Seeberger et al., 2015; Asscherickx et al., 2016; Camps-Perepérez et al., 2017; Gogna et al., 2020; Muñoz-Pereira et al., 2020).

In recent years, orthognathic surgery has evolved toward less invasive procedures, with the aim of reducing morbidity (AlAsseri and Swennen, 2018). Within this context, Hernández-Alfaro et al. (2010) described a SARPE technique to treat transverse discrepancies of more than 5 mm in nongrowing patients which can be

* Corresponding author. Department of Oral and Maxillofacial Surgery, Pontifícia Universidade Católica do Rio Grande do Sul Avenida Ipiranga, 6681, Building 6, 90619-900, Porto Alegre, Brazil.

E-mail address: orion.haas@acad.oucrs.br (O.L. Haas Junior).

¹ Both authors contributed equally.

performed under local anesthesia plus sedation, as an office procedure, in 19 min.

In synchrony with the evolution of treatment options for transverse maxillary deficiency, the purpose of this study was to evaluate maxillary expansion, operative time and pain associated with a new minimally invasive surgical technique in combination with MARPE to treat maxillary hypoplasia in adult patients.

2. Materials and methods

This study is part of a longitudinal research project conducted jointly by the Department of Oral and Maxillofacial Surgery and the Department of Orthodontics of the Pontifical Catholic University of Rio Grande do Sul (PUC-RS) since April 2019. All procedures were performed in accordance with the Declaration of Helsinki, and the Institutional Review Board approved the study (ethical approval number: 42856915.1.0000.5336).

2.1. Sample

The inclusion criteria for this study were age 18 years or older and an established diagnosis of transverse maxillary deficiency. Patients with congenital malformations or any systemic conditions that contraindicated surgical procedures under local anesthesia were excluded.

2.2. Surgical protocol

2.2.1. Virtual planning

The position of the MARPE bone-borne expander (PECLAB, Belo Horizonte, MG, Brazil) followed a digital workflow, based on cone-beam computed tomography (CBCT) of the patient's face, intra-oral scanner data in STL format, and STL files for the expander/screws. These images were superimposed in the Dolphin Imaging 12.0 Premium software (Dolphin Imaging & Management Solutions, Chatsworth, CA, USA) to create a virtual model where screw length and expander position were selected in accordance with palatal bone and palatal mucosa thickness. A surgical guide was used to transfer the virtual planning to the surgical field.

2.2.2. Technique

Patients underwent minimally invasive osteotomies under local anesthesia. All procedures were performed in office by the same operator (OLHJ). The MARPE expander was positioned using a surgical guide and attached with four bicortical miniscrews previously selected during virtual planning (Fig. 1A).

A maxillary approach over the keratinized mucosa from lateral incisor to lateral incisor was made. Periosteal elevation was performed to expose the whole nasomaxillary region and the posterior maxillary area through a mucosal tunnel. Then, four osteotomies were made: one subspinal osteotomy to separate the anterior nasal spine, one vertical midline osteotomy extended into the nasal floor to the level of the medium thirds of the central incisors' roots (Fig. 1B), and two horizontal lateral osteotomies extending from the piriform aperture to the posterior maxilla (one per side) (Fig. 1C). The MARPE expander was then activated to check maxillary separation in the midline. One millimeter and a quarter (6 activations) remained at the time of the procedure. Sutures were placed to reposition the alar process of the nasal muscle and to close the mucosal incision (Fig. 1D).

An antibiotic, anti-inflammatory, analgesic, chlorhexidine rinse was prescribed for use during the postoperative period. The latency period was 7 days, at which point MARPE activation was started at a rate of two turns per day until appearance of an interincisal diastema. The activation rate was then decreased to one turn per day

until the required expansion was achieved. The activation protocol was based on the study by [Carlson et al. \(2016\)](#).

2.3. Analysis

2.3.1. Operative time

The duration of the surgical procedure was timed from first incision to placement of the last suture.

2.3.2. Visual analog scale (VAS) for pain

Patients were instructed to record pain daily on a VAS ([Hayes and Paterson, 1921](#)) from 0 ("no pain") to 10 ("worst pain imaginable"). The scores were obtained from the first postoperative day until the last day of activation of the expander. Pain was classified as mild (VAS score 1–3), moderate (VAS score 4–6), or severe (VAS score 7–10).

2.3.3. CBCT measurements

An i-CAT scanner (Imaging Sciences International, Hatfield, PA, USA) was used to obtain CBCT images before expansion (T0) and at the end of the activation period (T1). Scans were performed at 120 kV, 8 mA, acquisition time 40 s, and 0.3-mm voxel dimension. The data were reconstructed with 0.3-mm slice thickness, and the resulting digital imaging and communications in medicine (DICOM) images were assessed using Dolphin Imaging software.

The pre-treatment three-dimensional CBCT model was reconstructed in Dolphin Imaging Software. Then, it was oriented to set the Frankfort plane (Or left-Po-Or right) parallel to the axial crosshair and the nasion-anterior nasal spine plane perpendicular to the Frankfort plane. After orientation of pre-treatment images, the post-treatment CBCT was superimposed using the voxel-based technique of the anterior cranial base ([Haas Junior et al., 2019](#)). When both CBCT scans had the same orientation, the surgical results could be measured (Fig. 2).

For transverse maxillary evaluation, eight distances and two angular values were analyzed. Distance 1 (D1): Posterior maxilla distance; Distance 2 (D2): Posterior midpalatal suture distance; Distance 3 (D3): Anterior maxilla distance; Distance 4 (D4): Anterior midpalatal suture distance; Distance 5 (D5): Posterior alveolar process distance; Distance 6 (D6): Anterior alveolar process distance; Distance 7 (D7): Posterior dental crown distance; Distance 8 (D8): Posterior dental root distance; Angle 1 (A1): Angle UR6; and Angle 2 (A2): Angle UL6 ([Table 1](#)).

2.4. Statistical analysis

Test-retest reliability of the measurements was calculated by intraclass correlation coefficients (ICCs). Assessment of all parameters at T0 and T1 (10 days apart) of five patients were compared. The data obtained were processed in IBM SPSS Statistics (version 22.0, IBM, Armonk, NY) and assessed for normality by the Shapiro–Wilk test. Means and standard errors for each parameter were calculated. As the assumption of normality was confirmed, data at T0 and T1 were compared by a paired *t*-test, at a significance level of 5%.

3. Results

Eleven consecutive patients were included and prospectively analyzed from June to December 2019. The sample consisted of 8 women and 3 men, with a mean age of 38.89 years (range, 19.1–56 years). Mean operative time was 24.11 min (range, 14.4–32 min), and the mean activation period of the orthodontic appliance was 24.36 days (range, 20–31 days) ([Table 2](#)).

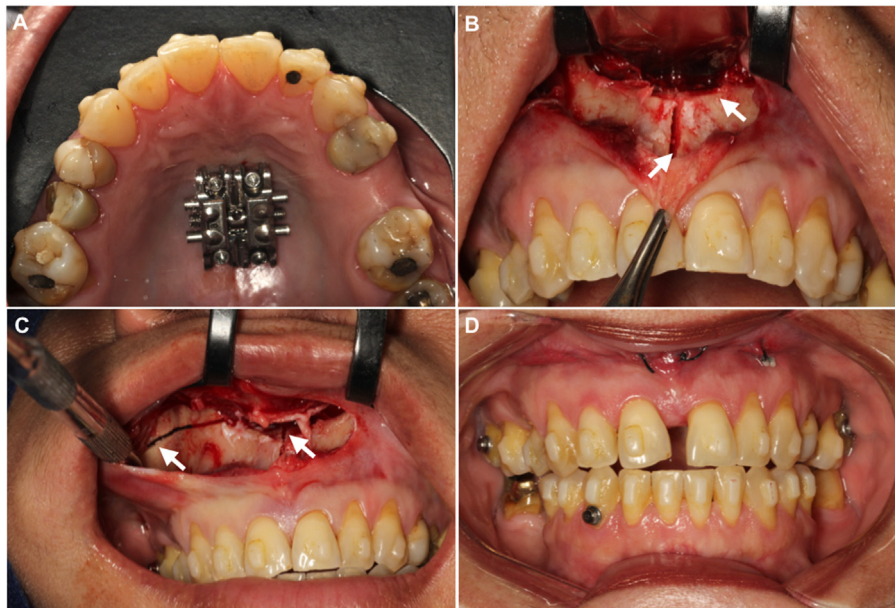


Fig. 1. MISMARPE technique. A. MARPE expander in place; B. Subspinal osteotomy and vertical osteotomy; C. Horizontal osteotomy and intranasal osteotomy; D. MARPE activation and suture.

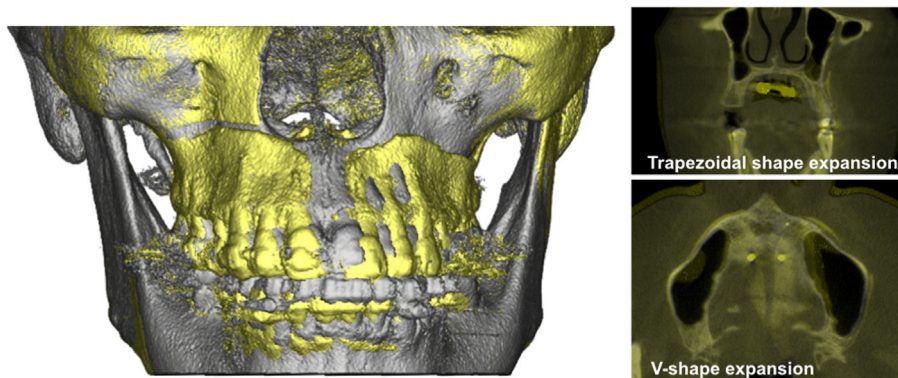


Fig. 2. Voxel-based superimposition and palatal expansion pattern. Gray – preoperative CBCT/Yellow – postoperative CBCT.

Table 1

Landmarks and measurements for transverse maxillary evaluation.

Skeletal	
D1. Posterior maxilla distance	Width between maxilla buccal cortex in the region of the right and left first upper molar, passing through inferior inner contour of the posterior nasal cavity.
D2. Posterior midpalatal suture distance	Midpalatal suture width in the posterior region (same CBCT coronal view of the posterior maxilla distance). Representing the posterior midpalatal suture opening after activation.
D3. Anterior maxilla distance	Width between maxilla buccal cortex in the region of the right and left upper canine, passing through inferior inner contour of the anterior nasal cavity.
D4. Anterior midpalatal suture distance	Midpalatal suture width in the anterior region (same CBCT coronal view of the anterior maxilla distance). Representing the anterior midpalatal suture opening after activation.
Alveolar	
D5. Posterior alveolar process distance	Width between most coronal alveolar process buccal cortex in the region of the right and left first upper molar.
D6. Anterior alveolar process distance	Width between alveolar process buccal cortex in the region of the right and left upper canine, 5 mm inferior to the line of the “Anterior maxilla distance”.
Dental	
D7. Posterior dental crown distance	Width between medial-palatal cuspid of the right and left first upper molar.
D8. Posterior dental root distance	Width between palatal root apex of the right and left first upper molar
A1. Angle UR6	Angle formed by the straight line between distances 7 and 8 in the right side.
A2. Angle UL6	Angle formed by the straight line between distances 7 and 8 in the left side.

UR6: upper right first molar; UL6: upper left first molar.

Table 2
Demographic data.

Patients	Gender	Age (years)	Surgical time (minutes)	Activation period (days)
1	F	19.1	28	25
2	F	40.5	26.58	22
3	F	52	23.4	24
4	F	40.4	14.4	28
5	F	34.3	32	20
6	M	40.9	22.3	31
7	M	35.8	29	22
8	F	45.8	19.5	24
9	M	56	21	24
10	F	37.8	21	20
11	F	25.2	28	28
General	8F/3M	38.89	24.11	24.36

F: female; M: male.

Table 3
Mean values of VAS (Visual Analogue Scale) for pain.

Patients	Latency period (Day one to six) Average	Activation period (Day seven to end activation) Average	Total postoperative period (Latency + Activation) Average (Range)
1	1	2.84	2.48 (0–6)
2	1	3.31	2.82 (0–6)
3	1.5	2.70	2.46 (0–6)
4	0.83	2.10	1.88 (0–6)
5	0.66	4.3	3.46 (0–6)
6	1.33	2.87	2.62 (0–6)
7	0.5	1.09	0.96 (0–4)
8	0.33	4.41	3.64 (0–6)
9	1.5	6	5.12 (1–9)
10	1.33	4	3.38 (0–6)
11	1	2.71	2.41 (0–6)
General	1	3.25	2.81 (0–9)

Table 3 provides detailed VAS data. Before device activation (postoperative days 1–6), overall mean VAS score was 1. During activation (day 7 until the end of the activation period for each patient), the mean VAS score was 3.25. Overall postoperative VAS score 2.81, with most patients recording a maximum pain score of 6 (moderate) on VAS, except for patient 9 (Table 3 and Fig. 3).

However, at all stages, all patients had a mean VAS score within the moderate range of pain.

ICCs showed excellent intra- and inter-examiner reproducibility. The results for all measurements are shown in Table 4. Comparative analysis showed significant increases in maxillary width at the skeletal, alveolar, and dental levels ($p < 0.0001$) after complete

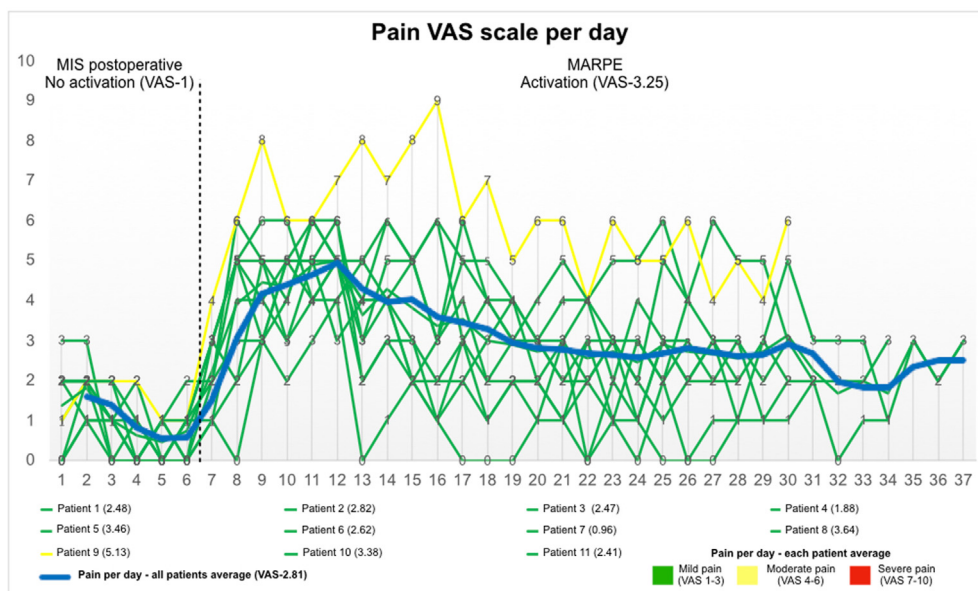


Fig. 3. VAS scores for pain per day.

Table 4
Measurements for transverse maxillary evaluation.

Patients	D1 (mm)			D2 (mm)			D3 (mm)			D4 (mm)			D5 (mm)			D6 (mm)			D7 (mm)			D8 (mm)		
	T0	T1	T1-T0	T0	T1	T1-T0	T0	T1	T1-T0	T0	T1	T1-T0	T0	T1	T1-T0	T0	T1	T1-T0	T0	T1	T1-T0	T0	T1	T1-T0
1	52.3	55.4	3.1	72	75.2	3.2	44.8	47	2.2	36.4	38.6	2.2	0	2.3	2.3	36.3	38.5	2.2	35.6	38.4	2.8	0	4.1	4.1
2	55.4	59.3	3.9	65.6	67.9	2.3	45.7	48.7	3	30.8	32.4	1.6	0	2.9	2.9	30.1	34.2	4.1	35.4	39.5	4.1	0	4	4
3	60.2	62.7	2.5	66.1	68.4	2.3	46.7	50.2	3.5	37.3	39.9	2.6	47.2	49.9	2.7	28.9	32.5	3.6	33.9	38.4	4.5	3.9	8.8	4.9
4	48.6	52	3.4	55.8	59.3	3.5	36.1	38.7	2.6	30.3	33.5	3.2	0.8	7.2	6.4	25.9	33.8	7.9	27.7	34.9	7.2	1.1	7.7	6.6
5	51	52.5	1.5	78.3	78.2	-0.1	36.7	39.7	3	31.4	32.9	1.5	0.6	2.3	1.7	24.8	30.5	5.7	29	34	5	1.9	6.1	4.2
6	48.8	57.8	9	60.6	63	2.4	43.3	51.9	8.6	30	35.8	5.8	0.3	8.1	7.8	31.5	38.5	7	36.3	42.5	6.2	1.8	9.2	7.4
7	52.2	56.3	4.1	68.3	70.3	2	37.7	44.3	6.6	36.4	41.7	5.3	1.6	5.5	3.9	22.8	31.1	8.3	31.3	37.5	6.2	1.7	8.9	7.2
8	58.4	63	4.6	63.9	64.8	0.9	42.3	46.2	3.9	34.7	37	2.3	0.8	3.5	2.7	22.6	26	3.4	30	33.9	3.9	2.2	7.5	5.3
9	44.5	46.4	1.9	57.2	58	0.8	38.4	42.5	4.1	29.2	30.7	1.5	0.5	2.8	2.3	33.1	35.8	2.7	35.9	38.6	2.7	0.9	2.6	1.7
10	54.7	55.9	1.2	57.5	58.7	1.2	39.6	41.6	2	29.5	31.5	2	44.5	46.1	1.6	26.7	28.2	1.5	27.7	29.6	1.9	1.1	4.2	3.1
11	60.8	63.3	2.5	64.2	65.7	1.5	48.7	49.8	1.1	34	36.6	2.6	49	50.3	1.3	26.6	28.8	2.2	29.5	32.9	3.4	6.2	10.7	4.5
Mean (SD)	53.3	56.7	3. (0.6)	64.5	66.3	1.8 (0.3)	41.8	45.5	3.7 (0.6)	32.7	35.5	2. (0.4)	0.74	4	3.2 (0.6)	28.1	32.5	4.4 (0.7)	32	36.3	4.3 (0.5)	1.9	6.7	4.7 (0.5)
P	<0.0001*			<0.0001*			<0.0001*			<0.0001*			<0.0001*			<0.0001*			<0.0001*			<0.0001*		
Intra-examiner ICC	0.93			0.89			0.93			0.88			0.90			0.89			0.94			0.91		
Inter-examiner ICC	0.91			0.95			0.70			0.88			0.88			0.71			0.77			0.88		

A1 (°)	A2 (°)	
	T0	T1-T0
110	113.2	3.2
107.1	106.4	-0.7
102.8	103	0.2
95.6	97	1.4
94.3	95	0.7
113.4	115.7	2.3
85.1	90.5	5.4
110.3	111.1	0.8
101.1	100.9	-0.2
110.8	110.8	0
120.6	117.5	-3.1
104.6	105.5	0.9 (0.6)
0.203		
0.89		
0.94		

*Statistically significant (P < 0.05).
ICC (intraclass correlation coefficient); D1. Posterior maxilla distance; D2. Posterior midpalatal suture distance; D3. Anterior maxilla distance; D4. Anterior midpalatal suture distance; D5. Posterior alveolar process distance; D6. Anterior alveolar process distance; D7. Posterior dental crown distance; D8. Posterior dental root distance; A1. Angle UR6; A2. Angle UL6; (mm): millimeters.

activation of the device. The anterior skeletal gains were 3.7 mm (D3) and 2.7 mm (D4). There was a 4.4 mm gain (D6) at the anterior alveolar level. In the posterior region, the skeletal, alveolar, and dental gains were, respectively, 3.4 mm (D1) and 1.8 mm (D2); 3.2 mm (D5); 4.3 mm (D7); and 4.7 mm (D8). Greater expansion was observed in the anterior region than in the posterior region. In the posterior region, more expansion was seen in the maxilla than in the alveolar process (Table 4).

Skeletal measurements distant from the miniscrews were greater than the measurements close to the miniscrews, both in the posterior region (D1 greater than D2) and in the anterior region (D3 greater than D4). The measurements that showed the smallest increases were the anterior and posterior midpalatal suture distances (D2 and D4). The final angulations of the maxillary first molars did not show significant differences after the procedure (UR6: 0.9°, p = 0.203; UL6: 2.3°, p = 0.123) (Table 4).

All patients had an opening of the transverse palatal suture, and 8 patients had an opening of the median suture posteriorly to the transverse palatal suture (up to the posterior nasal spine). No patient presented with opening of the pterygomaxillary fissure at the end of the activation period.

4. Discussion

To analyze the potential effectiveness and safety of the present minimally invasive surgical MARPE (MISMARPE) technique, a longitudinal sample was assessed consisting of patients in the second to sixth decades of life (mean age, 38.89 years) in whom MARPE would be contraindicated. This approach aimed at minimizing surgical trauma while providing an advantage over SARPE (Fig. 4).

The MISMARPE technique does not involve pterygomaxillary disjunction. This step is not required for the success of maxillary expansion according to the results of a meta-analysis conducted by Sangsari et al. (Sangsari et al., 2016). Avoiding pterygomaxillary disjunction makes the surgical procedure less traumatic, more streamlined, and feasible under local anesthesia in an office setting. MISMARPE can be undertaken with less morbidity to the patient and fewer costs to both patients and insurers, which are extremely important advantages. Another important advantage of performing the MISMARPE technique in an office setting is the short operative time, which, in our sample, ranged from 14.4 to 32 min (mean, 24.11 min) from first incision to closure of the surgical wound. This result indicates that MISMARPE is a rapid minimally invasive technique in the hands of experienced operators.

Shortened operative time also contributed to a reduction in postoperative discomfort/pain and complications. This outcome was assessed by using a VAS that had already been tested in the SARPE technique, with results of mild pain (Gül et al., 2021). A recent MARPE study described mild to moderate pain as reported by patients, but VAS was not used (Zong et al., 2019). In the present study, the overall mean VAS score was 2.81, which is classified as mild pain. This is in accordance with the SARPE and MARPE techniques, despite the use of local anesthesia to perform the surgical procedure and no pterygomaxillary disjunction. Also, pain was

greater during activation of the expander (overall mean VAS score of 3.25) than during the first 7 days after surgery, i.e., during the latency period (overall mean VAS score of 1). These findings confirm the low morbidity and good tolerability of the proposed procedure when performed in an office setting. The low level of discomfort experienced by patients can be attributed to the minimally invasive soft-tissue approach, use of piezoelectric surgery for osteotomies, short operative time, and judicious postoperative medication protocol.

In addition to rapid execution and minimal morbidity, MISMARPE also proved effective in the treatment of maxillary hypoplasia, with statistically significant expansion of all regions of interest: average transverse gains in the body of the maxilla ranged from 4.4 to 4.7 mm anteriorly to 1.8–3.2 mm posteriorly, with a 3.4-mm gain in the posterior alveolar process and a 4.3-mm gain in the anterior alveolar process. In an axial view, the midpalatal suture is opened in a V-shape, while on the coronal plane, the midpalatal suture is opened in a trapezoidal shape, with more anterior than posterior expansion and more alveolar-process than maxillary expansion (Fig. 2). Based on these findings, one may assume that, in adult patients, the MISMARPE technique will be useful mainly in cases where there is a discrepancy between the maxillary and mandibular arches, with V-shaped maxillary arch and U-shaped mandibular arch. MISMARPE can be used to coordinate the arches and correct the anterior maxillary constriction without dental repercussions, thus preventing relapse after removal of brackets. Liu et al. (2017), in a study of young adults with obstructive sleep apnea (OSA), used a technique and a device very similar to those presented here and observed a reduction in objective and subjective measurements of OSA. Vinha et al. (2020) also observed a reduction in OSA using the conventional surgically assisted rapid maxillary expansion (SARME) technique. In the present study, respiratory parameters were not assessed. Airway assessment using the MISMARPE technique will be performed in future studies.

The main factors that may explain a more anterior opening in patients undergoing MISMARPE include the use of fully skeletal anchorage (Kayalar et al., 2016, 2019; Celenk-Koca et al., 2018) and the absence of pterygomaxillary disjunction, which turns the posterior region into the center of resistance of the maxilla (Verstraaten et al., 2010). This trend also applies to older patients, as those in our sample (aged 19–56 years); advancing age correlates negatively with the proportion of suture opening (Salgueiro et al., 2015; Shin et al., 2019; Smeets et al., 2020).

The technique described in this study produced gains in all dimensions at the skeletal and dental levels, but the extent and pattern of expansion are also influenced by the type of appliance. There is evidence that bone-borne appliances produce more skeletal expansion than tooth-borne ones (Lin et al., 2015; Celenk-Koca et al., 2018) because forces are applied directly to bone, thus obviating the need for overcorrection to prevent dental relapse when using tooth-borne appliances.

This is a proof-of-concept study presenting the results of the first consecutive patients treated with the MISMARPE technique.

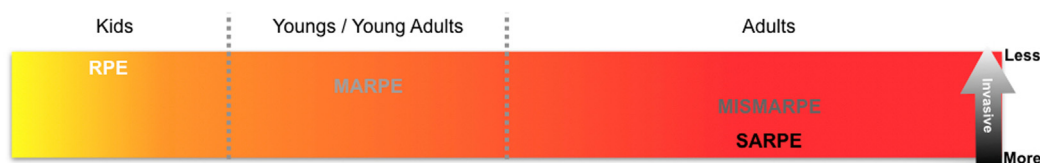


Fig. 4. MISMARPE indication and invasiveness in relation to other techniques.

Therefore, the study has limitations such as the small sample size and lack of data to evaluate long-term effects.

5. Conclusion

It appears that the MISMARPE technique might have potential for use in maxillary expansion in adults. Larger comparative studies with evaluation of stability effects are needed to confirm the clinical relevance of the approach.

Ethical approval

CAAE: 42856915.1.0000.5336 (Research Ethics Committee - Pontifical Catholic University of Rio Grande do Sul).
Written patient consent has been obtained.

Funding

None declared.

Declaration of competing interest

None declared.

References

- Abedini, S., Elkenawy, I., Kim, E., Moon, W., 2018 Nov 19. Three-dimensional soft tissue analysis of the face following micro-implant-supported maxillary skeletal expansion. *Prog. Orthod.* 19 (1), 46.
- AlAsseri, N., Swennen, G., 2018. Minimally invasive orthognathic surgery: a systematic review [Internet] *Int. J. Oral Maxillofac. Surg.* 47 (10), 1299–1310. <https://doi.org/10.1016/j.ijom.2018.04.017>. Available from:
- Asscherickx, K., Govaerts, E., Aerts, J., Vande Vannet, B., 2016 Mar. Maxillary changes with bone-borne surgically assisted rapid palatal expansion: a prospective study. *Am. J. Orthod. Dentofacial Orthop.* 149 (3), 374–383.
- Brunetto, D.P., Sant'Anna, E.F., Machado, A.W., Moon, W., 2017 Feb. Non-surgical treatment of transverse deficiency in adults using Microimplant-assisted Rapid Palatal Expansion (MARPE). *Dental Press J. Orthod.* 22 (1), 110–125.
- Camps-Perepérez, I., Guijarro-Martínez, R., Peiró-Guijarro, M.A., Hernández-Alfaro, F., 2017. The value of cone beam computed tomography imaging in surgically assisted rapid palatal expansion: a systematic review of the literature. *Int. J. Oral Maxillofac. Surg.* 46 (7), 827–838.
- Cantarella, D., Dominguez-Mompell, R., Mallya, S.M., Moschik, C., Pan, H.C., Miller, J., Moon, W., 2017 Nov 1. Changes in the midpalatal and pterygopalatine sutures induced by micro-implant-supported skeletal expander, analyzed with a novel 3D method based on CBCT imaging. *Prog. Orthod.* 18 (1), 34.
- Carlson, C., Sung, J., McComb, R.W., Machado, A.W., Moon, W., 2016 May. Micro-implant-assisted rapid palatal expansion appliance to orthopedically correct transverse maxillary deficiency in an adult. *Am. J. Orthod. Dentofacial Orthop.* 149 (5), 716–728.
- Celenk-Koca, T., Erdinc, A.E., Hazar, S., Harris, L., English, J.D., Akyalcin, S., 2018. Evaluation of miniscrew-supported rapid maxillary expansion in adolescents: a prospective randomized clinical trial. *Angle Orthod.* 88 (6), 702–709.
- Gogna, N., Johal, A.S., Sharma, P k, 2020. The stability of surgically assisted rapid maxillary expansion (SARME): a systematic review [Internet] *J. Cranio-Maxillofacial. Surg.* 48 (9), 845–852. <https://doi.org/10.1016/j.jcms.2020.07.003>. Available from:
- Gül, A., Pieter de Gijt, J., Wolvius, E.B., Koudstaal, M.J., 2021 Aug. Patient experience and satisfaction of surgically assisted rapid maxillary expansion and mandibular midline distraction. *J. Cranio-Maxillo-Fac. Surg.* 49 (8), 649–654. <https://doi.org/10.1016/j.jcms.2021.01.033>.
- Haas Junior, O.L., Guijarro-Martínez, R., De Sousa Gil, A.P., Méndez-Manjón, I., Valls-Otañón, A., De Oliveira, R.B., et al., 2019. Cranial base superimposition of cone-beam computed tomography images: a voxel-based protocol validation. *J. Craniofac. Surg.* 30 (6), 1809–1814.
- Hayes, M.H.S., Paterson, D.G., 1921. Experimental development of the graphic rating method. *Psychol. Bull.* 18, 98–99.
- Hernandez-Alfaro, F., Mareque Bueno, J., Diaz, A., Pagés, C.M., 2010 Sep. Minimally invasive surgically assisted rapid palatal expansion with limited approach under sedation: a report of 283 consecutive cases. *J. Oral Maxillofac. Surg.* 68 (9), 2154–2158.
- Jesus, A.S., et al., 2021. Nasomaxillary effects of miniscrew-assisted rapid palatal expansion and two surgically assisted rapid palatal expansion approaches. *Int. J. Oral Maxillofac. Surg.* (in press).
- Kayalar, E., Schauseil, M., Kuvat, S.V., Emekli, U., Firatli, S., 2016. Comparison of tooth-borne and hybrid devices in surgically assisted rapid maxillary expansion: a randomized clinical cone-beam computed tomography study. *J. Cranio-Maxillofacial Surg.* 44 (3), 285–293.
- Kayalar, E., Schauseil, M., Hellak, A., Emekli, U., Firatli, S., Korbmacher-Steiner, H., 2019. Nasal soft- and hard-tissue changes following tooth-borne and hybrid surgically assisted rapid maxillary expansion: a randomized clinical cone-beam computed tomography study. *J. Cranio-Maxillofacial Surg.* 47 (8), 1190–1197.
- Lin, L., Ahn, H.W., Kim, S.J., Moon, S.C., Kim, S.H., Nelson, G., 2015. Tooth-borne vs bone-borne rapid maxillary expanders in late adolescence. *Angle Orthod.* 85 (2), 253–262.
- Liu, S.Y.-C., Guilleminault, C., Huon, L.-K., Yoon, A., 2017. Distraction osteogenesis maxillary expansion (DOME) for adult obstructive sleep apnea patients with high arched palate. *Otolaryngology-Head Neck Surg. (Tokyo)* 157 (2), 345–348.
- Muñoz-Pereira, M.E., Junior, O.L.H., Da Silva Meirelles, L., Machado-Fernández, A., Guijarro-Martínez, R., Hernández-Alfaro, F., de Oliveira, R.B., Pagnoncelli, R.M., 2020. Stability and surgical complications of tooth-borne and bone-borne appliances in surgically assisted rapid maxillary expansion: a systematic review. *Br. J. Oral Maxillofac. Surg.* <https://doi.org/10.1016/j.bjoms.2020.08.017>.
- Oliveira, C.B., et al., 2021. Evaluation of factors related to the success of miniscrew-assisted rapid palatal expansion. *Angle Orthod.* 91 (2), 187–194.
- Salgueiro, D.G., Rodrigues, V.H. de O., Tieghi Neto, V., de Menezes, C.C., Gonçalves, E.S., Ferreira, O., 2015. Evaluation of opening pattern and bone neoformation at median palatal suture area in patients submitted to surgically assisted rapid maxillary expansion (SARME) through cone beam computed tomography. *J. Appl. Oral Sci.* 23 (4), 397–404.
- Seeberger, R., Abe-Nickler, D., Hoffmann, J., Kunzmann, K., Zingler, S., 2015 Dec. One-stage tooth-borne distraction versus two stage bone-borne distraction in surgically assisted maxillary expansion (SARME). *Oral Surg. Oral Med. Oral Pathol. Oral Radiol.* 120 (6), 693–698.
- Shin, H., Hwang, C.J., Lee, K.J., Choi, Y.J., Han, S.S., Yu, H.S., 2019. Predictors of midpalatal suture expansion by miniscrew-assisted rapid palatal expansion in young adults: a preliminary study. *Kor. J. Orthod.* 49 (6), 360–371.
- Smeets, M., Da Costa Senior, O., Eman, S., Politis, C., 2020. A retrospective analysis of the complication rate after SARPE in 111 cases, and its relationship to patient age at surgery [Internet] *J. Cranio-Maxillofacial. Surg.* 48 (5), 467–471. <https://doi.org/10.1016/j.jcms.2019.12.015>. Available from:
- Verstraaten, J., Kuipers-Jagtman, A.M., Mommaerts, M.Y., Bergé, S.J., Nada, R.M., Schols, J.G.J.H., 2010. A systematic review of the effects of bone-borne surgical assisted rapid maxillary expansion [Internet] *J. Cranio-Maxillofacial. Surg.* 38 (3), 166–174. <https://doi.org/10.1016/j.jcms.2009.06.006>. Available from:
- Vilani, G.N., Mattos, C.T., de Oliveira Ruellas, A.C., Maia, L.C., 2012 Dec. Long-term dental and skeletal changes in patients submitted to surgically assisted rapid maxillary expansion: a meta-analysis. *Oral Surg. Oral Med. Oral Pathol. Oral Radiol.* 114 (6), 689–697.
- Vinha, P.P., Thuler, E.R., de Mello-Filho, F.V., 2020. Effects of surgically assisted rapid maxillary expansion on the modification of the pharynx and hard palate and on obstructive sleep apnea, and their correlations [Internet] *J. Cranio-Maxillofacial. Surg.* 48 (4), 339–348. <https://doi.org/10.1016/j.jcms.2020.02.007>. Available from:
- Williams, B.J., Currimbhoy, S., Silva, A., O'Ryan, F.S., 2012 Oct. Complications following surgically assisted rapid palatal expansion: a retrospective cohort study. *J. Oral Maxillofac. Surg.* 70 (10), 2394–2402.
- Zandi, M., Miresmaeili, A., Heidari, A., 2014 Oct. Short-term skeletal and dental changes following bone-borne versus tooth-borne surgically assisted rapid maxillary expansion: a randomized clinical trial study. *J. Cranio-Maxillo-Fac. Surg.* 42 (7), 1190–1195.
- Zong, C., Tang, B., Hua, F., He, H., Ngan, P., 2019. Skeletal and dentoalveolar changes in the transverse dimension using microimplant-assisted rapid palatal expansion (MARPE) appliances [Internet] *Semin. Orthod.* 25 (1), 46–59. <https://doi.org/10.1053/j.sodo.2019.02.006>. Available from: