

RESTORATIVE DENTISTRY

Complete oral rehabilitation with direct and indirect composite resins: a minimally invasive approach on severely compromised teeth

Vinícius F. Lippert, DDS, MS/Jonas P. Andrade, DDS, MS, PhD/Ana M. Spohr, DDS, MS, PhD/
Marcel F. Kunrath, DDS, MS, PhD

The rehabilitation of severely worn teeth is a complex challenge for dental practitioners. There are many different types of dental materials and restorative techniques, and there is not a single way to achieve the desired result. This clinical report demonstrates a complete oral rehabilitation with composite resins when using an indirect application and direct techniques, with the support of the Lucia Jig technique, the Willis technique, and diagnostic waxing for the vertical dimension correction. The wide clinical improvement was achieved with the recovery of the function, the esthetics, and the increase of vertical dimension of occlusion through the planned treatment. The proposed treatment main-

tained the natural teeth, without the intense wear by the application of the composite resins instead of ceramics, together with excellent conditions for the patient to control the posttreatment and extend the durability, with the correct follow-up of appointments. Young patients with extensive dental wear and the loss of vertical dimension should not be directly submitted to ceramic treatments, with preparations for full crowns. Oral rehabilitation using composite resins, either directly or indirectly, allows for the recovery of the function and esthetics, without the intense predictable dental wear, and reduced financial investment.

(Quintessence Int 2022;53:824–831; doi: 10.3290/j.qi.b3315033)

Key words: direct resin, esthetic, indirect resin, occlusion, oral rehabilitation

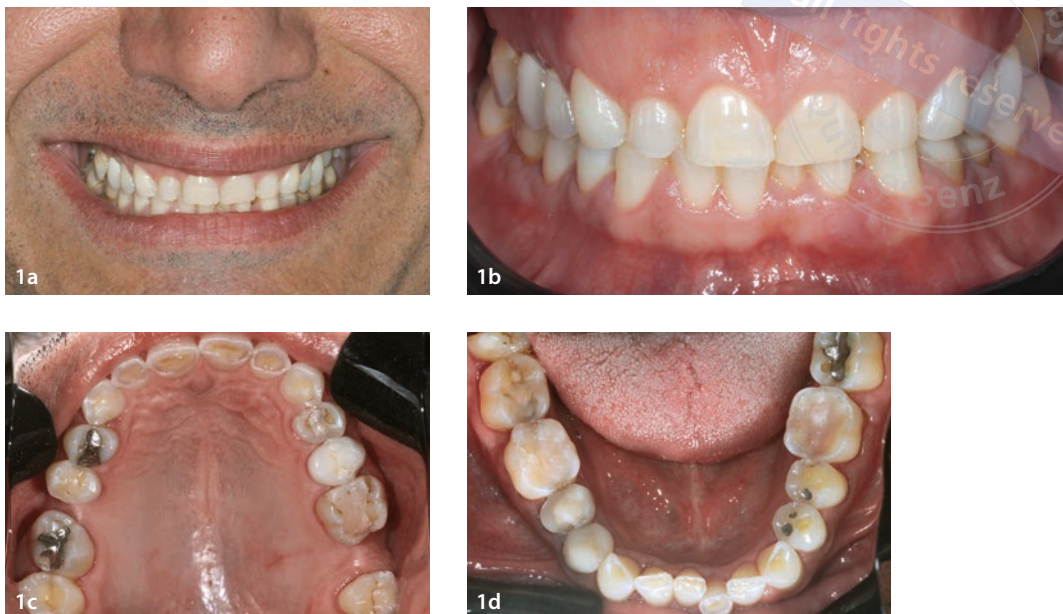The gradual loss of tooth enamel is a biologic condition that results from the aging process. However, the premature wear of this tissue is due to a combination of factors, such as friction (abrasion), occlusal stress (abfraction), and biocorrosion (erosion), with the last mentioned being the most predominant factor in this process.^{1,2} The action of acidic drinks, gastroesophageal reflux, bulimia, medications, drugs, and reduced salivary flow all contribute to the progression of these injuries.³

The treatment for dental erosion depends on the amount of dental structure loss and this must address the main factors promptly, to prevent a progression of this disease.^{3,4} The European Consensus Statement⁵ suggests that the restorative procedures should be postponed whenever possible. However, when these procedures are performed, they must be minimally invasive for reducing the pain and restoring the function and esthetics, through mutual agreement with the patient. The treatment of severe tooth wear is not a simple approach. The

planning must be conducted carefully, including the impression of the arches, photographs, and the assembly of the models in a semi-adjustable articulator and diagnostic waxing. This procedure can be performed in an analog or virtual way, to return a natural esthetic, and a stable and balanced occlusion.⁶

The restorative materials that are mainly used in the rehabilitation of patients with eroded teeth are metal-ceramic crowns, zirconia crowns, and glass ceramics, such as lithium disilicate ceramics, as well as composite resins that are made by both direct and indirect methods.⁷⁻¹⁰ Direct composite resins are the most economical option when resorted to in situations of mandibular dental wear.^{4,5} Currently, the indirect composite resins that are produced by the CAD/CAM process have been an option that has been well used for posterior teeth.¹¹ The literature shows countless types of treatments, and there is no consensus on which restorative technique is the best, exemplifying different advantages and disadvantages.

Figs 1a to 1d (a) Initial smile. (b) Intraoral initial view. (c) Intraoral occlusal maxillary view. (d) Intraoral occlusal mandibular view.



Nowadays, it is more common that patients, especially the young, look for conservative treatments, to avoid dental wear.¹² In addition, a therapeutic approach with composite resins provides better intraoral finishing and polishing, thus avoiding antagonistic tooth wear when compared to ceramics.¹³⁻¹⁵ Some *in vitro* studies have shown that the fracture resistance of occlusal veneers in composite resin is greater than occlusal veneers in glass ceramics, due to the fact that they have a lower elastic modulus and a better absorbs the tensions, which is beneficial for the stomatognathic system.¹⁶⁻²⁰

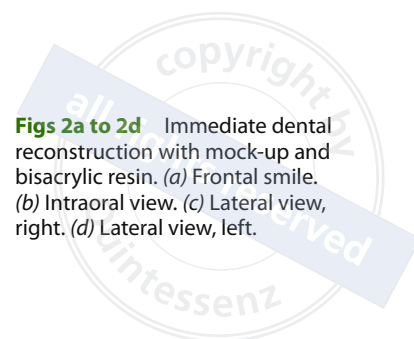
The purpose of this clinical report was to present an ultra-conservative clinical case of full-mouth rehabilitation that was made from composite resins, in a patient with extensive dental wear, using indirect (laboratory technique) and direct (stratified technique) methods.

Case presentation

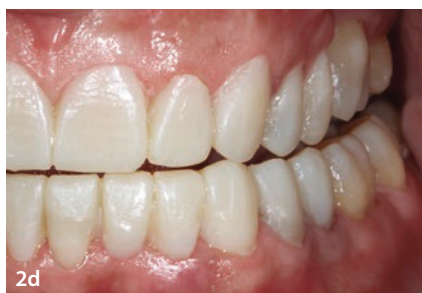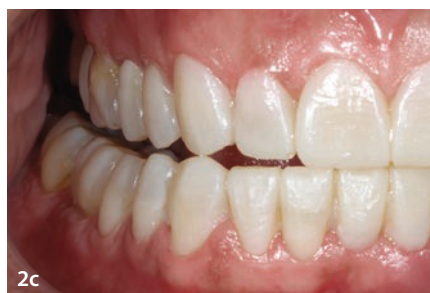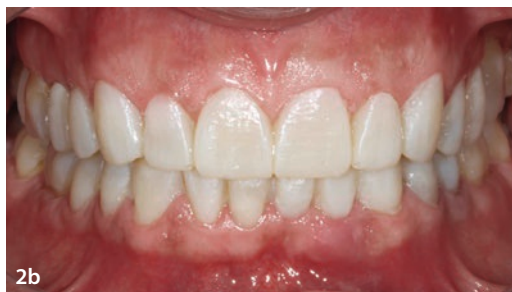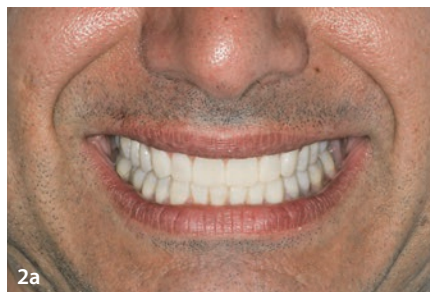A 45-year-old man who complained about frequent fractures on composite resin restorations and dental structures sought dental treatment at a private clinic. Anamnesis, clinical and radiographic examinations, photographs, and diagnostic casts were performed. These procedures revealed that the patient presented a loss of the vertical dimension of occlusion (VDO), which was associated with parafunction events and erosion (Fig 1). Due to the great dental wear and dentin exposure, a full-mouth rehabilitation treatment was proposed, with a restoration of the VDO, by

applying composite resins, to recover the function and esthetics, without aggressive additional wear on the teeth. Additionally, the patient was advised to control the intake of liquids and acid foods, combined with a medical follow-up.

Initially, adequate oral health was ensured, with prophylaxis and a replacement of all patient's aged restorations. The cavities were all sealed with Flowable Dental Composite Resin A2 (Natural Flow, DFL). Subsequently, for the extraoral planning, impressions of the maxillary and mandibular dental arches were made with polyvinyl siloxane (PVS) (Variotime, Kulzer), using the two-step technique, to obtain the casts for diagnostic waxing. The casts were mounted on an articulator (Bio-Art A7 Fix) for carrying out the transfer of the skull-maxilla relationship with the facial arch (Elite Facial Arch, Bio-Art). The VDO was reestablished by the Lucia Jig technique,²¹ with the posterior bilateral bite registration when using self-curing acrylic (GC Pattern Resin). The parameters that were applied were the metric method of Willis²² when using a compass, while the determination of the VDO was performed by subtracting 3 mm (freeway space) from the vertical dimension at rest, together with the Turner and Fox esthetic method when concerning the thirds of the face.²³ In addition, an unconditioned resin veneer increment over the patient's maxillary central incisor was performed, and this was sent to the laboratory as a length reference for the diagnostic waxing. The difference that was provided after the protocols for the VDO increase when using the articulator was 3 mm from the initial measurement.



Figs 2a to 2d Immediate dental reconstruction with mock-up and bisacrylic resin. (a) Frontal smile. (b) Intraoral view. (c) Lateral view, right. (d) Lateral view, left.



The diagnostic waxing was made by a dental technician, with the aim of performing full-mouth rehabilitation, by applying the direct and indirect composite resins, whilst recovering the dental health, the anatomy, the esthetics, and the VDO. Two PVS (Variotime) guides on the waxing were made for the mock-up by using A1 colored bisacrylic resin (Structur 2, Voco). With the reproduction of the wax-up in the mouth with bisacrylic resin, the evaluation of the esthetic aspects and the phonetic tests were performed to check the increase in the VDO. Furthermore, the contact points and the guides were both evaluated (Fig 2).

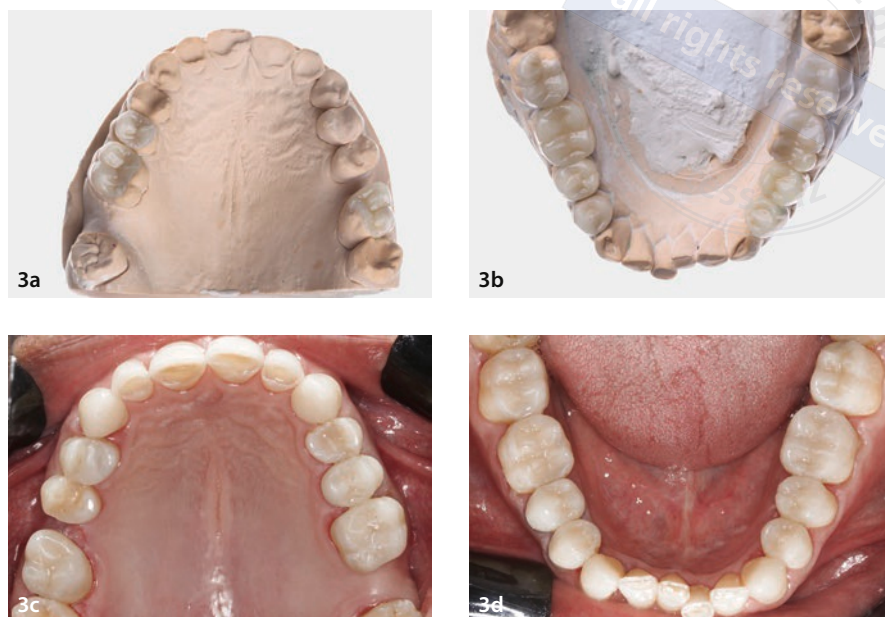
Regarding the previous esthetic procedures for the main treatment, a periodontal surgery of the maxillary anterior teeth (canine to canine) was performed, with an electric scalpel (B 100 Plus, Rhosse) but only over the soft tissue (0.5 mm in the maxillary left central incisor and 0.5 mm in the maxillary right lateral incisor), aiming at the gingival recontour by equalizing the gingival zenith. The CT scan was performed with soft tissue retraction, to precisely identify the distances between the bone crest and the gingival margin, the bone crest and the cemento-enamel junction, and the gingival margin and the cemento-enamel junction. From this evaluation, it was verified what would be necessary to esthetically improve the situation when using the diagnostic wax-up, and this identified the need for only the removal of the soft tissue. A duplication of the diagnostic wax-up was performed and a

surgical guide was made with an acetate plate to perform the procedure. After 30 days, a dental night guard bleaching technique was carried out for 4 weeks when using a 10% carbamide peroxide gel (Whiteness Perfect 10%, FGM Dental Group), for daily use with a 24-hour interval between each application. The patient was recommended to use a toothpaste with properties for sensitivity protection during the whitening, and there was no report of any discomfort. After the bleaching, the color of the teeth was recorded with the Vita Classical Shade Guide, for selection of the composite resin to be used in the rehabilitation procedure. An additional color investigation was carried out, by using small resin spheres to compare with the tooth substrate.

Indirect composite resins and adhesive procedure

To carry out the indirect composite resin restorations and to increase the VDO, the retentions were removed, and the acute angles of posterior teeth (15, 16, 27, 34 to 37, and 44 to 47, according to FDI notation) were rounded by finishing and polishing disks (Sof-Lex, 3M Espe), followed by impressions of the dental arches with PVS. Indirect composite resins (Ceramage, Shofu Dental) were produced in the laboratory, by using transparent guides, according to the diagnostic waxing that was previously approved, with the objective of providing better mechanical properties.²⁴ Initially, the indirect composite resins

Figs 3a to 3d (a and b) The indirect resins at the planning stage, and (c and d) the indirect resins after the adhesion to the patient's teeth.

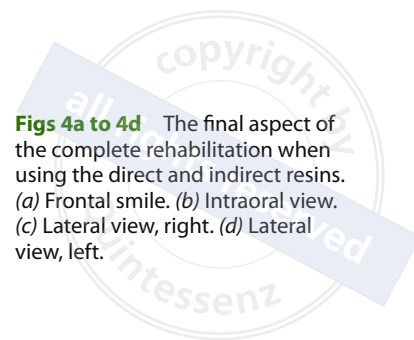


were tested without rubber dam isolation, to verify the adaptation of the margins. In sequence, under isolation with rubber dam (Madeitex, Brazil) the luting procedures were performed, and a further test was carried out to carefully observe the adaptation and contact points. The internal surface of each composite resin was blasted with 50 μm aluminum oxide, followed by an application of silane (Prosil, FGM Dental Group) for 2 minutes, with a Single Bond Universal Adhesive system (3M Espe), and a subsequent light jet of air (like a jet wash for the teeth), without photoactivation. On the dental substrate, selective etching (Ultra-Etch, Ultradent) was performed on the enamel for 30 seconds, with a subsequent washing and drying, and the Single Bond Universal Adhesive system was applied, with a subsequent light jet of air, without photoactivation. For the cementation, dual-cure resin cement (RelyX Ultimate, 3M) was used, which was positioned on the internal surface of the indirect composite resin, and then adapted for the dental substrate. The removal of the excess cement was conducted with a microbrush and dental floss, followed by photopolymerization for 60 seconds on each face, with a VALO poly-wave device (Ultradent) in a standard mode (1,000 mW/cm^2). An additional polymerization per face was carried out after applying a water-soluble gel (Power Block, BM4), thus inhibiting the contact of the resin cement with oxygen from the external environment. After removing the absolute isolation, and with the Lucia Jig in position, the occlusal adjustments were made, with the

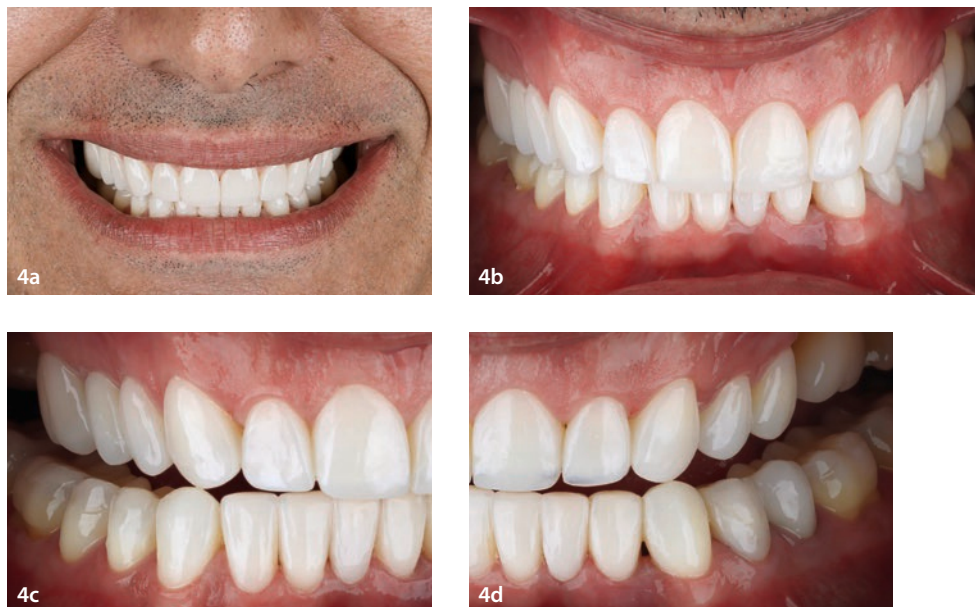subsequent finishing and final polishing of all the teeth (Fig 3). The EVE Diacomp Twist system (pink and gray rubber) and a felt disk with universal polishing paste (Diamond Excel, FGM Dental Group) were used for the finishing and polishing procedures. On the same day, provisional direct composite resins were performed on the teeth 13, 23, 33, and 43, to give contact with the anterior sector and the canine guides.

Direct composite resins

At the next appointment, direct restorations using the stratified technique were performed on the maxillary and mandibular anterior teeth. However, due to the inadequate position of the mandibular left central incisor (tooth 31) and the option of not performing the orthodontic treatment as first indicated, the buccal surface preparation was performed by correcting the positioning of this specific tooth. To execute these direct restorations, silicone palatal guides were made on the models of the diagnostic waxing. These helped in making the first palatal and lingual layer of all the elements. The composite resins that were used were the A1E palatal layer (Empress Direct, Ivoclar), the A2D dentin layer (Estelite Omega, Tokuyama), the Trans incisal effect (Estelite Omega), and the EB1 final layer (Estelite Omega), respectively. For the finishing process, a surgical scalpel blade no. 12, FF diamond tips (KG Sorensen), a 3M Sof-Lex disk, and multi-laminated dental burs (Jota) were used to remove the



Figs 4a to 4d The final aspect of the complete rehabilitation when using the direct and indirect resins. (a) Frontal smile. (b) Intraoral view. (c) Lateral view, right. (d) Lateral view, left.



excesses and delimit the texture. Diamond spiral rubbers from Eve Diacomp Twist (pink and gray), felts, and a universal polishing paste (Diamond Excel) were used for the polishing process. Furthermore, the posterior teeth (14, 24, and 25), in which the indirect restorations were not performed, received direct restorations, reestablishing the missing occlusal contacts. The reason for applying the direct restorations on these specific teeth was diagnosed due to the small thickness of the resin that was needed for the restorations, which made it difficult to manufacture the indirect restorations in the laboratory.

All the mandibular movements and guides were checked, and an immediate protective 1-mm temporary acetate plate was made for the patient to use at night. Posteriorly, the patient returned for a final finishing and polishing appointment (Fig 4), to identify any excess that was still present. Following this procedure, a night guard was manufactured for adjusting all the occlusal contacts, with the indication of night use.

The final case registration showed an esthetic improvement and a functional rehabilitation due to the recovery of the VDO in a well-stabilized position, and the reconstruction of the teeth's natural size. Thereafter, the patient returned for a 1-year follow-up, and no damage was observed as a result of the rehabilitation. The patient agreed with the constant use of the night guard, with the intention of protecting his rehabilitation. New photographs were taken, without any repolishing, to identify any possible wear or pigmentation (Fig 5). ■■

Discussion

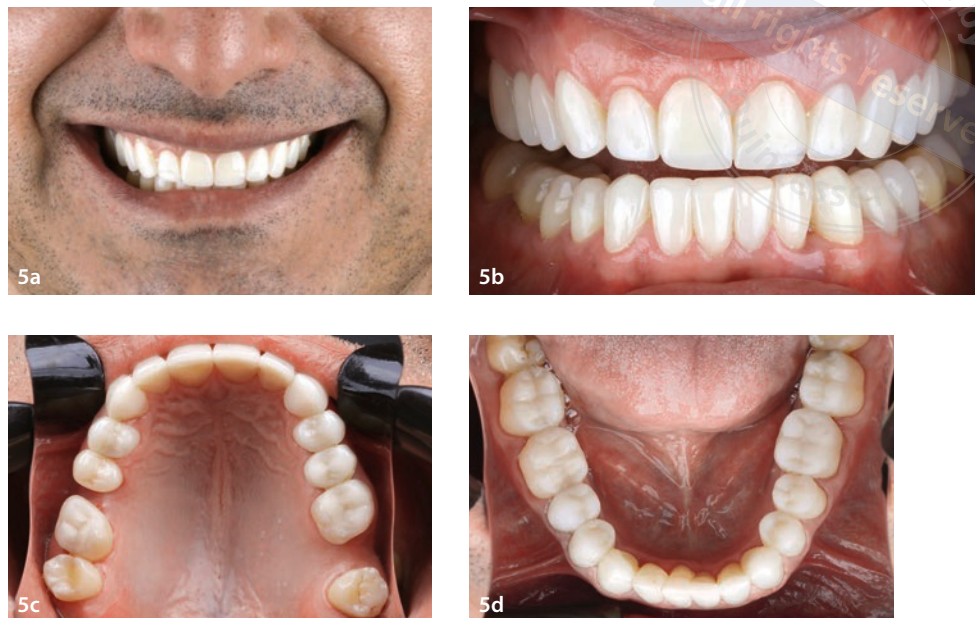
The premature loss of the VDO and the severe tooth wear were not related to only one reason. There occurred a combination of factors, such as attrition (bruxism), abrasion, and erosion, which all led to this deleterious result.^{2,3,26}

The wear of the posterior cusps provided an overload on the anterior teeth and the incisal wear of the anterior teeth generated an occlusal overload on the posterior teeth. In other words, the occlusal balance was directly related to a mutually protected occlusion at the maximum habitual intercuspation (formerly named centric occlusion), in a combination with the laterality and protrusion guides. The loss of the guides can cause early wear of the molar and premolar cusps, as well as the non-carious cervical lesions, known as abfraction.^{25,27,28}

It has become increasingly prevalent to find severe dental wear in young patients. This is probably due to bruxism and diet changes with acidic foods, due to their current chosen lifestyle. The fact is that premature dental wear is now a reality, and how dentistry professionals should treat these patients is a challenge to be faced.^{8,26}

First, it is essential to identify and treat the main etiologic factors of dental wear for the long-term success of any restorative treatment. Second, the choice of the most suitable material available in the market is important. This is controversial and can generate doubt for the dental surgeon because there is no

Figs 5a to 5d Patient follow-up (1 year). (a) Frontal smile. (b) Intraoral view. (c) Intraoral maxillary view. (d) Intraoral mandibular view.



consensus in the literature concerning the best restorative material for severely worn teeth.

The use of composite resins in patients with eroded teeth is one of the current options and this strategy is well-accepted today because it allows for minimally invasive techniques and provides adequate intraoral finishing and polishing.^{4,5} It likewise prevents antagonistic teeth wear.^{13,21}

The composite resin brand for the posterior teeth that was selected in this case study was Ceramage (Shofu Dental), which is a micro-hybrid composite resin for laboratory use. This composite, as well as the nano-hybrids, is indicated for the posterior teeth because it presents better mechanical properties (hardness, abrasive resistance, and flexural resistance) when compared to the microfilled composite resins, which have better polishing properties and surface gloss.^{14,21} In the anterior sector, two different commercial brands were used in this case report. Empress Direct resin (nano-hybrid resin) was used in the palatal layer to provide better mechanical resistance in the excursion movements. The other commercial brand that was used was the Estelite Omega resin, and this presented better rheologic, finishing, and polishing properties. The best smoothness and surface gloss properties of the Estelite Omega resin were mainly related to the spherical and regular inorganic filler particle sizes.²⁹⁻³¹

After the end of any rehabilitation, the dental practitioner must be aware of the patient's occlusion in the centric and eccentric movements. Occlusal overloads can generate failures,

such as chipping and fracture.^{32,33} Another relevant factor is recalling the patients periodically to adjust and repolish the composite resin restorations, while checking the occlusal contacts and for possible early wear.

The limitations of the treatment presented in this clinical report are linked to the engagement of the patient in the care of his rehabilitation, with periodic appointments, as well as the daily care at home. It is extremely important that the patient changes deleterious habits to increase the restorations' longevity, as well using a night mouth guard.

Conclusion

Within the limitations of the current clinical case, it was concluded that a full-mouth rehabilitation by using composite resins was one of the attainable options for the dental treatment because it required less dental wear. It was economical and less abrasive to the antagonistic teeth than ceramics, thus mainly benefitting the younger patients, who still need to maintain their natural teeth intact for a long time. The treatment technique requires training and attention at all stages of the execution. In addition, it is necessary to follow-up with the patients by scheduling periodic maintenance appointments (polishing, checking the occlusal contacts, and ascertaining the excursion movements), to increase the longevity of this dental rehabilitation. ■■

Acknowledgment


The author MFK thanks the Osteology Foundation, Switzerland, for financial support. during his research period at the Department of Biomaterials, The Sahlgrenska Academy at University of Gothenburg, Gothenburg, Sweden.

Disclosure

The authors do not have any financial interest in the companies whose materials are included in this article.

References

1. Bartlett D, Phillips K, Smith B. A difference in perspective: the North American and European interpretations of tooth wear. *Int J Prosthodont* 1999;12:401–408.
2. West NX, Joiner A. Enamel mineral loss. *J Dent* 2014;42:2–11.
3. Peumans M, Politano G, Van Meerbeek B. Treatment of noncarious cervical lesions: when, why, and how. *Int J Esthet Dent* 2020; 15:16–42.
4. Carvalho TS, Colon P, Ganss C, et al. Consensus report of the European Federation of Conservative Dentistry: erosive tooth wear—diagnosis and management. *Clin Oral Investig* 2015;19:1557–1561.
5. Loomans B, Opdam N, Attin T, et al. Severe tooth wear: European Consensus Statement on Management Guidelines. *J Adhes Dent* 2017;19:111–119.
6. Vailati F, Belsler UC. Full-mouth adhesive rehabilitation of a severely eroded dentition: the three step technique. Part 1. *Eur J Dent* 2008;3:30–44.
7. Kavoura V, Kourtis SG, Zoidis P, Andritsakis DP, Doukoudakis A. Full-mouth rehabilitation of a patient with bulimia nervosa. A case report. *Quintessence Int* 2005;36: 501–510.
8. Rinke S, Fischer C. Range of indications for translucent zirconia modifications: clinical and technical aspects. *Quintessence Int* 2013;44:557–566.
9. Mesko ME, Sarkis-Onofre R, Cenci MS, et al. Rehabilitation of severely worn teeth: A systematic review. *J Dent* 2016;48:9–15.
10. Edelhoff D, Ahlers MO. Occlusal onlays as a modern treatment concept for the reconstruction of severely worn occlusal surfaces. *Quintessence Int* 2018;49:521–533.
11. Mainjot AK, Dupont NM, Oudkerk JC, et al. From artisanal to CAD-CAM blocks: state of the art of indirect composites. *J Dent Res* 2016;95:487–495.
12. Resende TH, Reis KR, Schlichting LH, et al. Ultrathin CAD-CAM ceramic occlusal veneers and anterior bilaminar veneers for the treatment of moderate dental bio-corrosion: a 1.5-year follow-up. *Oper Dent* 2018;43:337–346.
13. Wiegand A, Credé A, Tschammler C, Attin T, Tauböck TT. Enamel wear by antagonistic restorative materials under erosive conditions. *Clin Oral Investig* 2017;21: 2689–2693.
14. Zhao X, Pan J, Zhang S, Malmstrom HS, Ren YF. Effectiveness of resin-based materials against erosive and abrasive enamel wear. *Clin Oral Investig* 2017;21:463–468.
15. Yadav R, Kumar M. Dental restorative composite materials: A review. *J Oral Biosci* 2019;61:78–83.
16. Magne P, Schlichting LH, Maia HP, et al. In vitro fatigue resistance of CAD/CAM composite resin and ceramic posterior occlusal veneers. *J Prosthet Dent* 2010;104:149–157.
17. Schlichting LH, Maia HP, Baratieri LN. Novel-design ultra-thin CAD/CAM composite resin and ceramic occlusal veneers for the treatment of severe dental erosion. *J Prosthet Dent* 2010;105:217–226.
18. Johnson AC, Versluis A, Tantbirojn D, et al. Fracture strength of CAD/CAM composite and composite-ceramic occlusal veneers. *J Prosthodont Res* 2014;58:107–114.
19. Egbert JS, Johnson AC, Tantbirojn D, et al. Fracture strength of ultrathin occlusal veneer restorations made from CAD/CAM composite or hybrid ceramic materials. *Oral Sci Int* 2015;12:53–58.
20. Schlichting LH, Resende TH, Reis KR, et al. Simplified treatment of severe dental erosion with ultrathin CAD-CAM composite occlusal veneers and anterior bilaminar veneers. *J Prosthet Dent* 2016;116:474–482.
21. Lucia VO. Centric relation: theory and practice. *J Prosthet Dent* 1960;10:849–856.
22. Willis FM. Esthetic of full denture construction. *J Am Dent Assoc* 1930;17:633–642.
23. Geerts GAVM, Stuhlinger ME, Nel DG. A comparison of the accuracy of two methods used by pre-doctoral students to measure vertical dimension. *J Prosthet Dent* 2004;91:59–66.
24. Yadav RD, Raisingani D, Jindal D, Mathur R. A comparative analysis of different finishing and polishing devices on nano-filled, microfilled, and hybrid composite: a scanning electron microscopy and profilometric study. *Int J Clin Pediatr Dent* 2016; 9:201–208.
25. Sreekumar AV, Rupesh PL, Pradeep N. Nature of occlusion during eccentric mandibular movements in young adults. *J Contemp Dent Pract* 2012;13:612–617.
26. Wetselaar P, Lobbezoo F. The tooth wear evaluation system: a modular clinical guideline for the diagnosis and management planning of worn dentitions. *J Oral Rehabil* 2016;43:69–80.
27. Katona TR, Eckert GJ. The mechanics of dental occlusion and disclusion. *Clin Biomech* 2017;50:84–91.
28. Kumar M, Verma R, Bansal M, et al. To evaluate the severity, distribution of occlusal tooth wear and its correlation with bite force in young North Indian adults. *Open Dent J* 2018;12:735–741.
29. Ilie N, Hickel R. Investigations on the mechanical behavior of dental composites. *Clin Oral Investig* 2009;13:427–438.
30. Ilie N, Rencz A, Hickel R. Investigations towards nano-hybrid resin-based composites. *Clin Oral Investig* 2013;17:185–193.
31. Can Say E, Yurdagüven H, Yaman BC, et al. Surface roughness and morphology of resin composites polished with two-step polishing systems. *Dent Mater J* 2014;33: 332–342.
32. Belli R, Geinzer E, Muschweck A, Petschelt A, Lohbauer U. Mechanical fatigue degradation of ceramics versus resin composites for dental restorations. *Dent Mater* 2014;30:424–432.
33. Demarco FF, Collares K, Coelho K, et al. Anterior composite restorations: A systematic review on long-term survival and reasons for failure. *Dent Mater* 2015;31: 1214–1224.



Vinícius F. Lippert

Vinícius F. Lippert Associate Professor, Department of Restorative Dentistry, School of Health and Life Sciences, Pontifical Catholic University of Rio Grande do Sul (PUCRS), Porto Alegre, RS, Brazil

Jonas P. Andrade Associate Clinical Researcher, Department of Restorative Dentistry, School of Health and Life Sciences, Pontifical Catholic University of Rio Grande do Sul (PUCRS), Porto Alegre, RS, Brazil

Ana M. Spohr Full Professor, Department of Restorative Dentistry, School of Health and Life Sciences, Pontifical Catholic University of Rio Grande do Sul (PUCRS), Porto Alegre, RS, Brazil

Marcel F. Kunrath Associate Researcher, Post-Graduate Program of Dentistry, School of Health and Life Sciences, Pontifical Catholic University of Rio Grande do Sul (PUCRS), Porto Alegre, RS, Brazil; and Postdoctoral Researcher, Department of Biomaterials, Institute of Clinical Sciences, The Sahlgrenska Academy at University of Gothenburg, Gothenburg, Sweden

Correspondence: Vinícius Funghetto Lippert, Department of Restorative Dentistry, School of Health and Life Sciences, Pontifical Catholic University of Rio Grande do Sul (PUCRS), Avenida Ipiranga, 6681 Porto Alegre, Rio Grande do Sul, 90619-900, Brazil. Email: vinicius.lippert@pucrs.br