

A Comparison of Wedge and Needle Hepatic Biopsy in Open Bariatric Surgery

Alexandre Vontobel Padoin, MD¹; Cláudio Corá Mottin, MD, PhD¹; Myriam Moretto, MD; Diovanna Berleze, MD; Carlos Kupski, MD, PhD; Luiz Glock, PhD; Carlos Luiz Reichel, MD²; Vinicius Duval da Silva, MD, PhD²; Jefferson Braga da Silva, MD, PhD

Centro da Obesidade Mórbida, Hospital São Lucas da PUCRS (COM HSL/PUCRS), ¹Department of Surgery, ²Department of Pathology, Porto Alegre, Brazil

Background: Morbidly obese patients, despite normal laboratory tests and no clinical evidence of liver disease, present a high prevalence of hepatic histological changes. Liver biopsy is able to provide the diagnosis, staging and assessment of follow-up of hepatic disease, thus helping to define clinical management. There is no agreement on which biopsy technique provides better material for analysis. Considering that subcapsular fibrosis is a common finding, sampling from deeper sites is necessary to achieve an adequate histological assessment.

Methods: A study was done in 264 consecutive morbidly obese patients who underwent open Roux-en-Y gastric bypass between July 2001 and Sept 2004, in whom an intraoperative liver biopsy was taken. The first 107 were wedge biopsies, and the last 157 were needle biopsies. The histological degree of steatosis, presence of fibrosis and adequacy of material from the 2 biopsy techniques were compared.

Results: Degree of steatosis in both sampling techniques showed no statistical difference ($P=0.132$). The presence of fibrosis in wedge biopsies (46.1% fibrosis, n 41) was significantly higher than in needle biopsies (13.7% fibrosis, n 20), $P<0.001$. As expected, sample size of needle biopsies was smaller than that obtained by the wedge technique ($P<0.001$), but there was no difference in the quality of material obtained ($P=0.95$).

Conclusion: Needle biopsies were as effective as wedge biopsies in assessing the degree of steatosis in morbidly obese patients. More important, the presence of subcapsular fibrosis in needle biopsies was less than in wedge biopsies, suggesting an adequate tissue sample by the less invasive technique.

Key words: Liver biopsy, hepatic steatosis, morbid obesity, bariatric surgery

Reprint requests to: Alexandre Vontobel Padoin, MD, Av. Ipiranga 6690/302, Porto Alegre, RS, Brazil 90610-000. Fax: + 55 51 33360890; e-mail: alexandre@padoin.med.br

Introduction

Hepatic biopsy is considered the gold standard for the diagnosis of conditions like steatosis, chronic hepatitis and cirrhosis, and also to identify normal liver parenchyma.^{1,2} Current imaging methods are able to suggest some of the pathologic conditions mentioned above, but with some limitation.³⁻⁵ Only hepatic biopsy can differentiate steatohepatitis from steatosis, also allowing its staging.^{3,5,6} The biopsy is a relatively safe method for diagnosis, allowing also some prognostic considerations for those diseases.^{1,2} The prevalence of hepatic changes in morbidly obese patients is high, even in the presence of normal laboratory tests and no clinical evidence of disease.⁷⁻⁹ Hepatic steatosis is the most common histological finding in morbidly obese patients, with the possibility of progression to steatohepatitis and cirrhosis.¹⁰⁻¹² Therefore, hepatic biopsy has an important role for early diagnosis, grading and staging of these conditions, with implications for the management of such patients.^{8,10,12-17}

Wedge biopsy usually provides a generous amount of material to the pathologist, but care should be taken to avoid a superficial sample, because it is known that shallow tissue sampling is not representative of the inner parenchyma.¹ Subcapsular areas usually present with structural variations, mainly fibrosis and nodules, that are considered a normal finding of hepatic tissue, but may lead to a wrong diagnosis (Figure 1).^{1,2} To avoid this potential problem, the ideal wedge biopsy sample must be taken deeper than 1.0 cm.^{1,2} Needle biopsy has been sug-

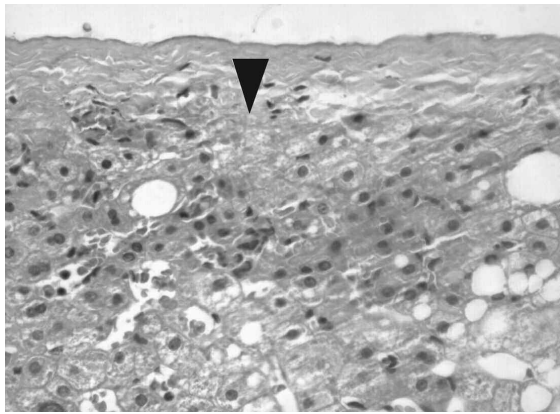


Figure 1. Wedge biopsy showing liver capsule and areas of subcapsular fibrosis in the upper center (arrow). There are several hepatocytes presenting macro- and microvesicular steatosis. (H&E, x200).

gested as an alternative to intraoperative wedge biopsy, because it allows a deeper sampling of liver tissue, avoiding the amount of subcapsular fibrosis collected by wedge biopsies.²

Tru-Cut[®] needles provide a non-fragmented sample, even in the presence of fibrosis.¹ Needle biopsy samples are thought to represent a fraction of 1/50,000 of the hepatic parenchyma,² thus not representing an important problem in diffuse hepatic diseases such as hepatitis, steatosis and cirrhosis.^{1,2} Size and tissue integrity, as well as careful processing (embedding, sectioning, and staining) of the needle biopsies are of paramount importance for diagnosis.² In order to allow proper evaluation of hepatic parenchyma, it has been suggested that needle biopsies are not fragmented and have a length between 1 and 2 cm, and an adequate number of portal triads. However, there is no agreement on the number of portal triads that have to be evaluated in order to be representative of the entire liver status. Different authors have proposed as a minimum requirement 4,¹ 6,¹⁸ or even 10 portal triads.¹⁹

Even though hepatic biopsy is considered the gold standard for liver disease, there is no agreement on which of the two types of biopsy is better for histological diagnosis. Literature searches have not shown studies comparing the results of different methods of biopsy during conventional open bariatric surgery.

The aim of this paper is to compare wedge and needle liver biopsy during open bariatric surgery, considering histological diagnosis, degree of steatosis, presence of fibrosis and material adequacy.

Materials and Methods

From July 2001 to Sept 2004, 295 consecutive patients underwent open Roux-en-Y gastric bypass (RYGBP) at the Centro da Obesidade Mórbida do Hospital São Lucas da Pontifícia Universidade Católica do Rio Grande do Sul. From the initial group, 31 were excluded from the study for the following reasons: 1 patient presented physical deformities that affected anthropometric measurement, 23 underwent the surgery laparoscopically, 3 underwent Scopinaro's biliopancreatic diversion, 2 tested positive for hepatitis C virus, and the biopsies of 2 patients were studied in a different pathology laboratory.

Intraoperative hepatic biopsy is considered part of the routine surgical protocol, and was performed by wedge biopsy until July 2002, when this technique was replaced by Tru-Cut[®] needle biopsy (1 mm diameter).

The wedge biopsies included a 3-cm deep section, followed by cauterization and suture. Tru-Cut[®] biopsies under direct visualization were followed by cauterization of the biopsy bed area. All samples were performed on hepatic segment III. All biopsies were processed, stained (hematoxylin and eosin) and analyzed on the Pathology Service of our hospital by two pathologists. The degree of steatosis was classified according to Burt.²⁰ This anatomical pathology classification considers the amount of hepatic parenchyma involved (mild, <1/3; moderate, 1/3-2/3; and severe, >2/3). The comparison between biopsy methods was performed only in the patients with steatosis, which represented 91% of all biopsies studied. Biopsies with <6 portal triads or artifacts were rejected.

Both groups of patients were compared regarding age, gender, body mass index (BMI), waist/hip ratio and prevalence of co-morbidities such as arterial hypertension, diabetes mellitus and dyslipidemia, to verify sample homogeneity.

Patients with fasting glucose ≥ 126 mg/dl (measured at least twice), or patients whose oral glucose tolerance tests (after 75 g of glucose) showed impaired results (>200 mg at 2 hours) were considered diabetic, as were those with a previous diagnosis of diabetes who were on pharmacological treatment.

Patients who were being treated with anti-hypertensive agents, independent of whether they were

Padoin et al

stabilized or not, and/or subjects with values of systemic arterial pressure $\geq 140/90$ mmHg, were considered hypertensive.

Subjects with total cholesterol ≥ 200 mg/dl, triglycerides ≥ 150 mg/dl or HDL-cholesterol < 40 mg/dl for males and < 50 for females or LDL-cholesterol ≥ 130 mg/dl were considered dyslipidemic. Those who were already being treated with oral hypolipemic agents were also considered dyslipidemic.

Results were analyzed with statistical program SPSS (Chicago, USA). Quantitative variables were compared by ANOVA and categorical variables by Chi-Square test. Population estimates were performed for all variables. Significance level was $P \leq 0.05$, and population estimates presented a confidence interval of 95%. The study was approved by the Pontificia Universidade Católica do Rio Grande do Sul Research and Ethics Committee.

Results

Of 264 patients who underwent RYGBP, 185 were female (70.1%). Table 1 presents mean age, BMI, waist/hip ratio, and prevalence of hypertension, diabetes and lipid disorders of patients submitted to wedge or needle biopsy. There were no significant differences between both groups, except for biopsy length ($P < 0.001$).

Table 2 shows the histological findings of the two groups in detail. From a total of 258 biopsies (6 biopsies having been considered inadequate), 94.2% presented histological changes, and only 15 patients (5.8%) had normal parenchyma. The most common finding was steatosis, present in 235 patients (91.0%). From these patients, 89 (37.9%) had wedge biopsies and 146 (62.1%) had needle biopsies.

Table 3 shows only patients with steatosis, and

Table 1. Profile of patients with biopsy performed by wedge or needle technique

	Wedge biopsy N = 107	Needle biopsy N = 157	Total N = 264	P
Age (years)	36.0 \pm 10.1	37.9 \pm 11.0	37.1 \pm 11.0	0.186
BMI (kg/m ²)	48.5 \pm 8.2	48.8 \pm 8.6	48.7 \pm 8.4	0.798
Waist/Hip ratio	0.93 \pm 0.112	0.95 \pm 0.098	0.94 \pm 0.104	0.381
Female	77 (72.0%)	108 (68.8%)	185 (70.1%)	0.580
Diabetes	13 (12.1%)	30 (19.1%)	43 (16.3%)	0.133
Hypertension	63 (58.9%)	99 (63.10%)	162 (61.4%)	0.494
Dyslipidemia	76 (71.0%)	98 (62.4%)	174 (65.9%)	0.147
Biopsy length (cm)	1.62 \pm 0.32	0.79 \pm 0.48	1.13 \pm 0.58	<0.001

Table 2. Histological findings compared to the biopsy method

	Wedge biopsy N = 107	Needle biopsy N = 157	Total N = 264
Inadequate material	2 (1.9%)	4 (2.5%)	6 (2.3%)
	Wedge biopsy N = 105	Needle biopsy N = 153	Total N = 258
Normal hepatic tissue	12 (11.4%)	3 (1.9%)	15 (5.8%)
Steatosis	89 (84.8%)	146 (95.4%)	235 (91.0%)
Steatohepatitis	2 (1.9%)	2 (1.3%)	4 (1.5%)
Chronic hepatitis	0	2 (1.3%)	2 (0.8%)
Cirrhosis	2 (1.9%)	0	2 (0.8%)

Table 3. Profile of patients with steatosis according to the biopsy technique

	Wedge biopsy	Needle biopsy	Total	P
	N = 89	N = 146	N = 235	
Age (years)	37.2 ±11.0	37.8 ±10.6	37.6 ±10.7	0.711
BMI (kg/m ²)	48.6 ±8.4	48.7 ±8.5	48.6 ±8.5	0.924
Waist/Hip ratios	0.94 ±0.114	0.95 ±0.098	0.95 ±0.104	0.694
Female	64 (71.9%)	99 (67.8%)	163 (69.4%)	0.508
Diabetes	12 (13.5%)	27 (18.5%)	39 (16.6%)	0.317
Hypertension	53 (59.6%)	94 (64.4%)	147 (62.6%)	0.458
Dyslipidemia	61 (68.5%)	89 (61.0%)	150 (63.8%)	0.241

Table 4. Degree of steatosis according to biopsy method

	Wedge biopsy N = 89	Needle biopsy N = 146	Total N = 235
Mild Steatosis	27 (30.3%)	50 (34.2%)	77 (32.8%)
Moderate Steatosis	19 (21.3%)	44 (30.1%)	63 (26.8%)
Severe Steatosis	43 (48.3%)	52 (35.6%)	95 (40.4%)

P=0.132

demonstrates no statistically significant difference between the patient's profile in the two groups. Table 4 presents the different degrees of steatosis in both groups of patients; again, there was no significant difference between the groups.

Fibrosis was identified in 61 biopsies (26.0%). 41 wedge (46.1%) and 20 needle (13.7%) presented fibrosis, with a significant difference between groups (*P*<0.001). From the 6 biopsies with inadequate material, 2 (1.9%) were wedge and 4 (2.5%) were needle, showing no significant difference (*P*=0.95).

Discussion

This study revealed a high prevalence of hepatic histological changes in morbidly obese patients, similar to previous published studies.^{8-10,12} The study included only patients in whom steatosis was the only hepatic abnormality, a finding present in 91.0% of the biopsies studied. Steatosis is a diffuse parenchymal process with a very high prevalence in morbidly obese patients, therefore being a good model for study.

Normal histology was found in 12 patients (11.2%) who underwent wedge biopsies and 3 (1.9%) who underwent needle biopsies. This difference could be

related to the low number of normal biopsies in this study (5.7%), and may be due to chance only.

There were 2 biopsies (1.9%) considered inadequate for analysis in the wedge biopsy group and 4 (2.5%) in the needle biopsy group. According to the literature,¹ the chance of inadequate material increases when the biopsy length is <0.5 cm. Other authors have suggested that inadequate material increases when a sample of ≤1.0 cm is obtained.¹⁹ In this study, even considering the significant difference in tissue size obtained by needle biopsy (*P*<0.001), there was no significant difference between wedge and needle biopsy when comparing the quality of tissue for analysis. Also, the presence and degree of steatosis was not significantly different between the two techniques. Subjective criteria for grading histological data have been criticized in the literature.^{21,22} In order to reduce this problem, we considered it essential that all samples were seen in the same pathology laboratory. Considering the high prevalence and clinical importance of steatosis in morbidly obese patients, new quantitative methods to achieve an accurate and reproducible classification of the degree of steatosis should be pursued.

The presence of fibrosis was significantly higher in wedge biopsies. This finding may be explained by the presence of more artifacts, such as subcapsular

Padoin et al

fibrosis, even in a properly performed wedge biopsies. This finding could also be related to the fact that fibrosis can be better assessed by staining with picrosirius red,²² which was not used in this study.

Although the two biopsy techniques provided similar results in terms of diagnosis, we believe that needle biopsy is more practical, and yields deeper hepatic tissue sampling with less tissue removal. These characteristics have made needle biopsy the standard procedure on our service.

References

1. Gayotto LCC. Biópsia hepática. In: Gayotto LCC. Doenças do fígado e vias biliares. São Paulo: Atheneu 2001: 151-63.
2. Klatskin G, Conn HO. Histopathology of the Liver. New York: Oxford University Press 1993: 3-8.
3. Joy D, Thava VR, Scott BB. Diagnosis of fatty liver disease: is biopsy necessary? *Eur J Gastroenterol Hepatol* 2003; 15: 539-43.
4. Mottin CC, Moretto M, Padoin AV et al. The role of ultrasound in the diagnosis of hepatic steatosis in morbidly obese patients. *Obes Surg* 2004; 14: 635-7.
5. Saadeh S, Younossi ZM, Remer EM et al. The utility of radiological imaging in nonalcoholic fatty liver disease. *Gastroenterology* 2002; 123: 745-50.
6. Charlton M. Nonalcoholic fatty liver disease: a review of current understanding and future impact. *Clin Gastroenterol Hepatol* 2004; 2: 1048-58.
7. Bravo AA, Sheth SG, Chopra S. Liver biopsy. *N Engl J Med* 2001; 344: 495-500.
8. Del Gaudio A, Boschi L, Del Gaudio GA et al. Liver damage in obese patients. *Obes Surg* 2002; 12: 802-4.
9. Spaulding L, Trainer T, Janiec D. Prevalence of non-alcoholic steatohepatitis in morbidly obese subjects undergoing gastric bypass. *Obes Surg* 2003; 13: 347-9.
10. Gholam PM, Kotler DP, Flancbaum LJ. Liver pathology in morbidly obese patients undergoing Roux-en-Y gastric bypass surgery. *Obes Surg* 2002; 12: 49-51.
11. Matteoni CA, Younossi ZM, Gramlich T et al. Nonalcoholic fatty liver disease: a spectrum of clinical and pathological severity. *Gastroenterology* 1999; 116: 1413-9.
12. Moretto M, Kupski C, Mottin CC et al. Hepatic steatosis in patients undergoing bariatric surgery and its relationship to body mass index and co-morbidities. *Obes Surg* 2003; 13: 622-4.
13. Crespo J, Fernandez-Gil P, Hernandez-Guerra M et al. Are there predictive factors of severe liver fibrosis in morbidly obese patients with non-alcoholic steatohepatitis? *Obes Surg* 2001; 11: 254-7.
14. Pereira Lima ML, Mourao SC, Diniz MT et al. Hepatic histopathology of patients with morbid obesity submitted to gastric bypass. *Obes Surg* 2005; 15: 661-9.
15. Mottin CC, Moretto M, Padoin AV et al. Histological behavior of hepatic steatosis in morbidly obese patients after weight loss induced by bariatric surgery. *Obes Surg* 2005; 15: 788-93.
16. Shalhub S, Parsee A, Gallagher SF et al. The importance of routine liver biopsy in diagnosing nonalcoholic steatohepatitis in bariatric patients. *Obes Surg* 2004; 14: 54-9.
17. Wolf AM, Busch B, Kuhlmann HW et al. Histological changes in the liver of morbidly obese patients: correlation with metabolic parameters. *Obes Surg* 2005; 15: 228-37.
18. Dixon JB, Bhathal PS, O'Brien PE. Nonalcoholic fatty liver disease: predictors of nonalcoholic steatohepatitis and liver fibrosis in the severely obese. *Gastroenterology* 2001; 121: 91-100.
19. Janiec DJ, Jacobson ER, Freeth A et al. Histologic variation of grade and stage of non-alcoholic fatty liver disease in liver biopsies. *Obes Surg* 2005; 15: 497-501.
20. Burt AD, Mutton A, Day CP. Diagnosis and interpretation of steatosis and steatohepatitis. *Semin Diagn Pathol* 1998; 15: 246-58.
21. Franzen LE, Ekstedt M, Kechagias S et al. Semi quantitative evaluation overestimates the degree of steatosis in liver biopsies: a comparison to stereological point counting. *Mod Pathol* 2005; 18: 912-6.
22. Hui AY, Liew CT, Go MY et al. Quantitative assessment of fibrosis in liver biopsies from patients with chronic hepatitis B. *Liver Int* 2004; 24: 611-8.

(Received September 25, 2005; accepted November 3, 2005)