

## Improving the Interpretation of Ictal Scalp EEG: BSS–CCA Algorithm for Muscle Artifact Removal

\*Anneleen Vergult, \*Wim De Clercq, †André Palmi, \*Bart Vanrumste, ‡Patrick Dupont, \*Sabine Van Huffel, and †Wim Van Paesschen

\*ESAT-SCD Electrical Engineering Department, Katholieke Universiteit Leuven; †Neurology Department, University Hospital Leuven, Katholieke Universiteit Leuven; and ‡Nuclear Medicine, University Hospital Leuven and Medical Imaging Center, Katholieke Universiteit Leuven, Leuven, Belgium.

**Summary:** *Purpose:* To investigate the potential clinical relevance of a new algorithm to remove muscle artifacts in ictal scalp EEG.

*Methods:* Thirty-seven patients with refractory partial epilepsy with a well-defined seizure onset zone based on full presurgical evaluation, including SISCOB but excluding ictal EEG findings, were included. One ictal EEG of each patient was presented to a clinical neurophysiologist who was blinded to all other data. Ictal EEGs were first rated after band-pass filtering, then after elimination of muscle artifacts using a blind source separation–canonical correlation analysis technique (BSS–CCA). Degree of muscle artifact contamination, lateralization, localization, time and pattern of ictal EEG onset were compared between the two readings and validated against the other localizing information.

*Results:* Muscle artifacts contaminated 97% of ictal EEGs, and interfered with the interpretation in 76%, more often in extratemporal than temporal lobe seizures. BSS–CCA significantly improved the sensitivity to localize the seizure onset from 62% to 81%, and performed best in ictal EEGs with moderate to severe muscle artifact contamination. In a significant number of the contaminated EEGs, BSS–CCA also led to an earlier identification of ictal EEG changes, and recognition of ictal EEG patterns that were hidden by muscle artifact.

*Conclusions:* Muscle artifacts interfered with the interpretation in a majority of ictal EEGs. BSS–CCA reliably removed these muscle artifacts in a user-friendly manner. BSS–CCA may have an important place in the interpretation of ictal EEGs during presurgical evaluation of patients with refractory partial epilepsy. **Key Words:** Epilepsy—Muscle artifact—Ictal EEG—Blind source separation—Canonical correlation analysis.

The electroencephalogram (EEG) is frequently contaminated by electrophysiological potentials generated by muscle activity, and these electromyogram (EMG) artifacts often interfere with the interpretation of the EEG (Lopes da Silva, 2005). Ictal EMG artifact on EEG due to movement during a seizure may be problematic in the setting of the preoperative evaluation of patients with refractory seizures, since ictal recordings are crucial for the localization of the seizure onset zone. Ictal scalp EEG recordings that provide clear localizing information streamline the presurgical evaluation, often obviating the need for intracranial EEG.

Ictal EEG recordings give localizing information in around 50–70% of cases, more often in temporal than extratemporal lobe epilepsy (Spencer et al., 1985; Walczak et al., 1992; Foldvary et al., 2001). Although muscle arti-

fact often interferes with the correct interpretation of ictal EEG (Spencer et al., 1985), this issue has never been formally addressed in any study of ictal EEG interpretation. In the study of Foldvary et al. (2001) 11% of ictal EEGs were entirely obscured by artifacts. In a study of frontal lobe complex partial seizures, Williamson et al. (1985) reported that 70% of ictal EEGs had no appreciable scalp EEG change other than artifact.

In clinical practice, muscle artifacts are suppressed by digital low-pass filters. However, these filters suppress all high-frequency activity, including electrical brain activity relevant to the localization of seizure onset, such as ictal beta activity. Moreover, muscle artifacts filtered by a low pass filter can resemble cerebral activity (Klass, 1995), or epileptic spikes (Barlow, 1986), potentially leading to an incorrect interpretation of the filtered EEG.

More recently, independent component analysis (ICA) has been evaluated for artifact removal (Nam et al., 2002; Urrestarazu, 2004; LeVan, 2006). ICA separates the EEG into statistically independent sources that generate the measured multichannel EEG. This technique performs

Accepted December 8, 2006.

Address correspondence and reprint requests to Anneleen Vergult, Katholieke Universiteit Leuven (ESAT-SCD), Kasteelpark Arenberg 10, B-3001 Leuven, Belgium. E-mail: anneleen.vergult@gmail.com  
doi: 10.1111/j.1528-1167.2007.01031.x

adequately for the removal of eye movement artifacts, but cross-talk was observed when the separation of brain and muscle activity was attempted. Therefore, ICA not only eliminates EMG artifacts but at the same time suppresses genuine brain activity. Thus, or too little EMG artifact is removed or genuine brain activity is suppressed. Moreover, the identification of the sources containing artifacts in general and muscle activity in particular is not obvious. The automatic artifact removal method based on ICA (LeVan, 2006) showed a good identification of eye artifacts, but less good of EMG artifacts.

We have developed a new method for muscle artifact elimination in scalp EEG to circumvent the disadvantages of ICA (De Clercq et al., 2006). This technique is based on the statistical Canonical correlation analysis (CCA) method applied as a blind source separation (BSS) technique, further referred to as BSS-CCA. Using simulation experiments, we have shown that BSS-CCA outperforms ICA and low-pass filters in removing EEG muscle artifacts with no or minimal modification of the underlying brain activity (De Clercq et al., 2006). Moreover, a user-friendly implementation of the BSS-CCA method is now available, which makes the technique applicable in clinical practice.

The aim of this study was to compare the clinical performance of the BSS-CCA muscle artifact removal method with the commonly used low-pass filters in ictal scalp EEG recordings. We hypothesized that this method would improve the ability to localize the site of ictal onset with more precision and at an earlier time than when reading the same recordings filtered by the routinely used low-pass filter.

## METHODS

### Patients

Patients were included after a presurgical evaluation of refractory partial epilepsy when seizure semiology, structural MRI, interictal EEG, subtraction of ictal SPECT coregistered with MRI (SISCOM) and neuropsychological assessment were all concordant, and for our study purposes reliably defined the epileptogenic zone. Ictal EEG findings were not an inclusion criterion. Thirty-seven patients fulfilled the inclusion criteria. Twenty-four were women. Median age was 33 years (range: 14–62). Median age at seizure onset was 14 years (0–62). The median seizure frequency per month was 6 (1–600). MRI showed unilateral hippocampal sclerosis ( $n = 10$ ), focal cortical dysplasia ( $n = 5$ ), scar tissue ( $n = 5$ ), a tumor ( $n = 3$ ), dual pathology ( $n = 2$ ), a cavernous angioma ( $n = 1$ ), or no abnormality ( $n = 10$ ). Seventeen patients underwent an operation. With a follow-up of more than 2 years, 12 have remained seizure-free, and 5 almost seizure-free. Five patients refused surgery, and 15 were not offered surgery, because the epileptogenic zone involved eloquent cortex ( $n = 6$ ) or the MRI did not reveal an abnormality ( $n = 9$ ).

### EEG acquisition

Video-EEGs were recorded on 21-channel OSG EEG recorders (Rumst, Belgium). Electrodes were placed according to the International 10–20 System (Nuwer et al., 1998) with additional sphenoidal electrodes. Sampling frequency was 250 Hz and an average reference montage was used. The EEG was digitally filtered by a band-pass filter (0.3–35 Hz). A notch filter was applied to suppress the 50 Hz power-line interference.

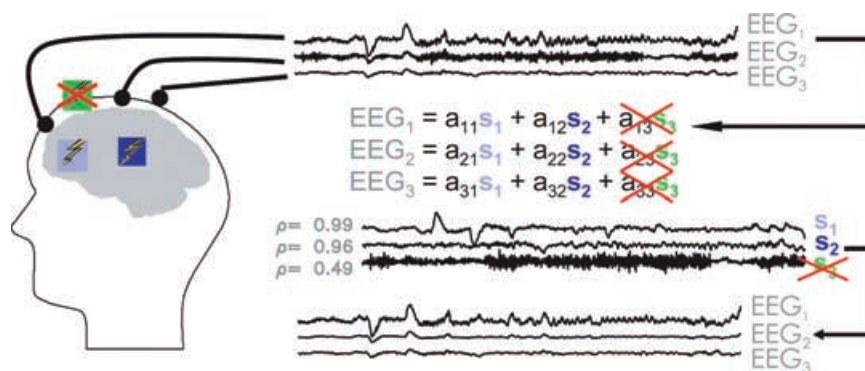
### Sample selection

Ictal EEG recordings for this study were selected by the epileptologist (WVP) who was aware of all the data of the presurgical evaluation. The selected EEGs started 30–40 s before clinical seizure onset or ictal EEG onset, whichever was first. The selected EEGs were around 60 s in duration and contained around 30 s of ictal EEG activity, when visible on the band-pass-filtered EEG. The selected EEG was of the seizure during which the ictal SPECT injection was given. One ictal EEG per patient was used in this study. The ictal SPECT injection was given during a complex partial seizure ( $n = 32$ ), simple partial seizure ( $n = 2$ ), or secondarily generalized seizure ( $n = 3$ ). The median duration of the injected seizure was 70 s (range: 11–389) and the median time of injection was 26 s after seizure onset (range: 3–109).

The ictal EEGs were presented to a clinical neurophysiologist and epileptologist (AP) who was blinded to all other clinical and localizing data. The same EEG portion was read twice, sequentially, initially only with the help of the band-pass filter, and later after full removal of muscle artifacts using the new BSS-CCA muscle artifact removal technique. To quantify improvements in the interpretation accuracy, the assigned lateralizations, localizations, and time of seizure onset were compared between the two readings, and also with the other localizing data. These procedures are detailed below.

### Muscle artifact removal by BSS-CCA

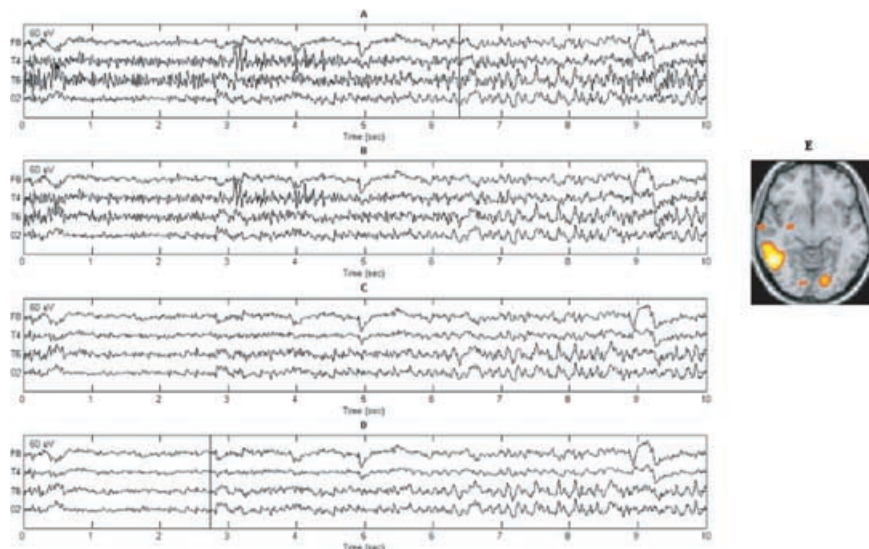
Muscle artifacts were semi-automatically removed from the presented EEG portions with the technique described in the paper of De Clercq et al. (2006). This technique, as principal component analysis (PCA) and ICA, estimates the underlying sources  $S$ , which generate the multichannel EEG and estimates the attenuation of each source to each electrode. These estimations are made, while knowing very little of how these sources propagate to the electrodes and making little assumptions on these source signals. This is schematically illustrated in Fig. 1. The assumptions of BSS-CCA are ideal for separation of muscle artifacts from other EEG activity. The technique assumes that the sources that are responsible for the EEG signals are not correlated with each other and have different autocorrelation structures. The most random sources, such as muscle artifacts, have the lowest autocorrelation coefficient. The method orders the estimated sources



**FIG. 1.** The BSS-CCA technique as a tool to remove muscle artifact from EEG. For simplification, assume two main sources in the brain (blue) and one muscular source (green) generating electrical activity measured by three scalp EEG electrodes (black). Each EEG electrode measures a combination of the activity of the three sources  $S_1$ ,  $S_2$ , and  $S_3$ . The attenuation of the sources, due to propagation through different media (brain, skull, scalp) and the distance of propagation, is presented by the attenuation factors  $a_{ij}$ , with  $i$  the number of electrode, and  $j$  the number of source. The BSS-CCA technique estimates these sources (shown) and attenuation factors (not shown), giving the muscular sources the highest source numbers, corresponding with the lowest autocorrelation coefficient (here 0.49). By removing the contribution of the muscular sources (here only  $S_3$ ) to the electrodes, the muscle artifact free EEG can be reconstructed as shown in the lower part of the figure.

automatically by a decreasing autocorrelation coefficient. Muscle artifacts, therefore, appear always in the lowest sources. Furthermore, these muscle artifact sources are well separated from the more highly autocorrelated genuine brain activity sources. In a 21-channel EEG recording, 21 sources were identified. In our algorithm, it is possible to remove selected sources, and hence the contribution from these sources to the EEG signal. By gradually removing the sources with the lowest autocorrelation coefficient, we have shown, using simulation experiments, that muscle artifact progressively disappears without any modifications of the genuine EEG signals (De Clercq et al., 2006). Since the number of sources containing muscle artifact may vary, depending on the severity of muscle artifact contamination, the neurophysiologist has to decide how many sources have to be removed in order to

remove all muscle artifacts, judging from the visual interpretation of the resulting EEG signals. Removal of higher sources containing genuine cerebral activity will lead to removal of cerebral EEG signals. The technique is, therefore, user-dependent and semi-automatic. Removal of all sources leads to loss of all EEG signals, that is, a completely flat EEG. This process has to be repeated for every 10-s epoch of each EEG segment, and takes around 1–2 min for every 10-s epoch (see below). Fig. 2 illustrates a progressive removal of muscle artifacts from a 10-s EEG epoch (see supplemental material for a full demonstration). Mathematical details can be found in the paper of De Clercq et al. (2006). It should be noted that it was not our intention to estimate real muscle artifact and genuine brain activity sources, but only a good separation between them. Although muscle artifacts from different positions



**FIG. 2.** Ten seconds ictal EEG tracing of a patient with a small focal cortical dysplasia in the right posterior area. Channels F8, T4, T6, and O2 are shown. **(A)** Band-pass (0.3–35Hz) and notch-filtered ictal EEG was contaminated with muscle artifacts and revealed ictal activity from 6.4 s onwards (vertical line). **(B,C)** By excluding progressively more sources using BSS-CCA muscle artifacts gradually disappeared. **(D)** After removal of all muscle artifacts, using BSS-CCA, low voltage fast ictal beta activity was revealed more than 3 s earlier (vertical line) than the band-pass-filtered EEG **(A)** at T6 and O2. BSS-CCA allowed a confident localization of the seizure onset zone in the right occipital–posterior temporal region, which was confirmed by subtraction ictal SPECT visualized on a template MRI **(E)**.

may well be correlated with each other during short time windows, this is not a problem for our BSS–CCA method, as long as no correlation exists between muscle artifact sources and genuine brain activity. The BSS–CCA method is available for academic use at <http://www.neurology-kuleuven.be/?id=210>.

### Performance measures

Comparison between accuracy of ictal EEG readings using the band-pass–filtered ictal EEG and the BSS–CCA processed EEG proceeded in a stepwise fashion. The EEGs were presented to the clinical neurophysiologist on a computer screen in 10-s epochs. The EEG signal could be moved in 5- or 10-s steps to fine-tune the readings. A fixed average referenced montage was used.

Step 1: The neurophysiologist interpreted the ictal EEG using the routine approach. The band pass filter parameters were set at 0.3 Hz–35 Hz. These, as well as the standard applied notch filter and the amplitude scale, could be freely modified. If a seizure onset was identified, the following features were specified or scored: (i) degree of muscle artifact contamination in the EEG sample, in a qualitative fashion; (ii) lateralization of seizure onset; (iii) localization of seizure onset; (iv) time of onset of the seizure; and (v) frequency band of the rhythmical pattern that characterized the onset. The possible categories pertinent to each feature are provided in Table 1. After determining or scoring these features, the reviewer proceeded to Step 2. If a seizure was not identified, the features were not determined and the reviewer proceeded immediately to Step 2.

Step 2: The neurophysiologist interpreted the ictal EEG after applying the BSS–CCA algorithm to remove muscle artifacts, as in Step 1. At this stage, the amplitude scale could still be changed and the reviewer could compare the cleaned EEG with the band-pass–filtered EEG epochs and their previous interpretation, which was displayed on a second screen, although the latter could not be modified.

**TABLE 1.** Possible categories of the investigated features

Amount of muscle artifact contamination	Lateralization	Localization	Pattern
Not present	Impossible	Impossible	Impossible
Mild, no interference with interpretation	Bilateral onset	F,T,C,P,O <sup>a</sup>	Delta
Moderate, some interference with interpretation	Left		Theta
Severe, interpretation difficult	Right		Alfa Beta Rhythmic spikes

F, frontal; T, temporal; C, central; P, parietal; O, occipital.

<sup>a</sup>All possible combinations were allowed.

Step 3: The reviewer was asked whether BSS–CCA (i) made interpretation of ictal EEG easier, (ii) allowed the identification of “hidden” ictal patterns, (iii) suppressed not only muscle artifacts but also cerebral EEG signals.

Step 4: Finally, the reviewer had to comment on why the interpretation was changed (or not), to monitor the consistency with the assigned feature values.

The interpretations with the routine band-pass filter and using the BSS–CCA algorithm were compared and validated against the other localizing information. Lateralizations and localizations obtained with the two artifact removal techniques were compared and verified in relation to the corresponding SISCOM and other data. Time of ictal EEG seizure onsets of the two techniques was compared with the clinical onset time, which was determined on video recordings of the seizures.

Improvements in the interpretation of ictal EEGs were quantified and one point was assigned when BSS–CCA was better than band-pass filtering for each of the following six parameters: (i) correct lateralization of the ictal onset zone, (ii) improved localization of the ictal onset zone, (iii) time of EEG ictal seizure onset was rated as more than 3 s earlier, (iv) identification of seizure onset frequency pattern, (v) faster seizure onset frequency pattern, (vi) appearance of a previously hidden ictal pattern. Results were presented in terms of the number of patients in whom the above statements were true, and also in an overall quantified fashion.

A more subjective feature “easiness of interpretation” was assessed in terms of the number of patients in whom BSS–CCA was considered to facilitate the interpretation.

### Statistical analysis

Differences in degree of muscle artifact contamination, and accuracy of localization and lateralization between temporal and extratemporal lobe seizures were assessed with the nonparametric Wilcoxon or Mann–Whitney test. Accuracies of lateralization, localization, and interval between clinical and EEG onset time were compared between band-pass– and BSS–CCA–filtered EEGs using Wilcoxon’s signed ranks. A p-value of <0.05 was considered a statistically significant difference.

## RESULTS

Muscle artifacts were present in 36 of 37 band-pass–filtered ictal EEGs (97%) and interfered with the interpretation in 28 (76%) (Table 2). Ictal EEGs were of temporal lobe seizures in 27 and of extratemporal lobes seizures in 10. Moderate to severe muscle artifacts were present in all 10 extratemporal lobe seizures (100%) in comparison with 18 of 27 temporal lobe seizures (67%) (p = 0.007).

In three patients the reviewer was not able to identify a seizure onset on the band-pass–filtered EEG. In one of these, a seizure onset could be correctly determined in time

**TABLE 2.** Quantification of the degree of muscle artifact contamination of ictal EEGs, n (%)

Degree of muscle artifact contamination	Total n = 37	Temporal lobe	Extratemporal
		seizures n = 27	lobe seizures n = 10
Not present	1 (3)	1 (4)	0 (0)
Mild, no interference with interpretation	8 (21)	8 (30)	0 (0)
Moderate, some interference with interpretation	17 (46)	13 (48)	4 (40)
Severe, interpretation difficult	11 (30)	5 (18)	6 (60)

and space after applying BSS-CCA. In addition, in all 3 cases an easier interpretation was reported after applying BSS-CCA, in that a recruiting rhythmic activity could be reliably ruled out.

The remaining 34 band-pass-filtered ictal EEGs, which displayed ictal activity, were further analyzed. Application of the BSS-CCA algorithm did not change the interpretation of EEGs with no or minimal muscle artifacts, but had an important impact on the interpretation of ictal EEGs with moderate to severe muscle artifact (Table 3, Figs. 3 and 4). Significant improvements were observed for localization of ictal EEG onset, earlier identification of ictal EEG changes, and recognition of ictal EEG patterns that were hidden by muscle artifact. There was a trend for improved lateralization of ictal EEG onset and recognition of faster onset patterns. On average 1 or 2 of 6 features improved in 25 ictal EEGs with moderate to severe muscle artifact contamination. In the group of severely contaminated EEGs, improvements in three of six features were observed.

Correct lateralization and localization of band-pass-filtered ictal EEGs were significantly higher in temporal lobe compared with extratemporal lobe seizures. Improvements in both lateralization and localization after application of BSS-CCA were seen more often in extratemporal lobe (33% and 44%, respectively) than temporal lobe seizures (8% and 12% respectively) (Table 4).

The median interval between clinical seizure onset and the first unequivocal evidence of seizure onset in band-pass-filtered EEG was 4 s, and after BSS-CCA 2 s. In the 25 EEGs with moderate to severe muscle artifacts, this interval was reduced from 5 to 3 s ( $p = 0.05$ ).

In five EEGs a faster and in seven a slower ictal onset pattern was indicated when applying BSS-CCA. This was often due to a pattern frequency lying on the border of two frequency ranges from which one had to choose, and was felt to be of little clinical significance. More important, in two cases, an ictal beta activity was identified that was hidden by muscle artifact, and in two cases, muscle artifact was misinterpreted as ictal beta activity before muscle artifact removal by BSS-CCA. By applying BSS-CCA the ictal pattern could be identified more correctly.

The reviewer felt it was "easier" to interpret 23 of all 37 ictal EEGs (62%). This percentage increased to 76% if only the 25 ictal EEG with moderate to severe muscle artifacts are considered.

Application of the BSS-CCA algorithm was not useful in 11 of 25 EEGs with moderate to severe muscle artifact contamination (44%). BSS-CCA did not change interpretation in eight EEGs. In several of these cases, we noticed that muscle artifacts were not always optimally removed when superimposed on slow artifacts, such as eye movements. BSS-CCA led to incorrect lateralization in three cases. In one of these mislateralization was due to excessive signal removal, leading to the suppression of genuine cerebral activity; in another due to incomplete removal of muscle artifact, which was interpreted as cerebral activity. In the third case of mislateralization, muscle artifact revealed a rhythmic low voltage pattern of unclear significance in the contralateral temporal lobe.

## DISCUSSION

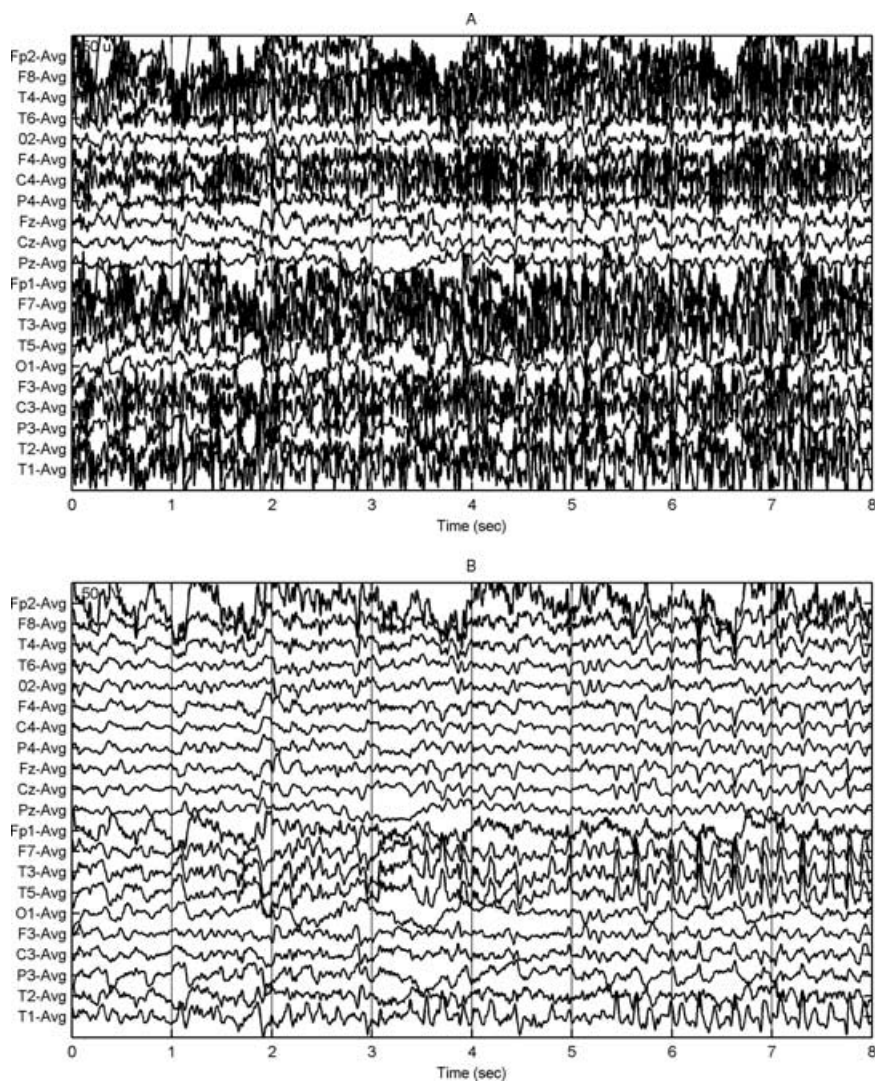
Scalp EEG is the most commonly used technique to determine the seizure onset zone during presurgical evaluation of refractory partial epilepsy (Rosenow and Lüders,

**TABLE 3.** Improvement in ictal scalp EEG interpretation by applying BSS-CCA, according to the degree of muscle artifact contamination in the routinely band-pass filtered signals<sup>a</sup>

Feature	Degree of muscle artifact contamination		p-value <sup>b</sup>
	No or minimal muscle artifacts n = 9	Moderate to severe muscle artifacts n = 25	
Improved lateralization	–	5 (20%)	0.06
Improved localization	–	7 (28%)	0.02
Onset > 3 sec earlier	–	6 (24%)	0.03
Improved pattern identification	–	3 (12%)	0.25
Faster onset pattern	–	5 (20%)	0.06
Appearance hidden patterns	–	10 (40%)	<0.01

<sup>a</sup>Three patients with no identifiable ictal EEG activity on band-pass-filtered EEG were excluded from this analysis.

<sup>b</sup>Band-pass vs. BSS-CCA-filtered EEGs moderately to severely contaminated with muscle artifacts.



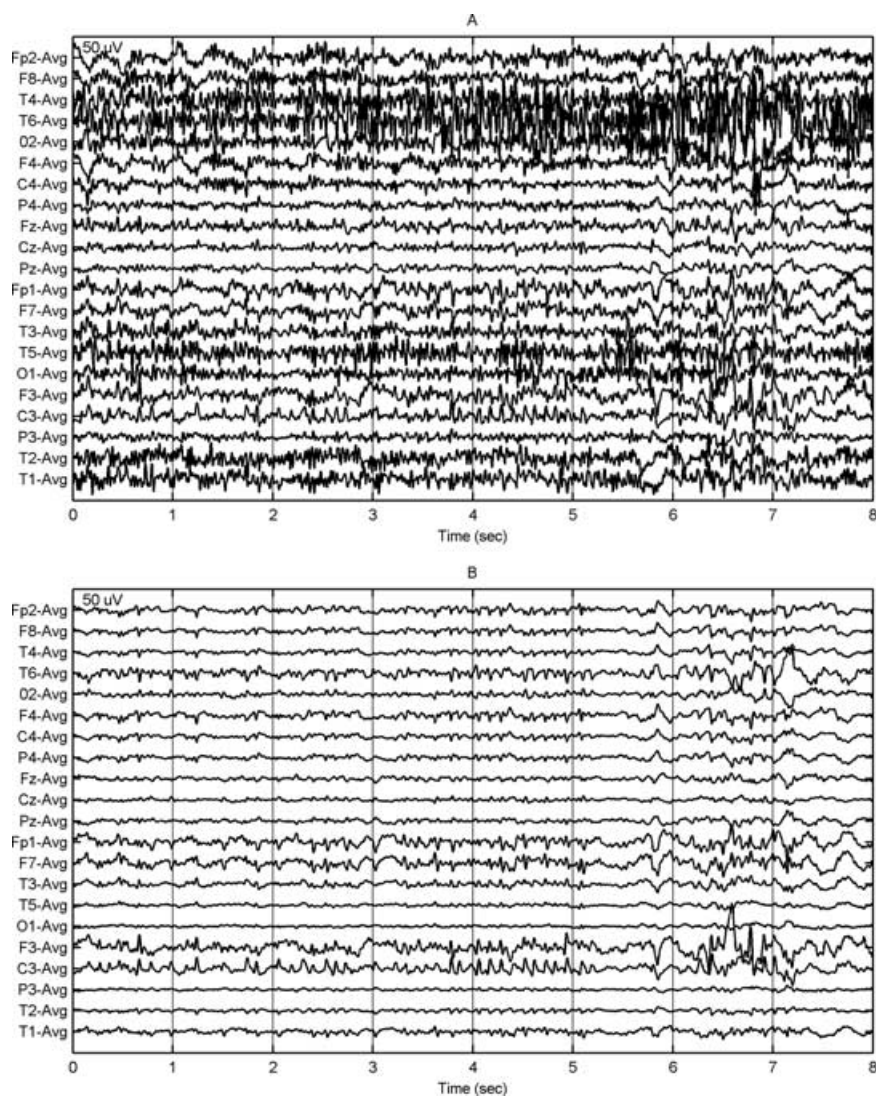
**FIG. 3.** Muscle artifact removal in a temporal lobe seizure. Patient was a 35-year-old woman with refractory left mesial temporal lobe epilepsy with hippocampal sclerosis. The first 8 s of the ictal EEG of a complex partial seizure were severely contaminated with muscle artifacts, making interpretation of the ictal EEG impossible (**A**). After muscle artifact removal using BSS-CCA (**B**), a recruiting theta rhythm was clearly visible in the left temporal derivations (F7-Avg, T3-Avg, T5-Avg, and T1-Avg (sphenoidal electrode)).

2001). Excessive muscle artifacts in a majority of ictal EEGs is one of the factors that make this technique relatively insensitive for the detection of the seizure onset zone. Muscle artifacts were present in 97% of ictal EEGs, and interfered with the interpretation in 76% in our study. Moderate to severe muscle artifacts, interfering with the interpretation of the ictal EEG were more frequent in extratemporal lobe than temporal lobe seizures, confirming previous reports (Foldvary et al., 2001). Sensitivity for the detection of the seizure onset zone on ictal EEG after band-pass filtering in our study was around 62%, which is consistent with reported sensitivities of 50–70%. BSS-CCA significantly improved the sensitivity for the detection of the seizure onset zone in ictal EEGs to around 81%. BSS-CCA also allowed earlier detection of the ictal activity and identification of ictal patterns hidden by muscle artifacts. Ictal beta activity is a common pattern in seizures of neocortical onset, and has been reported in around 25% of frontal lobe seizures (Worrell et al., 2002). Recognition of ictal beta is important, because it carries a good

prognosis with respect to seizure outcome after epilepsy surgery. Ictal beta, however, is readily obscured by muscle artifact. BSS-CCA improved the reliable identification of ictal beta by removing muscle artifacts that masked the pattern or that were misinterpreted as ictal beta.

In 63% of ictal EEGs which were severely contaminated with muscle artifacts, superior localization and lateralization were observed. The largest improvements were seen in EEGs of extratemporal seizures, since these were most often contaminated with muscle artifacts. Generally, it is believed that ictal EEGs have more localizing value in temporal than extratemporal seizures (Foldvary et al., 2001). However, our results suggest that EEGs in extratemporal lobe seizures contain valuable information, which is often hidden by muscle artifacts. By eliminating the muscle artifact contamination using BSS-CCA, hidden ictal activity may appear leading to a correct lateralization and localization.

Our methodology had several shortcomings. As gold standard for localization, we used all information of the



**FIG. 4.** Muscle artifact removal in an extratemporal lobe seizure. Patient was a 38-year-old woman with refractory late posttraumatic epilepsy. MRI of the brain showed a large contusion affecting the left frontal, temporal and parietal lobes, and left hippocampal sclerosis. She was admitted to determine whether the seizures started in the temporal lobe or extratemporal regions. The first 16 s of the ictal EEG (**A** and **C**) were severely contaminated with muscle artifacts and, therefore, difficult to interpret. Ictal SPECT during a partial seizure with injection 3 s after seizure onset showed hyperperfusion in the left frontal and temporal lobes. After muscle artifact removal using BSS-CCA, it became clear that the seizure started in the left frontocentral regions (**B**: channels F3-Avg, C3-Avg, and to a lesser extent Fp1-Avg and F7-Avg) with propagation toward the left temporal lobe (**D**: channel T3-Avg).

presurgical evaluation (except for ictal EEG), including SISCOM. We did not use seizure freedom after surgery, since not all patients underwent surgery. Selection of patients who were rendered seizure-free after surgery, would have made our sample size rather small. We have used SISCOM as a gold standard for the ictal onset zone. It is well known that the time resolution of ictal SPECT is poor, and that areas of hyperperfusion often represent a combination of ictal onset zone and propagated activity, even when ictal SPECT injections were given early during a seizure. Since the aim of the present study was to compare the sensitivity of two methods of analysis of the same EEG data set (visual analysis of band-pass-filtered EEG vs. EEG after application of BSS-CCA) to detect the ictal onset zone, we believe that our current inclusion criteria were sufficient to reliably indicate the lobe of seizure onset. Some of the features in our study did not have an independent gold standard, such as ictal onset pattern. Interpretation of EEG is known to vary between observers. In our

study, we only had one blinded observer, and results might have been different if we had used more blinded observers. This subjective aspect of EEG interpretation is reflected in some arbitrary definitions of improvements in our study, such as “easiness of interpretation,” which should be interpreted with caution. To ensure improvements were due to BSS-CCA, our methodology deviated at certain points from a real clinical situation. The reviewer had no information about seizure or patient except for the presented EEG. Moreover, the average referenced montage and window length were fixed. This made the interpretation in some cases more difficult compared with real clinical practice, especially for lateralization due to the fixed montage. On the other hand, to approach real clinical ictal EEG interpretation, we choose not to present only a 10-s ictal EEG including seizure onset, as in other studies (Urrestarazu et al., 2004), but an EEG of minimal 70 s duration. Despite these methodological shortcomings, we believe that our methodology reflected routine clinical practice as

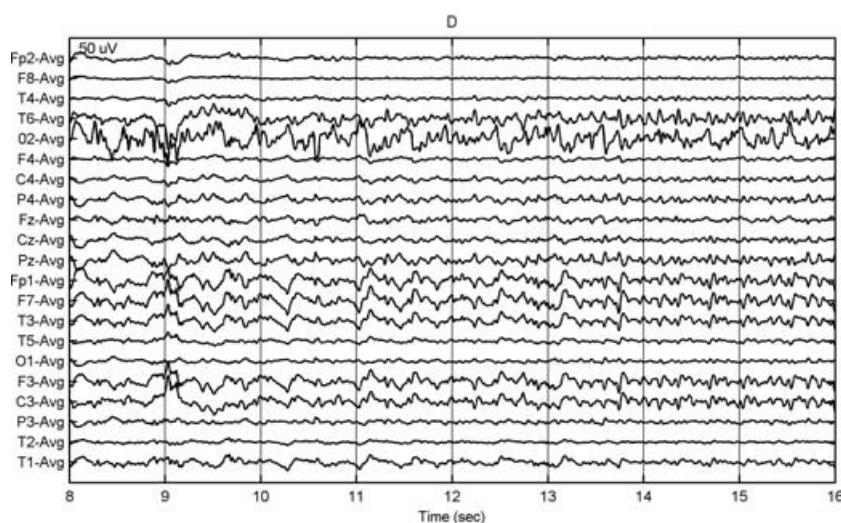
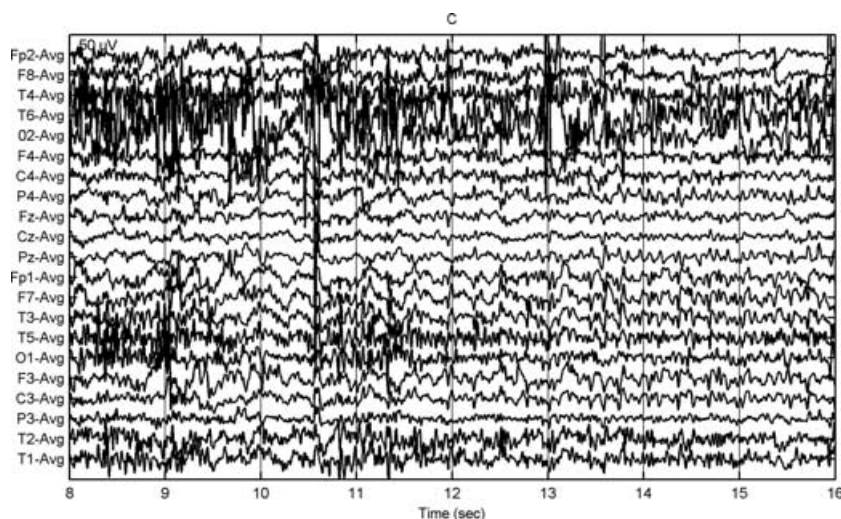


FIG. 4. Continued.

closely as possible, and that our positive results should be readily apparent to the clinician using the BSS-CCA algorithm.

The BSS-CCA method is currently implemented as a semi-automated tool. The EEG reader has to remove all

sources containing muscle artifact without removing cerebral activity in every 10-s EEG epoch, which could take from 30 to 60 s. Insufficient removal of muscle artifact and removal of cerebral activity led to mislateralizations in two of our patients. BSS-CCA may not remove muscle artifacts optimally, when these are superimposed on other slow artifacts, such as eye movement and blinking, which could be removed with other techniques, such as ICA (Urrestarazu et al., 2004). We believe that the method is best suited for the interpretation of ictal EEGs contaminated with muscle artifact. The use of the BSS-CCA method can be limited to the epochs in the neighborhood of the clinical seizure or ictal EEG, when muscle artifacts are present. This will reduce the extra time required for applying the BSS-CCA muscle artifact removal algorithm, which makes the use of the technique attractive in clinical practice. BSS-CCA could also be applied in magneto-encephalography and could potentially improve dipole localization. BSS-CCA may have an immediate clinical impact on the presurgical evaluation of patients with refractory partial epilepsy, and may obviate the need

**TABLE 4.** Improvements in localization and lateralization of ictal EEGs after applying BSS-CCA in temporal versus extratemporal lobe seizures, n (%)<sup>a</sup>

	Temporal n = 25	Extratemporal n = 9	p-value
Correct lateralization			
Band-pass filtering	18 (72)	3 (33)	0.05
BSS-CCA	20 (80)	6 (67)	0.44
Improvement	2 (8)	3 (33)	0.07
Correct localization			
Band-pass filtering	22 (88)	1 (11)	<0.01
BSS-CCA	24 (96)	5 (56)	<0.01
Improvement	3 (12)	4 (44)	0.04

<sup>a</sup>Three patients with no identifiable ictal EEG activity on band-pass-filtered EEG were excluded from this analysis.



for invasive EEG monitoring when the seizure onset zone can be reliably identified on ictal scalp EEG.

**Acknowledgments:** Research was supported by Research Council KUL: GOA-AMBioRICS, CoE EF/05/006 Optimization in Engineering, several PhD/postdoc & fellow grants; Flemish Government: FWO: PhD/postdoc grants, projects, G.0407.02 (support vector machines), G.0360.05 (EEG, Epileptic), G.0519.06 (Noninvasive brain oxygenation), FWO-G.0321.06 (Tensors/Spectral Analysis), research communities (ICCoS, ANMMM); IWT: PhD Grants; Belgian Federal Science Policy Office IUAP P5/22 (Dynamical Systems and Control: Computation, Identification and Modelling); EU: BIOPATTERN (FP6-2002-IST 508803), ETUMOUR (FP6-2002-LIFESCIHEALTH 503094), Healthagents (IST-2004-27214).

## REFERENCES

- Barlow JS. (1986). Artifact processing (rejection and minimization) in EEG data processing. In Lopes Da Silva FH, Strom Van Leeuwen W, Rémond A (Eds) *Clinical applications of computer analysis of EEG and other neurophysiological signals. Handbook of electroencephalography and clinical neurophysiology*. Elsevier, Amsterdam, pp. 15–62.
- De Clercq W, Vergult A, Vanrumste B, Van Paesschen W, Van Huffel S. (2006) Canonical correlation analysis applied to remove muscle artifacts from the electroencephalogram. *IEEE Transactions on Biomedical Engineering* 53:2583–2587.
- Foldvary N, Klem G, Hammel J, Bingaman W, Najm I, Lüders H. (2001) The localizing value of ictal EEG in focal epilepsy. *Neurology* 57:2022–2028.
- Klass DW. (1995) The continuing challenge of artifacts in the EEG. *The American Journal of EEG Technology* 35:239–269.
- LeVan P, Urrestarazu E, Gotman J. (2006) A system for automatic artifact removal in ictal scalp EEG based on independent component analysis and Bayesian classification. *Clinical Neurophysiology* 117:912–927.
- Lopes da Silva F. (2005) In Niedermeyer E, Lopes de Silva F (Eds) *Computer-assisted EEG diagnosis: pattern recognition and brain mapping. Electroencephalography, basic principles, clinical applications, and related fields, The edition*. Lippincott Williams & Wilkins, Philadelphia, pp. 1233–1263.
- Nam H, Yim TG, Han S, Oh JB, Lee S. (2002) Independent component analysis of ictal EEG in medial temporal lobe epilepsy. *Epilepsia* 43:160–164.
- Nuwer MR, Comi G, Emmerson R, Fuglsang-Frederiksen A, Guerit JM, Hinrichs H, Ikeda A, Luccas FJ, Rappelsburger P. (1998) IFCN standards for digital recording of clinical EEG. *Electroencephalography and Clinical Neurophysiology* 106:259–261.
- Rosenow F, Lüders H. (2001) Presurgical evaluation of epilepsy. *Brain* 124:1683–1700.
- Spencer S, Williamson P, Bridgers S, Mattson R, Cicchetti D, Spencer D. (1985) Reliability and accuracy of localization by scalp ictal EEG. *Epilepsia* 30:1567–1575.
- Urrestarazu E, Iriarte J, Alegre M, Valencia M, Viteri C, Artieda J. (2004) Independent component analysis removing artifacts in ictal recordings. *Epilepsia* 45:1071–1078.
- Walczak TS, Radtke RA, Lewis DV. (1992) Accuracy and interobserver reliability of scalp ictal EEG. *Neurology* 42:2279–2285.
- Williamson PD, Spencer DD, Spencer SS, Novelly RA, Mattson RH. (1985) Complex partial seizures of frontal lobe origin. *Annals of Neurology* 18:497–504.
- Worrell GA, So EL, Kazemi J, O'Brien TJ, Mosewich RK, Cascino GD, Meyer FB, Marsh WR. (2002) Focal ictal beta discharge on scalp EEG predicts excellent outcome of frontal lobe epilepsy surgery. *Epilepsia* 43:277–282.