

## CASE REPORT

# Case report of oral mucosa garlic burn during COVID-19 pandemic outbreak and role of teledentistry to manage oral health in an older adult woman

Isis de Araújo Ferreira Muniz<sup>1</sup>  | Débora e Silva Campos<sup>1</sup>  |  
 Rosemary Sadami Arai Shinkai<sup>2</sup>  | Thiago Gomes da Trindade<sup>3</sup>  |  
 Dúcia Caldas Cosme-Trindade<sup>4</sup> 

<sup>1</sup> Department of Restorative Dentistry, Federal University of Paraíba (UFPB), João Pessoa, Paraíba, Brazil

<sup>2</sup> Department of Prosthodontics, Pontifical Catholic University of Rio Grande do Sul (PUCRS), Porto Alegre, Rio Grande do Sul, Brazil

<sup>3</sup> Department of Clinical Medicine, Federal University of Rio Grande do Norte (UFRN), Natal, Rio Grande do Norte, Brazil

<sup>4</sup> Department of Restorative Dentistry, Federal University of Paraíba (UFPB), João Pessoa, Paraíba, Brazil

## Correspondence

Dúcia Caldas Cosme-Trindade, Department of Restorative Dentistry, Federal University of Paraíba (UFPB), Campus I, Cep: 58051-900, João Pessoa, PB, Brazil.  
 Email: [duciacaldas@ccs.ufpb.br](mailto:duciacaldas@ccs.ufpb.br)

## Abstract

**Background:** The COVID-19 global pandemic and the uncertainty of an effective treatment protocol have resulted in fear and anxiety, which have increased the search for natural products to prevent the disease and to manage the symptoms.

**Aims:** To discuss the negative effects of garlic used as a preventive measure against the novel coronavirus.

**Methods and results:** This study reports a case of oral mucosa burn on the dorsal surface of the tongue in a 72-year-old woman. The patient was using raw garlic daily during the pandemic to improve her immunological system. She scheduled a dental appointment and was assessed by teledentistry due to the pandemic, in which a detailed anamnesis was carried out. The burned area and ulceration were identified by video call and photographs. The patient was instructed to cease the habit immediately and change to a soft and non-acid/spicy/hot diet, which resulted in a great recovery 2 days later. She was monitored for 2 weeks until her tongue was completely healed.

**Conclusion:** This case highlights the consequences of inappropriate use of natural product and how self-treatment could negatively influence oral health. Additionally, it shows the importance of teledentistry for oral diagnosis and treatment during a pandemic.

## KEYWORDS

COVID-19, garlic burn, oral mucosa burn, self-treatment, teledentistry

## 1 | INTRODUCTION

The COVID-19 global pandemic has led to self-treatment and inappropriate use of medicines in seeking prevention and treatment against the novel coronavirus. Therefore,

improving the immunological system (a protective factor against infectious agents) by using natural products has been suggested for preventing and managing the infection.<sup>1</sup> The anti-inflammatory, antiviral, antioxidant, immunomodulatory, and antifibrotic properties of

products such as lemon, onion, turmeric, and garlic have already been associated to health benefits and described as supporting in the prevention of several pathologies.<sup>1</sup>

Garlic (*Allium sativum*) has been widely used in alternative medicine also due to its antimicrobial, hypolipidemic, and antifungal activities, with therapeutic action for cardiovascular diseases, cancer, diabetes, and hypertension.<sup>2-5</sup> There are no studies that have evaluated garlic's effectiveness against COVID-19. However, because it contains all of these properties, it has been suggested as a preventive strategy to complications caused by coronavirus infection, preventing it from spreading throughout the body and containing its negative effects.<sup>6</sup> Despite the benefits, garlic can be associated with adverse effects and health risks if used incorrectly, such as burning on the skin and oral mucosa.<sup>4,7-10</sup> Topical use of crushed garlic to relieve dental pain has already been reported in the literature causing negative effects to the patient.<sup>4,11</sup> Some factors seem to be related to the appearance and severity of the negative effects, which highlights the importance of following the recommendations of a professional, avoiding self-treatment and adverse reactions.

This article aimed to report an unusual case of oral mucosa chemical burn on the dorsal surface of the tongue caused by the daily use of raw garlic for preventing COVID-19 and highlights the importance of teledentistry on diagnosis and management of the patient.

## 2 | CASE PRESENTATION

A 72-year-old female patient sought dental care during the COVID-19 pandemic. She was complaining of great discomfort and pain in her mouth, especially on the top of her tongue, during meals and when she performed her oral hygiene routine.

Following the Health Surveillance Agency's recommendations for procedures during COVID-19 in Brazil, it was decided to examine the patient by teledentistry, which could be an effective way to assess the patient and address the problem safely. During the remote consultation (via WhatsApp video call), the patient displayed good general health with use of some medicines (antihypertensives), which gave her confidence to resume her normal routine including social and physical activities. However, she had started to use raw garlic as a preventive measure for COVID-19 to improve her general health, as recommended by a close friend. The prescription was to chew a clove of raw garlic every day, before lunch, to improve her immunological system, and she had been following this routine for 2 months.

She initially noticed no great impairment, but the symptoms gradually increased in the week before the

teleconsultation, particularly during the last 3 days with a burning sensation and pain when she was chewing the garlic. She also noticed that the fissures she had on her tongue had increased in size.

During the teleconsultation, we asked the patient to show her tongue to the camera, take photographs and immediately send them by the app. As the patient lives alone, nobody could help her to manage the camera properly and take a high-quality clinical photo. However, we could immediately identify a whitish area on the dorsal surface of the tongue. The burned extension and ulceration were accompanied by bacterial plaque and deep fissures. The patient was concerned about the fissured aspect of her tongue, and insisted it had become deeper after taking the raw garlic dose (Figure 1A).

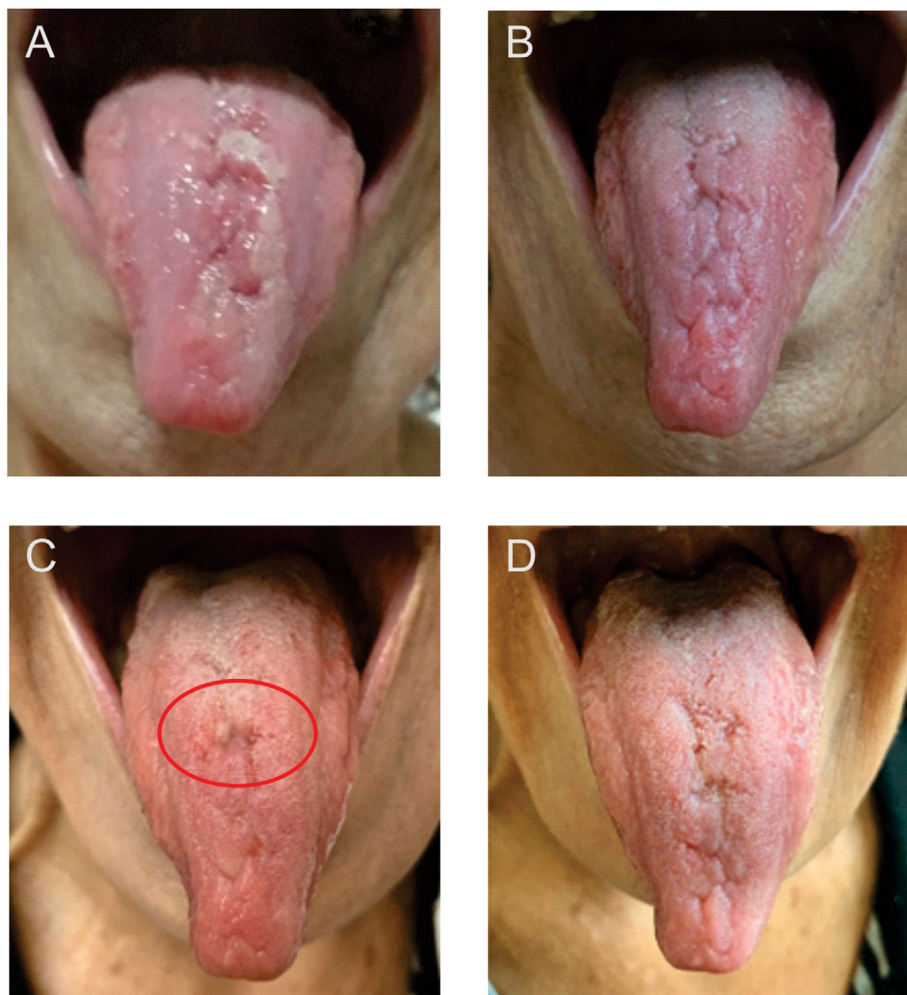
We instructed the patient to stop consuming raw garlic immediately and to try to maintain her oral hygiene habits with an appropriate tongue cleaner (Bitufo, Brazil). Additionally, we recommended she adopt an adequate soft diet with no acid, pepper, or hot food/drinks. We also advised her to use analgesics to manage discomfort and pain. The patient reported a significant reduction in the symptoms 2 days later, but we could not verify the complete healing of the mucosa at that time (Figure 1B). As a result of ceasing the habit, the burned area healed completely within 5 days and the patient stopped complaining about the pain, itching, and burning sensation.

At the follow-up appointment 1 week later, the patient reported a total absence of symptoms and assured she was only using garlic in food preparation. By analyzing the image, we could identify a better aspect of the tongue but with an inflammation area probably resulting from food lodged in the deep fissures (Figure 1C). We also educated her on adequate oral hygiene habits focusing on the dorsal surface of her tongue and recommended one further follow-up consultation.

In a new assessment 7 days later, we could verify complete healing of the mucosa, and the patient reported no more complaints regarding her tongue (Figure 1D). She was instructed to maintain her oral hygiene routine, especially for her tongue, and to avoid high consumption of acidic and spicy food/drinks. The patient was followed-up for 1 month by messages and video calls with no more symptoms.

## 3 | DISCUSSION

The use of natural products for preventing and treating systemic and oral health diseases as an integrative and complementary health practice has been widely disseminated in the literature, including in toothache relief episodes.<sup>12</sup> Garlic has been used to reduce the risk of diabetes,



**FIGURE 1** Timeline of the case report. (A) Clinical aspect of the tongue on Day 1: burned area on the dorsal surface, ulceration, and fissures increased in size. (B) Clinical aspect of the tongue on Day 3: partial healing of the mucosa after ceasing the habit. (C) Clinical aspect of the tongue on Day 7: presence of small area of inflammation. (D) Clinical aspect of the tongue on Day 14: complete healing of the dorsal surface

hypertension, atherosclerosis, hyperlipidemia, and consequently cardiovascular diseases.<sup>3</sup> However, its impact on preventing colds, cardiovascular disease, and cancer, for example, in terms of clinically relevant and patient-oriented outcomes, still needs more robust scientific evidence through clinical trials with good methodological quality.<sup>13–15</sup>

The search for natural medicine to improve immunity and to prevent the novel coronavirus has increased considerably because of fear and stress instilled in the population.<sup>16</sup> Donma and Donma (2020)<sup>6</sup> suggested the positive effect of garlic on the immunological system (by increasing of CD4<sup>+</sup> and CD8<sup>+</sup> cells and stimulation of NK cells) and on the adverse effects of COVID-19 related to reducing leptin, which promotes a reduction in appetite. Thota et al. (2020)<sup>1</sup> also suggested the effectiveness of garlic in respiratory diseases, pulmonary fibrosis, intra-alveolar edema and sepsis, all symptoms associated to coronavirus

infection. In a molecular study, garlic's antiviral effect was attributed to inhibition of ACE2 protein (receptor for the virus in the host). The compounds present in the garlic essential oil were able to inhibit this receptor, in addition to preventing the maturation and spread of the virus resulting from the attack on the viral protein PDB6LU7.<sup>5</sup> These therapeutic properties are found in essential oil and other formulations presented as capsules, tablets, and extracts in properly prescribed doses and duration by a professional.<sup>17</sup> Although some studies have suggested the hypothesis of the biological plausibility of garlic in improving immunological response, further studies are needed to prove its effectiveness in preventing COVID-19.

Unfortunately, most patients use natural products in their naturopathic form resulting from popular belief, which can reflect in adverse health effects.<sup>18</sup> Garlic's organosulfur compounds can provoke allergic reactions such as contact dermatitis, causing edema, erythema, and

hives resulting from ingestion and topical application.<sup>18</sup> Topical use of garlic in its natural form has also been related to skin and mucosa burns, depending on the presentation, contact area, and exposure duration,<sup>19</sup> as already described in the literature. Crushed and sliced raw garlic has resulted in abdominal and plantar burns, with bullous and erythematous lesions, when used to treat abdominal discomfort and a plantar wart,<sup>7</sup> to control fever episodes<sup>20</sup> and fungal nail infection.<sup>10</sup> Raw crushed and poultice garlic has been associated to skin burning when used for toothache relief<sup>11</sup> and trigeminal neuralgia treatment.<sup>9</sup> Vargo et al. (2017)<sup>4</sup> also reported a case of oral mucosa chemical burn from using raw crushed garlic to relieve dental pain. Additionally, the authors reviewed the literature on chemical burns caused by inappropriate self-treatment, its consequences, and highlighted the importance of a detailed clinical history for diagnosis. In our case report, burning on the dorsal surface of the tongue also resulted from inappropriate garlic use in its natural form, which highlights the negative effects of this product if used incorrectly.

The support and monitoring of our patient during the COVID-19 outbreak, including initial and follow-up consultations until complete resolution of the case, were made possible by using teledentistry, helping a patient who belonged to the at-risk group. Elective dental consultations were suspended during the pandemic, and only emergency care was permitted. Therefore, teledentistry has proven to be a promising tool in health care, as the patient could be rapidly evaluated by the professional immediately and in the follow-ups.<sup>21</sup> The effectiveness and good acceptance of teledentistry have already been analyzed; however, further studies focusing on the cost-effectiveness and long-term use are needed to definitively incorporate it into clinical dental practice.<sup>22</sup>

In conclusion, despite the great acceptance of the natural products in daily clinical practice due to their therapeutic use, they can negatively impact individual's health. Therefore, self-treatment must not be encouraged, as it can result in adverse effects and medicine interactions. In this case, the patient had used a natural product which, although used daily for food preparation, caused significant damage to her oral health. Thus, professionals should warn patients about the potential risks arising from inappropriate use of natural products in their fresh form, especially in this period of fear, uncertainty, and stress that the global population has been facing. The maxim "*primum non nocere*" must always be remembered by health professionals and frequently transmitted to the population.

## CONFLICT OF INTEREST

The authors declare that there is no conflict of interest.


## ETHICS STATEMENT

The patient has signed the consent form for publishing this case report. The research protocol was approved by the University Ethics Committee in compliance with federal regulations and the Declaration of Helsinki, and was registered in a national system for research in humans (CAAE - 42728321.0.0000.5188).

## ORCID

Isis de Araújo Ferreira Muniz  <https://orcid.org/0000-0002-5550-0294>

Débora e Silva Campos  <https://orcid.org/0000-0002-5579-8844>

Rosemary Sadami Arai Shinkai  <https://orcid.org/0000-0002-4107-5661>

Thiago Gomes da Trindade  <https://orcid.org/0000-0001-8178-0982>

Dúcia Caldas Cosme-Trindade  <https://orcid.org/0000-0001-9477-7037>

## REFERENCES

1. Thota SM, Balan V, Sivaramakrishnan V. Natural products as home-based prophylactic and symptom management agents in the setting of COVID-19. *Phytother Res*. 2020;34(12):3148-3167.
2. Putnik P, Gabrić D, Roohinejad S, et al. An overview of organosulfur compounds from *Allium* spp.: from processing and preservation to evaluation of their bioavailability, antimicrobial, and anti-inflammatory properties. *Food Chem*. 2019;276:680-691.
3. Ansary J, Forbes-Hernández TY, Gil E, et al. Potential health benefit of garlic based on human intervention studies: a brief overview. *Antioxidants*. 2020;9(7):1-35.
4. Vargo RJ, Warner BM, Potluri A, Prasad JL. Garlic burn of the oral mucosa: a case report and review of self-treatment chemical burns. *J Am Dent Assoc*. 2017;148(10):767-771.
5. Thuy BTP, My TTA, Hai NTT, et al. Investigation into SARS-CoV-2 resistance of compounds in garlic essential oil. *ACS Omega*. 2020;5(14):8312-8320.
6. Donma MM, Donma O. The effects of allium sativum on immunity within the scope of COVID-19 infection. *Med Hypotheses*. 2020;144:109934.
7. Schimmel J, Camarena-Michel A, Hoyte C. Pediatric cases involving chemical burns to garlic used to treat warts. *Dermatitis*. 2019;30(1):80-82.
8. Xu S, Heller M, Wu PA, Nambudiri VE. Chemical burn caused by topical application of garlic under occlusion. *Dermatol Online J*. 2014;20(1):21261.
9. Yilmaz HH, Gormez O, Hastar E, Yildirim D, Aksoy MC. Garlic burn in a patient with trigeminal neuralgia: a case report. *Eur J Dent*. 2010;04(01):88-90.
10. Sharp O, Waseem S, Wong KY. A garlic burn. *BMJ Case Rep*. 2018;2018:bcr-2018-226027.
11. Sisson D, Balmer C. A chemical burn from a garlic poultice applied to the face to treat toothache: a case report. *Prim Dent J*. 2014;3(1):28-29.
12. Baatsch B, Zimmer S, Rodrigues Recchia D, Büssing A. Complementary and alternative therapies in dentistry and

- characteristics of dentists who recommend them. *Complement Ther Med*. 2017;35:64-69.
13. Lissiman E, Bhasale AL, Cohen M. Garlic for the common cold. *Cochrane Database Syst Rev*. 2014;2014(1):CD006206.
  14. Schwingshackl L, Missbach B, Hoffmann G. An umbrella review of garlic intake and risk of cardiovascular disease. *Phytotherapy*. 2016;23(11):1127-1133.
  15. Miraghajani M, Rafie N, Hossein H, Bagher L, Azadbakht L. Aged garlic and cancer: a systematic review. *Int J Prev Med*. 2017;8:1-10.
  16. Chow KM, Law BMH, Ng MSN, et al. A review of psychological issues among patients and healthcare staff during two major coronavirus disease outbreaks in China: contributory factors and management strategies. *Int J Environ Res Public Health*. 2020;17(18):6673.
  17. Rouf R, Uddin SJ, Sarker DK, et al. Antiviral potential of garlic (*Allium sativum*) and its organosulfur compounds: a systematic update of pre-clinical and clinical data. *Trends Food Sci Technol*. 2020;104:219-234.
  18. Borrelli F, Capasso R, Izzo AA. Garlic (*Allium sativum* L.): adverse effects and drug interactions in humans. *Mol Nutr Food Res*. 2007;51(11):1386-1397.
  19. Rao PPJ, Shetty BSK, ShameemShah K, Kumaraswamy M, Kamath GS, Ullasa S. "Garlic burns due to naturopathic folk remedy"—an emphasis on its elimination. *Burns*. 2009;35(4):612.
  20. Strickler L, Harjo T. Burns due to application of raw garlic to the feet as a home remedy for fever. *Pediatr Emerg Care*. 2019;35(12):e234-e235.
  21. Monaghesh E, Hajizadeh A. The role of telehealth during COVID-19 outbreak: a systematic review based on current evidence. *BMC Public Health*. 2020;20(1):1193.
  22. Irving M, Stewart R, Spallek H, Blinkhorn A. Using teledentistry in clinical practice as an enabler to improve access to clinical care: a qualitative systematic review. *J Telemed Telecare*. 2018;24(3):129-146.

**How to cite this article:** Muniz IAF, Campos DeS, Shinkai RSA, Trindade TG, Cosme-Trindade DC. Case report of oral mucosa garlic burn during COVID-19 pandemic outbreak and role of teledentistry to manage oral health in an older adult woman. *Spec Care Dentist*. 2021;41:639–643. <https://doi.org/10.1111/scd.12605>