

Clinical Paper  
Orthognathic Surgery

# Nasolabial soft tissue effects of segmented and non-segmented Le Fort I osteotomy using a modified alar cinch technique—a cone beam computed tomography evaluation

A. Paredes de Sousa Gil<sup>1,2,3</sup>,  
R. Guijarro-Martínez<sup>1,2</sup>,  
O. L. Haas Jr.<sup>1,2,3</sup>, J. Masià-Gridilla<sup>1</sup>,  
A. Valls-Ontañón<sup>1,2</sup>, R. B. de Oliveira<sup>3</sup>,  
F. Hernández-Alfaro<sup>1,2</sup>

<sup>1</sup>Institute of Maxillofacial Surgery, Teknon Medical Centre, Barcelona, Spain; <sup>2</sup>Department of Oral and Maxillofacial Surgery, Universitat Internacional de Catalunya, Sant Cugat del Vallès, Barcelona, Spain; <sup>3</sup>Department of Oral and Maxillofacial Surgery, Pontifícia Universidade Católica do Rio Grande do Sul (PUCRS), Porto Alegre, Rio Grande do Sul, Brazil

A. Paredes de Sousa Gil, R. Guijarro-Martínez, O. L. Haas Jr., J. Masià-Gridilla, A. Valls-Ontañón, R. B. de Oliveira, F. Hernández-Alfaro: Nasolabial soft tissue effects of segmented and non-segmented Le Fort I osteotomy using a modified alar cinch technique—a cone beam computed tomography evaluation. *Int. J. Oral Maxillofac. Surg.* 2020; 49: 889–894. © 2019 International Association of Oral and Maxillofacial Surgeons. Published by Elsevier Ltd. All rights reserved.

**Abstract.** The aim of this study was to verify soft tissues changes and the effect of a minimally invasive surgical technique in the nasolabial region after segmented and non-segmented Le Fort I osteotomy, using cone beam computed tomography (CBCT) evaluation of three-dimensional (3D) volume surfaces. Two groups were evaluated: group 1, bimaxillary surgery with maxillary segmentation ( $n = 40$ ); group 2, bimaxillary surgery without maxillary segmentation ( $n = 40$ ). In both groups, a specific alar cinching technique was used to control nasal base broadening. CBCT evaluation was performed at three different treatment time points: T0, 1 month before surgery; T1, 1 month after surgery; T2, 1 year after surgery. The results showed statistically significant differences in the nasolabial area ( $P < 0.001$ ). For group 1, the mean change in alar base width ( $Al_{inf}-Al_{inf}$ ) was  $1.31 \pm 1.40$  mm at T1 and  $0.93 \pm 1.77$  mm at T2; for group 2 these values were  $1.12 \pm 2.01$  mm at T1 and  $0.54 \pm 1.54$  mm at T2. For group 1, the mean changes in inter-alar width ( $Al-Al$ ) were  $1.68 \pm 1.46$  mm at T1 and  $1.49 \pm 1.33$  mm at T2; for group 2, they were  $2.22 \pm 1.93$  mm at T1 and  $1.34 \pm 1.79$  mm at T2. The alar cinch technique proposed here appears to be effective in controlling nasolabial soft tissue widening.

**Key words:** three-dimensional analysis; Le Fort I osteotomy; soft tissue analysis; virtual planning.

Accepted for publication  
Available online 4 December 2019

Although the primary aim of orthognathic surgery is the correction of an underlying deformity, the number of patients seeking treatment with a strong aesthetic motivation has increased dramatically<sup>1</sup>.

The Le Fort I osteotomy enables maxillary repositioning in all three planes of space, and each movement has different effects on the nasolabial region and the overall facial aesthetics<sup>2</sup>. These effects commonly include the alar base dimensions and morphology, the nasolabial angle, the position of the upper lip, and the nasal tip area<sup>3</sup>. Changes in the external nasal morphology are related to both the direction and magnitude of maxillary repositioning, the greatest changes occurring with superior and/or anterior surgical movements<sup>4</sup>. They include upturning of the nasal tip, widening of the alar base, flattening and thinning of the upper lip, down-turning of the oral commissures, and loss of vermilion of the upper lip<sup>5</sup>.

The degree of sub-periosteal dissection and the degree of flap elevation may play an important role in changes in the soft tissues in this area, just as the amount of skeletal movement influences nasal widening<sup>6</sup>. Most muscle insertions around the alar base area are detached during regular maxillary access, but the functions of the unaffected muscles with outer insertions remain unchanged. As the soft tissues are pulled by the remaining muscles, freeing of the facial muscles from the nasolabial area and the anterior nasal spine (ANS) allows the muscles to be retracted laterally.

Modifications of the standard Le Fort I osteotomy that preserve the insertions of the perinasal musculature and the pre-existing position of the ANS and nasal septum have been reported, with excellent clinical outcomes<sup>7,8</sup>. Similarly, V-Y closure of the soft tissues and an alar cinch suture have also been described to counteract the detrimental effects in the nasolabial region<sup>3-5,6,8-11</sup>, although their effectiveness remains controversial<sup>5,9,10</sup>.

The soft tissue behaviour after orthognathic surgery seems to be complex and requires three-dimensional (3D) analysis. Among several 3D analysis strategies, cone beam computed tomography (CBCT) provides an accurate representation of both the hard and soft tissues with low radiation and greater dimensional accuracy<sup>12,13</sup>.

The purpose of this study was to verify the soft tissues changes and the effect of a minimally invasive surgical technique in the nasolabial area after segmented and non-segmented Le Fort I osteotomy using CBCT evaluation of 3D volume surfaces.

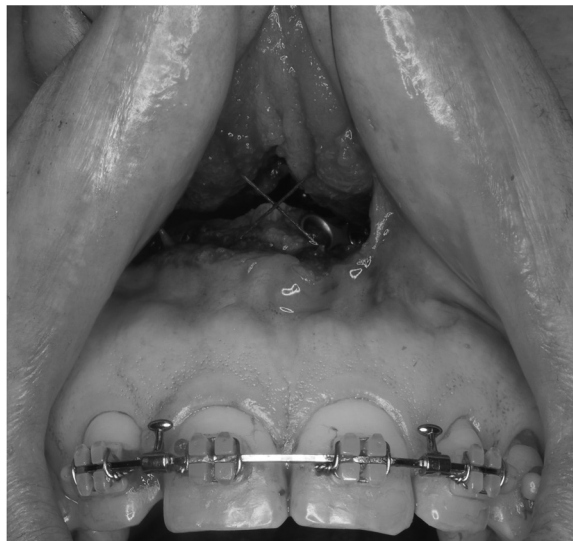


Fig. 1. Intraoral aspect of the minimally invasive incision in the buccal sulcus of the premaxilla and the modified alar cinch suture.

## Materials and methods

### Sample selection

A sample of 80 adult participants who had undergone bimaxillary orthognathic surgery at a specialized centre for the treatment of dentofacial deformity was recruited retrospectively. All procedures were performed by the same surgeon and senior author of this paper (F.H.A.) between January 2011 and January 2015. The patients were divided into two study groups: group 1, patients who underwent segmented Le Fort I osteotomy ( $n = 40$ ); group 2, patients who underwent non-segmented Le Fort I osteotomy ( $n = 40$ ). The inclusion criteria were as follows: (1) dentofacial deformity requiring orthognathic surgery treatment with Le Fort I osteotomy and bilateral sagittal split osteotomy (BSSO); (2) non-growing and non-syndromic patients; (3) no history of previous facial trauma or surgery; (4) written informed consent; (5) patients with healthy, asymptomatic temporomandibular joints; (6) CBCT evaluation at 1 month preoperative (T0), 1 month after surgery (T1), and 1 year after surgery (T2). A sample size calculation was performed to determine the appropriate sample size based on the previous results of 20 patients (10 in each group). This indicated that 30 participants were required in each group to compare nasolabial changes based on an effect size of 0.60, 80% power, and at a 5% level of significance.

### Surgery

All patients underwent orthognathic surgery under general anaesthesia and naso-

tracheal intubation. The maxilla was approached through a minimally invasive incision in the buccal sulcus of the premaxilla. A Le Fort I osteotomy was performed according to the so-called 'twist technique'<sup>14</sup>. After skeletal repositioning and fixation, a modified alar cinch suture and V-Y closure were performed<sup>8</sup> (Fig. 1). Incisions from tooth 2 to 2 were classified as small; from 3 to 3 were classified as medium; and from 4 to 4 were classified as large. Postoperatively, all patients wore a closed-circuit cold mask (17 °C) during hospital admission and were discharged 24 hours after surgery. Standard antibiotic and anti-inflammatory medications were prescribed.

### CBCT evaluation

To quantify the amount and direction of the maxillary movements, landmarks were marked in the midline sagittal view of the maxillary bone (Fig. 2). To evaluate the soft tissue changes after maxillary repositioning, landmarks were marked in the soft tissue 3D reconstruction (Fig. 3). Linear and angular measurements were performed by one author (A.P.S.G.) on the CBCT images obtained at T0, T1, and T2. To ensure accurate and reproducible measurements, the examiner repeated the protocol, tagging virtual models of 20 patients in each group 1 month later.

The CBCT images were collected from iCAT Vision-Q version 1.8.0.5 software in DICOM format (Digital Imaging and Communications in Medicine) and processed using Dolphin 3D Orthognathic Surgery Planning Software version 11.8 in a Pentium 4 Workstation (Processor 3.8

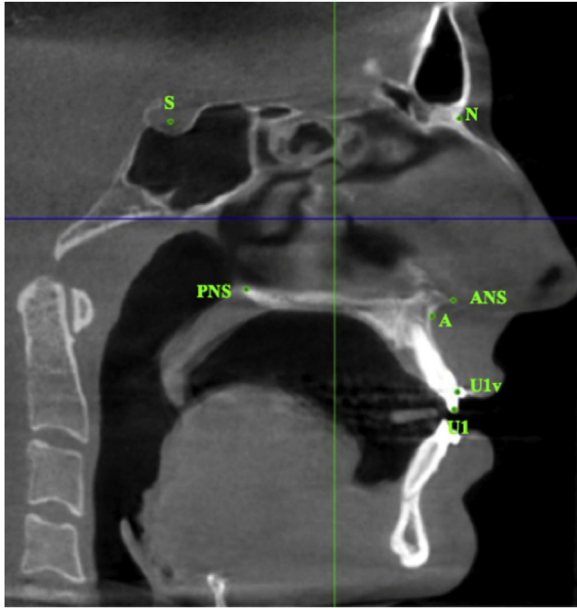


Fig. 2. Midline sagittal view of maxillary bone. N: nasion; ANS: anterior nasal spine; A: A-point; U1v: vestibular surface of the upper incisor; U1: upper incisor; PNS: posterior nasal spine; S: sella turcica.

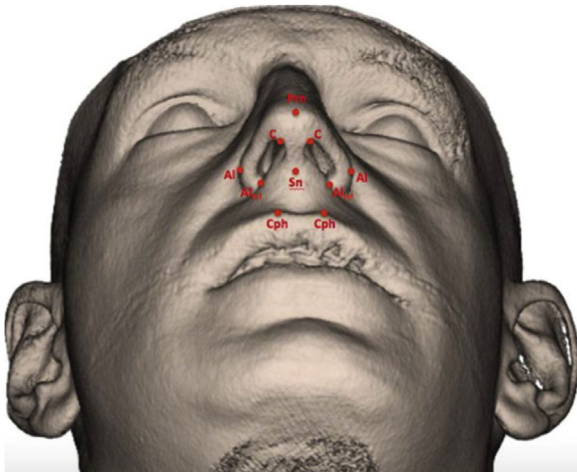


Fig. 3. Three-dimensional soft tissue landmarks. Prn: pronasale; C: columella; Al: alae; Al<sub>inf</sub>: alar base; Sn: subnasale; Cph: cupid Bow.

GHz, W/SP5 Windows XP Professional, 120 GB memory, 2 GB RAM). A 3D volume was created with hard and soft tissue reconstruction in the T0, T1, and T2 databases. The voxel-based superimpositions between the T0 and T1 volumes, and between the T0 and T2 volumes were performed with the anterior cranial base as an anatomical reference<sup>15</sup>, in order to standardize measurements of upper lip length and alar and alar base dimensions.

#### Statistical analysis

A descriptive analysis was performed for the most relevant statistics for all analysed

variables. The mean, standard deviation, minimum, maximum, and median were calculated for continuous variables, and absolute and relative frequencies (percentages) for qualitative variables. The Student *t*-test for paired data was used to compare the mean changes in the nasolabial soft tissues at each studied time point. Two-way analysis of variance (ANOVA) for repeated measurements was used to assess the nasolabial dimensions according to the type of surgery and incision size, and according to the type of surgery and occlusal plane rotation. Bonferroni's test was applied for multiple comparisons. Pearson's correlation coefficient was used

to assess the correlation between maxillary advancement and inter-alar and alar base width dimensions. The level of statistical significance was set at  $P < 0.05$ .

#### Results

Eighty patients were eligible according to the inclusion criteria. The majority of the sample was female (62.5%), and the mean age of the patients was 29.4 years (range 17–86 years). The bimaxillary complex was rotated counterclockwise in 56 patients and clockwise in 24 patients. The average maxillary advancement at A-point was 4.25 mm (4.1 mm in group 1 and 4.4 mm in group 2). Incisions were essentially small (83.7%), especially in segmented maxillary surgery (92.5%).

The mean inter-alar widening (Al–Al) was statistically significant for both groups at T1 and at T2 ( $P < 0.001$ ). In group 1, it was  $1.68 \pm 1.46$  mm at T1 and  $1.49 \pm 1.33$  mm at T2; in group 2, it was  $2.22 \pm 1.93$  mm at T1 and  $1.34 \pm 1.79$  mm at T2. There was no statistically significant difference in inter-alar width between group 1 and group 2 at T1 ( $P = 0.168$ ) or at T2 ( $P = 0.684$ ). The mean alar base widening (Al<sub>inf</sub>–Al<sub>inf</sub>) was statistically significant for both groups at T1 and at T2 ( $P < 0.001$ ). In group 1, it was  $1.31 \pm 1.40$  mm at T1 and  $0.93 \pm 1.77$  mm at T2; in group 2, it was  $1.12 \pm 2.01$  mm at T1 and  $0.54 \pm 1.54$  mm at T2. There was no statistically significant difference in alar base width between group 1 and group 2 at T1 ( $P = 0.614$ ) or at T2 ( $P = 0.289$ ). The mean upper lip lengthening (Al<sub>inf</sub>–Cph) in group 1 was  $1.30 \pm 1.69$  mm at T1 and  $1.54 \pm 1.64$  mm at T2; for group 2 it was  $1.18 \pm 1.40$  mm at T1 and  $1.41 \pm 1.57$  mm at T2 (Table 1).

The size of the incision did not have a statistically significant influence on inter-alar width, alar base width, or upper lip length at T1 ( $P = 0.455$ ,  $P = 0.745$ , and  $P = 0.323$ , respectively) or T2 ( $P = 0.988$ ,  $P = 0.311$ , and  $P = 0.439$ , respectively) (Table 2).

Both inter-alar and alar base widening were correlated with the magnitude of maxillary advancement at T2 considering the global sample, with  $r = 0.273$  ( $P = 0.021$ ) and  $r = 0.340$  ( $P = 0.004$ ), respectively. Alar base widening was more evident for group 1, with  $r = 0.377$  ( $P = 0.020$ ) (Fig. 4).

Similarly, occlusal plane rotation did not have any statistically significant influence on inter-alar width or alar base width at T1 ( $P = 0.494$  and  $P = 0.607$ , respectively) or T2 ( $P = 0.458$  and  $P = 0.833$ , respectively). Upper lip lengthening was

Table 1. Nasolabial changes (millimetres) according to the type of surgery.

Type of surgery	Nasolabial changes					
	Inter-alar width (Al-Al)		Alar base width (Al <sub>inf</sub> -Al <sub>inf</sub> )		Upper lip length (Al <sub>inf</sub> -Cph)	
	T1 - T0	T2 - T0	T1 - T0	T2 - T0	T1 - T0	T2 - T0
Group 1	1.68 ± 1.46	1.49 ± 1.33	1.31 ± 1.40	0.93 ± 1.77	1.30 ± 1.69	1.54 ± 1.64
Group 2	2.22 ± 1.93	1.34 ± 1.79	1.12 ± 2.01	0.54 ± 1.54	1.18 ± 1.40	1.41 ± 1.57

T0, 1 month preoperative; T1, 1 month postoperative; T2, 1 year postoperative. Group 1, segmented maxillary osteotomy; group 2, non-segmented maxillary osteotomy.

Table 2. Inter-alar width, alar base width, and upper lip changes (millimetres) according to the size of the incision and occlusal plane rotation.

	Type of surgery					
	Inter-alar width (Al-Al)		Alar base width (Al <sub>inf</sub> -Al <sub>inf</sub> )		Upper lip length (Al <sub>inf</sub> -Cph)	
	T1 - T0	T2 - T0	T1 - T0	T2 - T0	T1 - T0	T2 - T0
Size of incision	<i>P</i> = 0.455	<i>P</i> = 0.988	<i>P</i> = 0.745	<i>P</i> = 0.311	<i>P</i> = 0.323	<i>P</i> = 0.439
Occlusal plane rotation	<i>P</i> = 0.494	<i>P</i> = 0.458	<i>P</i> = 0.607	<i>P</i> = 0.833	<i>P</i> = 0.232	<i>P</i> = 0.016*

T0, 1 month preoperative; T1, 1 month postoperative; T2, 1 year postoperative.

\**P* < 0.05.

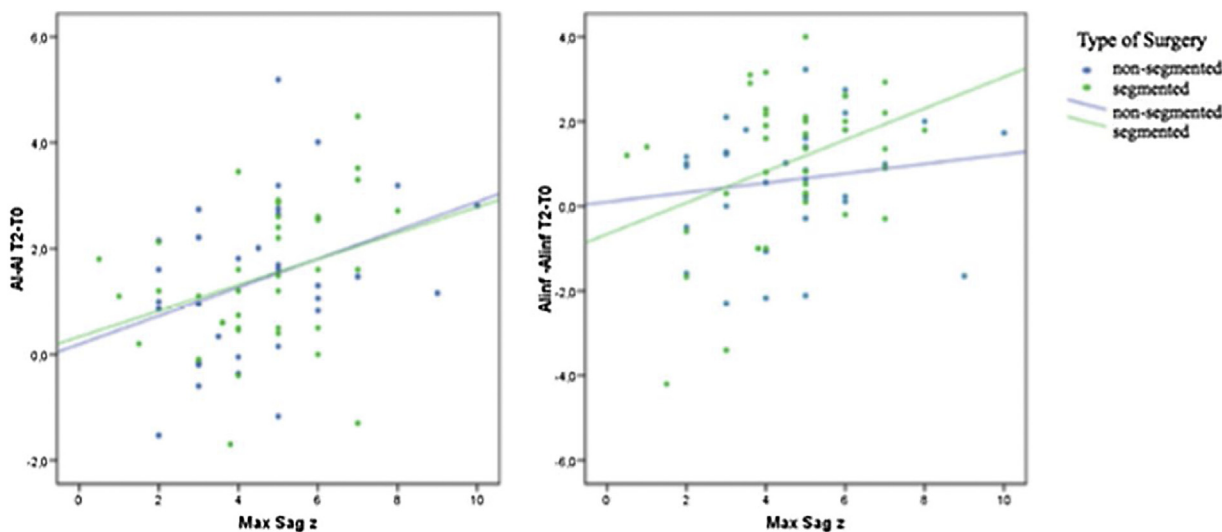


Fig. 4. Correlation between maxillary advancement and inter-alar width (Al-Al) and alar base width (Al<sub>inf</sub>-Al<sub>inf</sub>).

correlated with the occlusal plane rotation at T2 (*P* = 0.016), especially in clockwise rotation (*P* = 0.009). It was statistically significant for group 1 (*P* = 0.045).

## Discussion

This study evaluated 80 patients who underwent bimaxillary orthognathic surgery, comparing the nasolabial soft tissue effects according to whether the maxilla was segmented or not. In addition, potential correlations between soft tissues changes, occlusal plane rotation, and maxillary advancement were also investigated.

Using a minimally invasive surgical technique for the execution of the Le Fort I osteotomy, maxillary segmentation was found to have a small effect on the nasolabial soft tissues (*P* < 0.001). Group 1 showed a mean inter-alar and alar base widening at T2 of 1.49 ± 1.33 mm and 0.93 ± 1.77 mm, respectively; while

group 2 showed a mean inter-alar and alar base widening at T2 of 1.34 ± 1.79 mm and 0.54 ± 1.54 mm, respectively. Other studies are in agreement with the current results, showing effective nasal width control with the alar cinch suture at up to 12 months of follow-up<sup>16-18</sup>. Conversely, Metzler et al.<sup>19</sup> analysed the 3D nasolabial changes that occur after surgically assisted maxillary expansion (SAME) and found significant increases (*P* < 0.05) in alar width (from 33.1 mm to 34.5 mm) even when alar cinch suture and V-Y closure were performed. These soft tissue changes were hypothesized to be caused mainly by the surgical degloving and freeing of the nasal septum, independent of the skeletal movements, because no maxillary advancement was performed during SAME<sup>19</sup>.

According to Guymon et al.<sup>16</sup> and Wolford<sup>20</sup>, the alar base width increases for three main reasons: the release of perios-

teum and muscle attachments adjacent to the nose; oedema, causing the base of the nose to expand; and spatial changes of supportive bone to the nasal base in a superior or anterior direction. Most surgical protocols involve sub-periosteal dissection of the whole facial aspect of the maxilla<sup>8,21</sup>. Elevation of the paranasal soft tissues without adequate reattachment contributes to unfavourable post orthognathic surgery soft tissues changes in this region<sup>5</sup>. To reorient the displaced perinasal musculature and to control alar base width after maxillary osteotomy, many have advocated that an alar base cinch suture should be used in addition to other adjunctive procedures, such as nasal spine reduction, nasal floor reduction, and V-Y closure<sup>3,5,6,8-11</sup>. Phillips et al.<sup>22</sup> analysed 30 patients who underwent one-piece maxillary intrusion with standard soft tissue incision and V-Y closure. They reported that the soft tissues changes ob-

served in the nose alae and upper lip vermilion may be caused by the type and placement of soft tissue incisions rather than being a direct result of hard tissue changes that occur at surgery. In the present study, no correlation was found between the size of the incision and nasolabial changes, possibly because even the large incisions considered were smaller than the conventional maxillary approach, resulting in less damage to the perinasal muscles<sup>8</sup>.

It is well documented that soft tissue swelling can influence the postoperative soft tissue response and may take up to a year to resolve<sup>23,24</sup>. A greater than 10% change over 5 years has been shown to continue to occur in certain regions, such as the subnasale point and lips<sup>23,24</sup>. In both of the groups in the present study, inter-alar and alar base width changes were decreased at T2 when compared with T1, thereby suggesting the importance of soft tissue oedema when evaluating postoperative results, especially in the nasolabial region. Recent studies using CBCT images to measure nasal changes found that the alar cinch suture had no effect on controlling alar base widening<sup>25,26</sup>.

In this study, both groups – segmented and non-segmented – underwent a similar amount of maxillary anterior movement (4.1 mm and 4.4 mm, respectively), as well as similar occlusal plane rotations. The results showed a positive correlation between the magnitude of anterior/superior maxillary movement and inter-alar widening ( $P = 0.021$ ), especially in group 1 ( $P = 0.020$ ). Westermarck et al.<sup>17</sup> and Rosen<sup>27</sup> also found a positive correlation between alar flaring and the degree of maxillary impaction and/or advancement. On the other hand, Raithatha et al.<sup>24</sup> compared the long-term alar base widening in two groups and did not find any statistically significant differences between the cinch group and the control group regarding the extent of maxillary advancement and impaction. They attributed their results to a smaller degree of maxillary movement when compared to other studies.

No correlation between the occlusal plane rotation and the inter-alar and alar base width changes was found. Although maxillary sagittal and vertical movements did not produce significant upper lip changes, lengthening was observed in clockwise rotations, especially when the maxilla was segmented ( $P = 0.045$ ). In a multi-part systematic review, Moragas et al.<sup>28</sup> reported that the upper lip tends to follow the skeletal movement more

closely if both an alar cinch suture and V–Y closure are performed. Similarly, the amount of vermilion exposure can be influenced by the V–Y closure.

The proposed minimally invasive surgical Le Fort I technique avoids excessive soft tissue elevation and maintains the nasal sphincter muscles attached to the anterior nasal spine. The limited intraoral access as well as the crossed alar cinch suture and V–Y closure seemed to have an additional beneficial effect in controlling the enlargement of the nasal base, preserving upper lip form and length.

### Funding

None.

### Competing interests

None.

### Ethical approval

The clinical trial was approved by the Ethics Committee at the Quirón-Teknon Medical Centre Barcelona (Barcelona, Spain; number 2018/01-MF-UIC).

### Patient consent

At the study clinic, patients agree to the scientific use of their clinical photographs when they give their written consent for treatment.

### References

1. Rauso R, Tartaro G, Tozzi U, Colella G, Santagata M. Nasolabial changes after maxillary advancement. *J Craniofac Surg* 2011;**22**:809–12.
2. Pourdanesh F, Sharifi R, Mohebbi A, Jamilian A. Effects of maxillary advancement and impaction on nasal airway function. *Int J Oral Maxillofac Surg* 2012;**41**:1350–2.
3. Bertossi D, Albanese MD, Malchiodi L, Procacci P, Nocini PF. Surgical alar base management with a personal technique: the tightening alar base suture. *Arch Facial Plast Surg* 2007;**9**:248–51.
4. Collins PC, Epker BN. The alar base cinch: a technique for prevention of alar base flaring secondary to maxillary surgery. *Oral Surg Oral Med Oral Pathol* 1982;**53**:549–53.
5. Shams MG, Motamedi MHK. A more effective alar cinch technique. *J Oral Maxillofac Surg* 2002;**60**:712–5.
6. Rauso R, Gherardini G, Santillo V, Biondi P, Santagata M, Tartaro G. Comparison of two techniques of cinch suturing to avoid widening of the base of the nose after Le Fort I osteotomy. *Br J Oral Maxillofac Surg* 2010;**48**:356–9.
7. Mommaerts MY, Abeloos JV, De Clercq CA, Neyt LF. The effect of the subspinal Le Fort I-type osteotomy on interalar rim width. *Int J Adult Orthodon Orthognath Surg* 1997;**12**:95–100.
8. Hernández-Alfaro F, Paredes de Sousa Gil A, Haas Junior OL, Masià-Gridilla J, Valls-Otañón A, Guijarro-Martínez R. Soft tissue management to control nasal changes after Le Fort I Osteotomy. *Orthod F* 2017;**88**:343–6.
9. Stewart A, Edler R. Efficacy and stability of the alar base cinch suture. *Br J Oral Maxillofac Surg* 2011;**49**:623–6.
10. Shoji T, Muto T, Takahashi M, Akizuki K, Tsuchida Y. The stability of an alar cinch suture after Le Fort I and mandibular osteotomies in Japanese patients with Class III malocclusions. *Br J Oral Maxillofac Surg* 2012;**50**:361–4.
11. Millard Jr DR. The alar cinch in the flat, flaring nose. *Plast Reconstr Surg* 1980;**65**:669–72.
12. Kim BR, Oh KM, Cevidanes L, Park JE, Sim HS, Seo SK, Kim YJ, Park YH. Analysis of 3D soft tissue changes after 1- and 2-jaw orthognathic surgery in mandibular prognathism patients. *J Oral Maxillofac Surg* 2013;**71**:151–61.
13. Guijarro-Martínez R, Swennen GR. Cone-beam computerized tomography imaging and analysis of the upper airway: a systematic review of the literature. *Int J Oral Maxillofac Surg* 2011;**40**:1227–37.
14. Hernández-Alfaro F, Guijarro-Martínez R. “Twist technique” for pterygomaxillary dysfunction in minimally invasive Le Fort I osteotomy. *J Oral Maxillofac Surg* 2013;**71**:389–92.
15. Haas Jr OL, Guijarro-Martínez R, de Sousa Gil AP, Méndez-Manjón I, Valls-Otañón A, de Oliveira RB, Hernández-Alfaro F. Cranial base superimposition of cone-beam computed tomography images: a voxel-based protocol validation. *J Craniofac Surg* 2019; **30**:1809–14.
16. Guymon M, Crosby D, Wolford LM. The alar base cinch suture to control nasal width in maxillary osteotomies. *Int J Adult Orthodon Orthognath Surg* 1988;**3**:89–95.
17. Westermarck AH, Bystedt H, Von Konow L, Sallstrom KO. Nasolabial morphology after Le Fort I osteotomies. Effect of alar base suture. *Int J Oral Maxillofac Surg* 1991;**20**:25–30.
18. Yen CY, Kuo CL, Liu IH, Su WC, Jiang HR, Huang IG, Liu SY, Lee SY. Modified alar base cinch suture fixation at the bilateral lower border of the piriform rim after a maxillary Le Fort I osteotomy. *Int J Oral Maxillofac Surg* 2016;**45**:1459–63.
19. Metzler P, Geiger EJ, Chang CC, Steinbacher DM. Surgically assisted maxillary expansion imparts three-dimensional nasal change. *J Oral Maxillofac Surg* 2014;**72**:2005–14.
20. Wolford LM. Lip–nasal aesthetics following Le Fort I osteotomy — discussion. *Plast Reconstr Surg* 1988;**81**:180–2.
21. Schendel SA, Carlotti AE. Nasal considerations in orthognathic surgery. *Am J Orthod Dentofacial Orthop* 1991;**100**:197–208.

22. Phillips C, Devereux JP, Tulloch JF, Tucker MR. Full-face soft tissue response to surgical maxillary intrusion. *Int J Adult Orthodon Orthognath Surg* 1986;1:299–304.
23. Hack GA, de Mol van Otterloo JJ, Nanda R. Long-term stability and prediction of soft tissue changes after LeFort I surgery. *Am J Orthod Dentofacial Orthop* 1993;104:544–55.
24. Raithatha R, Naini FB, Patel S, Sherriff M, Witherow H. Long-term stability of limiting nasal alar base width changes with a cinch suture following Le Fort I osteotomy with submental intubation. *Int J Oral Maxillofac Surg* 2017;46:1372–9.
25. Ryckman MS, Harrison S, Oliver D, Sander C, Boryor AA, Hohmann AA, Kilic F, Kim KB. Soft-tissue changes after maxillomandibular advancement surgery assessed with cone-beam computed tomography. *Am J Orthod Dentofacial Orthop* 2010;137(Suppl. 4):S86–93.
26. Park SB, Yoon JK, Kim YI, Hwang DS, Cho BH, Son WS. The evaluation of the nasal morphologic changes after bimaxillary surgery in skeletal class III malocclusion by using the superimposition of cone-beam computed tomography (CBCT) volumes. *J Craniomaxillofac Surg* 2012;40:87–92.
27. Rosen HM. Lip–nasal aesthetics following Le Fort I osteotomy. *Plast Reconstr Surg* 1988;81:171–82.
28. Moragas JSM, Van Cauteren W, Mommaerts MY. A systematic review on soft-to-hard tissue ratios in orthognathic surgery part I: maxillary repositioning osteotomy. *J Craniomaxillofac Surg* 2014;42:1341–51.

Address:

Ariane Paredes de Sousa Gil  
Instituto Maxilofacial  
Teknon Medical Center  
Carrer Vilana  
12 (Off 185)  
Barcelona  
08022  
Spain  
Tel.: +34 933 933 185; Fax: +34 933 933 085  
E-mail: [aps.gil@hotmail.com](mailto:aps.gil@hotmail.com)