

# Neonatal seizures: Is there a relationship between ictal electroclinical features and etiology? A critical appraisal based on a systematic literature review

Magda L. Nunes<sup>1</sup> | Elissa G. Yozawitz<sup>2</sup> | Sameer Zuberi<sup>3</sup> | Eli M. Mizrahi<sup>4</sup> |  
 Maria Roberta Cilio<sup>5</sup> | Solomon L. Moshé<sup>6</sup> | Perrine Plouin<sup>7</sup> | Sampsa Vanhatalo<sup>8</sup> |  
 Ronit M. Pressler<sup>9</sup> | Task Force on Neonatal Seizures, ILAE Commission on Classification &  
 Terminology

<sup>1</sup>Pontifical Catholic University of Rio Grande do Sul, School of Medicine and Brain Institute (BraIns), Porto Alegre, RS, Brazil

<sup>2</sup>Saul R. Korey Department of Neurology and Department of Pediatrics, Albert Einstein College of Medicine and Montefiore Medical Center, Bronx, New York

<sup>3</sup>Fraser of Allander Neurosciences Unit, Royal Hospital for Children Glasgow, Glasgow, UK

<sup>4</sup>Peter Kellaway Section of Neurophysiology, Department of Neurology, Section of Pediatric Neurology, Department of Pediatrics, Baylor College of Medicine, Houston, Texas

<sup>5</sup>Departments of Neurology and Pediatrics, University of California, San Francisco, California

<sup>6</sup>Saul R. Korey Department of Neurology, Department of Pediatrics and Dominick P. Purpura Department of Neuroscience, Albert Einstein College of Medicine and Montefiore Medical Center, Bronx, New York

<sup>7</sup>Clinical Neurophysiology Unit in Saint Vincent de Paul and in Necker Hospital, Paris, France

<sup>8</sup>Children's Hospital Department of Clinical Neurophysiology and Neurological Sciences, HUS Medical Imaging Center, Helsinki University Central Hospital and University of Helsinki, Helsinki, Finland

<sup>9</sup>Clinical Neuroscience, UCL-Institute of Child Health, London, UK

## Correspondence

Magda L. Nunes, Pontifícia Universidade Católica do Rio Grande do Sul, School of Medicine and Brain Institute (BraIns), Porto Alegre, RS, Brazil.

Email: mlnunes@puers.br

## Funding information

CNPq-Brazil, Grant/Award Number: 306338/2017-3; NIH, Grant/Award Number: U54NS100064 and NS43209; Heffer Family; Segal Family Foundations; Abbe Goldstein/Joshua Lurie; Laurie March/Dan Levitz families

## Summary

The aim of this study was to evaluate whether specific etiologies of neonatal seizures have distinct ictal electroclinical features. A systematic review of English articles using the PubMed database since 2004 (last update 9/26/16). Search terms included text words and Medical Subject Headings (MeSH) terms related to neonatal seizures. Eligible articles included reports of neonates with seizures with a full description of seizure semiology and electroclinical findings. Independent extraction of data was performed by 2 authors using predefined data fields, including study quality indicators. Data were collected for every individual patient described in the articles. The dataset was analyzed with the Fisher exact test. The initial search led to 8507 titles; using filters, 2910 titles and abstracts were identified, with 177 full texts selected to be read. Fifty-seven studies were included in the analysis with 151 neonates (37.7 male and 62.9% term). Genetic etiologies (51%) and sequential seizures (41.1%) predominated in this sample and hypoxic-ischemic encephalopathy (HIE) accounted for

This is an open access article under the terms of the Creative Commons Attribution-NonCommercial-NoDerivs License, which permits use and distribution in any medium, provided the original work is properly cited, the use is non-commercial and no modifications or adaptations are made.

© 2019 The Authors. *Epilepsia Open* published by Wiley Periodicals Inc. on behalf of International League Against Epilepsy.

only 4%. The low prevalence of HIE observed was probably due to a publication bias. A significant association was found between etiology and seizure type: hemorrhage with autonomic seizures ( $P = 0.003$ ), central nervous system (CNS) infection and stroke with clonic seizures ( $P = 0.042$ ,  $P < 0.001$ , respectively), metabolic/vitamin-related disorders, and inborn errors of metabolism with myoclonic seizures ( $P < 0.001$ ). There were also specific electroencephalography (EEG) patterns seen with certain etiologies: vascular disorders and electrolyte imbalance with focal ictal discharges ( $P < 0.001$ ,  $P = 0.049$  respectively), vitamin-related disorders with multifocal ( $P = 0.003$ ), and all categories of genetic disorders with burst-suppression ( $P < 0.001$ ). Clonic and autonomic seizures were more frequently present with focal EEG abnormalities ( $P = 0.001$  and  $P < 0.001$ ), whereas tonic and myoclonic seizures present with burst-suppression ( $P = 0.001$ ,  $P = 0.005$ ). In conclusion, our data suggest that specific associations of etiologies of neonatal seizures with distinct clinical features and EEG patterns might help in the decision to establish appropriate treatment.

#### KEYWORDS

electroclinical features, neonatal EEG, neonatal seizures, semiology

## 1 | INTRODUCTION

Clinical identification of seizures in the neonate remains a challenge to neonatologists and other specialists caring for newborns. Neonates may demonstrate a vast repertoire of movements/behaviors seen in normal as well as sick newborns that may not be epileptic in origin.<sup>1,2</sup> Furthermore, the clinical features of seizures may be less clear compared to seizures in older children and adults. Although the latest World Health Organization (WHO) Guidelines on Neonatal Seizures strongly recommended that all clinical seizures should be confirmed by electroencephalography (EEG), often the equipment is not available in some settings or not at all times in many settings, and the decision to start treatment is based solely on clinical aspects.<sup>3</sup> This can result either in misdiagnosis or overtreatment.<sup>1,3,4</sup>

Identifying associations between neonatal seizure etiology, semiology, and EEG features might help in the distinction of acute symptomatic seizures from seizures related to epilepsy, which influences the proper approach to treatment.

Previous studies that analyzed this relationship were not necessarily based on simultaneous EEG confirmation of the seizures<sup>5-9</sup> or did not express, case by case, the electroclinical aspects of the ictal seizure.<sup>10-14</sup>

We conducted a systematic review in neonates with well-documented electroclinical seizures to answer the following questions: (a) how etiology relates to semiology; (b) how etiology relates to EEG; and (c) how semiology relates to EEG features. We aimed to integrate the findings of existing

#### Key Points

- Specific etiologies of neonatal seizures may be associated with distinct clinical features and these associations might be useful in countries with limited resources
- Specific electroclinical patterns may help in the recognition of the etiology of neonatal seizures
- Widespread use of the Neonatal Task Force proposal should be helpful for collecting data in future studies

studies to see if there is a relationship between ictal electroclinical features and etiology on seizures occurring during the neonatal period.

## 2 | METHODOLOGY

For this systematic review, we used the PubMed database and search terms related to neonatal seizures (see below). The search period was from January 2004 to 2016 (last update 9/26/16), as before 2004, in the majority of studies, the seizure description was not confirmed by video-EEG and was based on the clinical classification proposed by Volpe.<sup>15</sup> The filters used were human studies and English language.

## 2.1 | Inclusion criteria

- Studies describing term and preterm neonates with seizures, with a description of the seizure semiology, concomitant EEG findings, and etiologic investigations.
- Seizures from full-term infants were included if they occurred within 30 days postdelivery.
- Seizures from preterm infants were included if they occurred within the postmenstrual age (gestational age plus chronologic age in weeks) of 40 weeks.

## 2.2 | Search strategy

The following search strategy was employed ((neonatal seizures) OR (neonatal convulsions) OR (“Infant, Newborn”[MeSH]) AND seizures) OR (“Infant, Newborn”[MeSH]) AND convulsions)).

## 2.3 | Selection criteria

Studies were selected if the title and/or abstract suggested a description of semiology, EEG, or video-EEG findings.

## 2.4 | Exclusion criteria

- Review articles, editorials, letters to the editor, articles without individual description of seizure semiology and/or EEG.
- Articles that included EEG and semiology but were not within the neonatal period as described above.

## 2.5 | Data collection and analysis

Titles and abstracts were first screened by 2 authors (MLN and RP) using predefined data fields. All full texts were read by the same authors, and the data were extracted and organized in an Excel table (Microsoft Corp.) and discussed within the group to assess quality indicators and reliability. The following variables were extracted: full bibliographic reference, number of patients, sex, gestational age, age at first seizure, etiology, and seizure semiology with EEG description. We used the list of etiologies as described in the 2017 International League Against Epilepsy (ILAE) classification of seizures and epilepsies<sup>16</sup> but, because hypoxic-ischemic encephalopathy (HIE) is so common in the neonatal period, we assigned it a special category. We have classified vascular etiologies and cortical malformations as a separate group, due to their frequency in this age group, instead of under the rubric of structural category as suggested in the ILAE classification. Thus, the etiologies were classified into the following 7 groups: (a) HIE, (b) cortical malformations, (c) central nervous system (CNS) infection, (d) metabolic (electrolyte imbalance, inborn errors of metabolism, vitamin-related disorders,

and withdrawal seizures), (e) genetic (channelopathies, chromosomal disorders, other gene disorders), (f) vascular (stroke and hemorrhage), and (g) Unknown. Although inborn errors of metabolism and vitamin-related disorders can be included in either genetic or metabolic categories, we decided to include these cases in metabolic disorders. Similarly, although cortical malformations may have a genetic component, for the purpose of this report, we assigned them under the structural category. From the 57 articles included, we could evaluate electroclinical data from a total of 151 neonates (Table 1).

Semiology was described as clonic, tonic, myoclonic, automatisms, epileptic spasms, and autonomic, when it was possible to identify the main clinical feature of the seizure. We used the term sequential seizures, according to the report of ILAE Neonatal Task Force (available online)<sup>17</sup> and the 2017 ILAE classification manual, in situations when it was difficult to identify the dominant feature, typically in longer seizures where a sequence of clinical features was seen, often with changing lateralization.<sup>18</sup> The articles were reviewed by 3 of the authors (RP, MN, and EY) for agreement in seizure type based on the seizure semiology described in the articles. The ictal EEG patterns were classified as focal (unilateral or bilateral onset), multifocal (more than 2 different and independent foci), or burst-suppression. However, in many articles, burst-suppression was described as a background pattern, and the authors did not specify if the seizure episode correlated with the diffuse suppression. In Table 1, we documented how the various authors used the term burst-suppression in their papers.

The guidelines from preferred reporting items for systematic review and meta-analysis and a measurement tool to assess systematic reviews methodology were used to analyze papers included in the study.<sup>19-21</sup> We initially planned to use meta-analytic techniques.<sup>22</sup> However, because there was a large number of studies with only single cases, confidence intervals could not be calculated, thereby preventing the meta-analysis calculations. Nevertheless, we collected and included data for every individual patient described in the studies. Furthermore, the dataset was analyzed as if it came from a single study, with the Fisher exact test. Significant results were considered when the *P*-value was <0.05. When the *P*-value was equal to 0.000, we have expressed it as *P* < 0.001.

The data were analyzed looking at combinations of clinical semiology of the seizures, etiology, and EEG patterns. In the statistical analysis, if the initial evaluation of the data suggested an association between or among the groups of etiology, all the other categories were grouped together. For example, if an association between a channelopathy (genetic group) and tonic seizures was observed, the statistical analysis (Fisher exact test) was done by grouping all other etiologies (ie, channelopathy vs all others) and all other seizure types (ie, tonic vs all others) and creating a 2 × 2 table. The same approach was applied to compare seizure type and EEG as well as etiology and EEG.

**TABLE 1** Full description of the sources

GA/sex	Seizure onset (d)	Semiology (seizure description by author)	Seizure classification	Etiology	EEG
Pisano et al <i>Epilepsia</i> , 2015. N = 7/15					
(NA)/female	3rd	Tonic asymmetric	Tonic	KCNQ2 encephalopathy	Burst-suppression <sup>a</sup>
(NA)/female	1st	Tonic asymmetric, apnea	Tonic	KCNQ2 encephalopathy	Burst-suppression <sup>a</sup>
(NA)/male	3rd	Tonic asymmetric	Tonic	KCNQ2 encephalopathy	Focal (temporal)
(NA)/female	1st	Clonic	Clonic	KCNQ2 encephalopathy	Multifocal
(NA)/male	2nd	Tonic and clonic	Sequential (tonic, clonic)	KCNQ2 encephalopathy	Multifocal
(NA)/female	3rd	Tonic asymmetric	Tonic	KCNQ2 encephalopathy	Multifocal
(NA)/male	2nd	Tonic asymmetric	Tonic	KCNQ2 encephalopathy	Multifocal
Dereymaeker et al <i>Eur J Pediatr Neurol</i> , 2015. N = 1/1					
Term/female	9th	Clonic movements	Clonic	Transient hypothyroidism/viral encephalitis by HPe V type 3	Multifocal
Cirillo et al <i>Pediatrics</i> , 2015. N = 2/2					
Term/female	5th	Myoclonic-tonic and tonic seizures (rhythmic movements of extremities, eye deviation, oxygen desaturation).	Sequential (myoclonic, tonic, autonomic)	<i>ALDH7A1</i> heterozygous mutation (c.328C.T; p.R1103)	Multifocal sharp waves
Term/female	21st	Myoclonic jerks of arms and legs and tonic head deviation (tonic)	Sequential (myoclonic, tonic)	<i>ALDH7A1</i> —unknown	Bilateral continuous epileptiform discharges
Machado et al <i>Einstein (São Paulo)</i> , 2015. N = 2/11					
(NA)/(NA)	9th	Multifocal clonic	Clonic	Left MCA ischemic stroke	Burst-suppression <sup>a</sup>
(NA)/(NA)	1st	Focal clonic	Clonic	Left MCA ischemic stroke	Focal (left temporal)
Raimondi et al <i>BMJ Case Report</i> , 2015. N = 1/1					
Preterm/female	1st	Eye lid blinking, hypersalivation with orobuccal rhythmic movements	Sequential (automatisms, autonomic)	Pyridoxal 5-phosphate deficiency, <i>PNPO</i> mutation	Burst suppression (background pattern)
Nascimento et al <i>Pediatr Neurol</i> , 2015. N = 1/1					
Preterm/male	20th	Crying, conjugate eye deviation to the right, myoclonus of the left eyelid, followed by chewing episodes with sialorrhea	Sequential (tonic, myoclonic, automatisms)	$\beta$ -oxidation defect from a D-bifunctional protein deficiency	Multifocal

(Continues)

TABLE 1 (Continued)

GA/sex	Seizure onset (d)	Semiology (seizure description by author)	Seizure classification	Etiology	EEG
Fukasawa et al <i>Am J Med Gent A</i> , 2015. N = 2/7					
Preterm/male	28th	Apnea and tachycardia, sometimes followed by tonic posturing	Sequential (autonomic, tonic)	Trisomy 18	Rhythmic spikes and slow waves of 2-3 Hz from the right temporal-occipital region
Term/female	2nd	Apnea	Autonomic	Trisomy 18	Rhythmic spikes and slow waves of 1-2 Hz from the right temporal-rolandic-occipital region
Guerin et al <i>J Child Neurol</i> , 2015. N = 1/1					
Preterm/female	1st	Fragmentary and generalized myoclonic jerks	Myoclonic	Pyridox(am)ine-5-phosphate oxidase deficiency	Burst-suppression (background pattern)
Spagnoli et al <i>J Child Neurol</i> , 2015. N = 2/2					
Preterm/male	5th	Multifocal clonic	Clonic	IVH grade III with posthemorrhagic hydrocephalus	Multifocal discharges, alpha-beta range, left centrotemporal or posterior emphasis, less frequently with a right temporal onset
Preterm/female	30th	Clonic events	Clonic	IVH with posthemorrhagic hydrocephalus	Low-voltage alpha-beta activity over the anterior regions, mainly expressed over the right
Paddock et al <i>J Neonatal Perinatal Med</i> , 2014. N = 1/1					
Term/female	1st	Clonic (right hand and leg)	Clonic	Left MCA ischemic stroke	Focal spikes left hemisphere (aEEG)
Saito et al <i>J Hum Genet</i> , 2014. N = 2/2 (siblings)					
Term/female	7th	Focal clonic followed by generalized tonic-clonic	Sequential (clonic, tonic)	Ohtahara ( <i>BRAT1</i> mutation)	Burst-suppression (background pattern)
Term/female	1st	Generalized myoclonic seizures and partial clonic, after tonic and apnea	Sequential (myoclonic, clonic, tonic, autonomic)	Ohtahara	Burst-suppression (background pattern)
Ito et al <i>J Perinatol</i> , 2014. N = 1/1					
Term/female	1st	Deviation of eyeballs, nystagmus, twitching of the eyelids, tonic or clonic activities of the limbs or apnea	Sequential (tonic, autonomic)	Holoprosencephaly	Low-voltage fast rhythms followed by slow waves of increasing amplitude C3-C4 (aEEG)
Allen et al <i>Epilepsia</i> , 2014. N = 3/3					
Term/female	4th	Mainly clonic, but also tonic, minor cyanosis	Sequential (clonic, tonic, autonomic)	BFNS-KCNQ2c.419_430dup	Bilateral independent high-amplitude sharp waves of 1 Hz, normal background
Term/female	6th	Clonic	Clonic	BFNS-KCNQ3 c.989G>A	Excessive sharp waves, normal background

(Continues)

TABLE 1 (Continued)

GA/sex	Seizure onset (d)	Semiology (seizure description by author)	Seizure classification	Etiology	EEG
Term/male	1st	Tonic arm and trunk with cyanosis, grunting and duskiness followed by apnea and hypoxia	Sequential (tonic, autonomic)	KCNQ2-881C>T encephalopathy	Ictal pattern: focal recruiting rhythm right parietal region Interictal: multifocal discharges, followed by background attenuation
Low et al <i>PLoS ONE</i> , 2014. N = 9/9					
Term/male	1st	Clonic right arm	Clonic	Left MCA ischemic stroke	Focal spikes, left central
Term/male	2nd	Dusky episodes	Autonomic	Left MCA ischemic stroke	Focal spikes, left central
Term/male	1st	Clonic left side	Clonic	Right MCA ischemic stroke	Focal spikes, right central
Term/female	1st	Clonic right side	Clonic	Right/left MCA ischemic stroke	Focal spikes, polyspikes left central
Term/female	2nd	Clonic left leg	Clonic	Right MCA ischemic stroke	Focal spikes, polyspikes right central
Term/female	2nd	Clonic right side	Clonic	Left MCA ischemic stroke	Focal spikes, left central
Term/male	1st	Clonic right arm	Clonic	Left MCA ischemic stroke	Focal spikes, left central
Term/male	1st	Clonic right arm	Clonic	Right/left MCA ischemic stroke	Focal spikes, polyspikes left central
Term/male	2nd	Clonic left leg	Clonic	Right MCA ischemic stroke	Focal spikes, polyspikes right central
Pariani et al <i>Pediatr Infect Dis J</i> , 2014. N = 1/2					
Term/female	9th	Myoclonic seizures, apnea and staring	Sequential (myoclonic, autonomic, behavioral arrest)	Parechovirus 3 encephalitis	Paroxysmal activity in the left and right hemisphere
Zerem et al <i>Eur J Paediatr Neurol</i> , 2014. N = 2/2					
Term/male	1st	General tonic extension, cry and usually desaturation	Sequential (tonic, autonomic)	SCN2A mutation (Ohtahara)	Burst-suppression (background pattern)
Term/male	1st	Tonic seizure, eye deviation, bradycardia	Sequential (tonic, autonomic)	SCN2A mutation (Ohtahara)	Ictal: focal discharges right frontal region Interictal: Burst-suppression background
Ansary et al <i>Singapore Med J</i> , 2014. N = 1/1					
Preterm/female	2nd	Multifocal myoclonic (both arms and legs)	Myoclonic	Venlafaxine withdrawal	Focal sharp waves (aEEG)
Kharoshankaya et al <i>Dev Med Child Neurol</i> , 2014. N = 1/1					
Term/male	1st	Clonic (right arm and leg) associated with mouthing and cyanosis	Sequential (clonic, automatisms)	Thalamic infarction	Low voltage (<10 µV) focal left-sided biphasic spike-wave discharges

(Continues)

TABLE 1 (Continued)

GA/sex	Seizure onset (d)	Semiology (seizure description by author)	Seizure classification	Etiology	EEG
Fong et al <i>Pediatr Infect Dis J</i> , 2014. N = 1/1					
Term/female	13th	Focal clonic arm	Clonic	Herpes simplex virus type 1	Focal epileptiform discharges over the midline-vertex and right frontal-midline regions
Numis et al <i>Neurology</i> , 2014. N = 3/3					
Preterm/NA	4th day	Tonic head, conjugate eye, and mouth deviation, unilateral tonic abduction of the limbs, apnea, and desaturation	Sequential (tonic, autonomic)	KCNQ2 epileptic encephalopathy	Low-voltage fast activity followed by recruiting spikes or theta rhythms arising mainly from the central regions of either hemisphere, followed by focal spike-wave complexes and prolonged focal or diffuse postictal suppression
Term/NA	1st day	Tonic head, conjugate eye, and mouth deviation, unilateral tonic abduction of the limbs, apnea, and desaturation	Sequential (tonic, autonomic)	KCNQ2 epileptic encephalopathy	Focal low-voltage fast activity followed by rhythmic theta rhythm from the fronto central region of both hemispheres, alternately followed by diffuse marked postictal suppression lasting up to 8 minutes
Term/NA	1st day	Tonic head, conjugate eye, and mouth deviation, unilateral tonic abduction of the limbs, apnea, and desaturation	Sequential (tonic, autonomic)	KCNQ2 epileptic encephalopathy	Low-voltage fast activity followed by focal theta rhythms involving the right or left hemisphere
Porri et al <i>Neuropediatrics</i> , 2014. N = 1/1					
Preterm/male	1st	Erratic myoclonic jerks involving all four extremities	Myoclonic	Pyridoxal-5'-Phosphate Oxidase Deficiency	Burst-suppression (ictal)
Khajeh et al <i>J Child Neurol</i> , 2014. N = 1/1					
Term/female	1st	Apnea	Autonomic	Polymicrogyria left temporal and frontal lobes	Left temporal 9-10 Hz activity, evolving into 2- to 3-Hz sharp and slow-wave activity
Weckhuysen et al <i>Neurology</i> , 2013. N = 11/11					
(NA)/female	1st	Tonic asymmetrical with apnea, bradycardia and desaturation, continuous complex movements of legs	Sequential (tonic, autonomic, clonic or automatisms)	KCNQ2 mutation	Burst-suppression <sup>a</sup>
(NA)/female	2nd	Apnea, erratic myoclonic and tonic contraction	Sequential (autonomic, myoclonic, tonic)	KCNQ2 mutation	Burst-suppression <sup>a</sup>
(NA)/male	2nd	Tonic generalized	Tonic	KCNQ2 mutation	Burst-suppression <sup>a</sup>
(NA)/male	1st	Tonic generalized with apnea, grimacing, followed by mastication and sialorrhea	Sequential (tonic, autonomic)	KCNQ2 mutation	Burst-suppression <sup>a</sup>

(Continues)

TABLE 1 (Continued)

GA/sex	Seizure onset (d)	Semiology (seizure description by author)	Seizure classification	Etiology	EEG
(NA)/male	2nd	Tonic with pursing of lips, clenching of eyes and cyanosis, sometimes eye deviation and flickering of eyeballs	Sequential (tonic, autonomic)	KCNQ2 mutation	Burst-suppression <sup>a</sup>
(NA)/female	2nd	Tonic asymmetrical with sucking movements of mouth	Sequential (tonic, autonomic)	KCNQ2 mutation	Burst-suppression <sup>a</sup>
(NA)/female	1st	Tonic asymmetrical with apnea	Tonic	KCNQ2 mutation	Multifocal
(NA)/male	1st	Tonic asymmetrical with apnea	Tonic	KCNQ2 mutation	Focal evolving to multifocal
(NA)/female	3rd	Tonic asymmetrical followed by hemiclonic	Sequential (tonic, clonic)	KCNQ2 mutation	Multifocal
(NA)/female	1st	Tonic generalized	Tonic	KCNQ2 mutation	Focal spike waves
(NA)/female	2nd	Tonic asymmetrical and apnea	Tonic	KCNQ2 mutation	Bilateral spikes
Borkenhagen et al <i>Pediatr Neurol</i> , 2013. N = 1/1 OK					
Term/female	5th	Clonic right foot, with subsequent multifocal clonic (arms and legs independently)	Clonic	Hypocalcemia	High-voltage, rhythmic spike-wave discharges, left vertex region with spread into the left posterior temporal, left parietal, and right parietal regions.
Serino et al <i>Epileptic Disord</i> , 2013. N = 1/1					
Term/male	3rd day	Focal, tonic seizures with head deviation, asynchronous and asymmetrical clonic jerks, eyelid myoclonias, and polypnea	Sequential (tonic, clonic)	KCNQ2 epileptic encephalopathy	Focal, low-voltage, fast activity, followed by recruiting theta rhythms and bilateral, focal, spike-wave complexes, alternately localized to one hemisphere and subsequently diffusing to the other
Mühl et al <i>Orphanet J Rare Dis</i> , 2013. N = 16/16					
Term/(NA)	1st	Clonic and tonic	Sequential (clonic, tonic)	KCNQ2 mutations	Burst-suppression <sup>a</sup>
Preterm/(NA)	15th	Myoclonic	Myoclonic	KCNQ2 mutations	Periods of flatness <sup>a</sup>
Term/(NA)	3rd	Tonic, pallor 2	Tonic	KCNQ2 mutations	Burst-suppression <sup>a</sup>
Term/(NA)	2nd	Tonic and hypotonic. Epileptic spasms	Sequential (tonic, epileptic spasms)	KCNQ2 mutations	Burst-suppression <sup>a</sup>
Term/(NA)	2nd	Tonic and tonic-clonic, cyanosis	Sequential (tonic, clonic, autonomic)	KCNQ2 mutations	Generalized spikes predominating on the left hemisphere followed by suppression burst. <sup>a</sup>
Term/(NA)	2nd	Left and right clonic jerks, facial cyanosis.	Clonic	KCNQ2 mutations	Burst-suppression <sup>a</sup>
Term/(NA)	1st	Isolated cyanosis, than recurrent hypertonic posture	Sequential (autonomic, tonic)	KCNQ2 mutations	Burst-suppression <sup>a</sup>
(NA)/(NA)	1st	Tonic asymmetric.	Tonic	KCNQ2 mutations	Bursts of multifocal spikes .

(Continues)



TABLE 1 (Continued)

GA/sex	Seizure onset (d)	Semiology (seizure description by author)	Seizure classification	Etiology	EEG
Term/(NA)	3rd	Tonic	Tonic	<i>KCNQ2</i> mutations	Burst-suppression <sup>a</sup>
Term/(NA)	1st	Tonic and/or clonic	Sequential (tonic, clonic)	<i>KCNQ2</i> mutations	Burst of asynchronous spikes and sharp waves. Periods of discontinuity with flatness no typical burst suppression
Term/(NA)	1st	Tonic and cyanosis	Tonic	<i>KCNQ2</i> mutations	Left or right spikes on a moderately abnormal background
Term/(NA)	4th	Asymmetric tonic extension of one limb. Bilateral clonic seizures. Apnea.	Sequential (tonic, clonic, autonomic)	<i>KCNQ2</i> mutations	Burst-suppression <sup>a</sup>
Term/(NA)	4th	Clonic hemi corporeal, left or right	Clonic	<i>KCNQ2</i> mutations	Prolonged periods of flatness. Discontinuous. <sup>a</sup>
Term/(NA)	1st	Tonic	Tonic	<i>KCNQ2</i> mutations	Multifocal slow waves, left frontal and right occipital spikes. Asymmetrical suppression-burst
Preterm/(NA)	8th	Myoclonic	Myoclonic	<i>KCNQ2</i> mutations	Burst-suppression <sup>a</sup>
Term/(NA)	2nd	Bilateral tonic clonic and right clonic	Sequential (tonic, clonic)	<i>KCNQ2</i> mutations	Slow waves with asynchronous bilateral spikes and intermittent flattening
Tanriverdi et al <i>Brain Dev</i> , 2013. N = 1/1					
Term/female	20th day	Focal seizures followed by generalization	Sequential (no specific description)	Sturge-Weber	Isolated sharp spike-wave discharges at parietal right hemisphere and at the frontotemporal areas of left hemisphere
Kato et al <i>Epilepsia</i> , 2013. N = 12/12					
(NA)/female	1st	Tonic, eye deviation	Tonic	<i>KCNQ2</i> mutation	Burst-suppression, asymmetric <sup>a</sup>
(NA)/male	3rd	Tonic	Tonic	<i>KCNQ2</i> mutation	Multifocal sharp waves
(NA)/male	5th	Left sided tonic	Tonic	<i>KCNQ2</i> mutation	Burst-suppression, brief suppression <sup>a</sup>
(NA)/female	2nd	Tonic	Tonic	<i>KCNQ2</i> mutation	Burst-suppression, asymmetric <sup>a</sup>
(NA)/male	1st	Tonic	Tonic	<i>KCNQ2</i> mutation	Burst-suppression, brief suppression <sup>a</sup>
(NA)/male	30th	Asymmetric tonic	Tonic	<i>KCNQ2</i> mutation	Burst-suppression <sup>a</sup>
(NA)/male	14th	Tonic	Tonic	<i>KCNQ2</i> mutation	Burst-suppression, asymmetric <sup>a</sup>
(NA)/male	2nd	Tonic	Tonic	<i>KCNQ2</i> mutation	Burst-suppression, brief suppression <sup>a</sup>
(NA)/female	2nd	Tonic	Tonic	<i>KCNQ2</i> mutation	Burst-suppression, like hypersarrhythmia <sup>a</sup>
(NA)/female	14th	Generalized tonic	Tonic	<i>KCNQ2</i> mutation	Burst-suppression, brief suppression <sup>a</sup>
(NA)/male	1st	Postural tonic	Tonic	<i>KCNQ2</i> mutation	Burst-suppression <sup>a</sup>
(NA)/female	3rd	Tonic, facial clonic	Sequential (tonic, clonic)	<i>KCNQ2</i> mutation	Burst-suppression, asymmetric <sup>a</sup>

(Continues)

**TABLE 1** (Continued)

GA/sex	Seizure onset (d)	Semiology (seizure description by author)	Seizure classification	Etiology	EEG
Simoneti et al <i>Epilepsia</i> , 2012. N = 2/2					
Term/female	1st	Unusual cry, wide opening of the eyes, flushing, and bulbar and head deviation to the right	Sequential (autonomic, tonic)	Duplication of the sodium channel gene cluster on 2q24 5.1	Right centrotemporal, also bicentral, slow, repetitive spike wave activity, followed by background slowing.
Term/female	3rd	Focal tonic, multifocal clonic seizures, starts with central cyanosis and head deviation	Sequential (autonomic, tonic, clonic)	Duplication of the sodium channel gene cluster on 2q24	Generalized suppression of the background activity, followed by sharp and slow waves, secondarily generalizing.
Riesgo et al <i>Neuropediatrics</i> , 2012. N = 3/3					
Preterm/male	10th	Apnea and desaturation	Autonomic	Undetermined	Focal rhythmic activity on the left temporal region.
Preterm/female	22nd	Apnea	Autonomic	Periventricular leukomalacia	Multifocal paroxysms occurred mainly in the right temporal region
Preterm/female	2nd	Apnea, clonic upper limbs	Sequential (autonomic, clonic)	Undetermined 7.0	Multifocal paroxysms and EEG seizures in both hemispheres mainly at left temporal region
Cusmai et al <i>Eur J Pediatr Neurol</i> , 2012. N = 3/3					
Term/female	2nd	Myoclonic seizures and epileptic tonic spasms.	Myoclonic	Nonketotic hyperglycinemia	Burst-suppression (background pattern)
Term/male	2nd	Myoclonic jerks and infantile spasms	Myoclonic	Nonketotic hyperglycinemia	Burst-suppression (background pattern)
Term/male	1st	Myoclonic jerks and tonic spasms	Myoclonic	Nonketotic hyperglycinemia	Burst-suppression (background pattern)
Vatta et al <i>J Child Neurol</i> , 2012. N = 1/1					
Term/male	14th day	Opening of the eyes followed by body stiffening and breathing difficulties, clonic right arm	Sequential (tonic, autonomic, clonic)	<i>STXBPI</i> mutation 5.3	Focal discharges, left central region, alpha/theta range
Weckhuysen et al <i>Ann Neurol</i> , 2012. N = 6/8					
(NA)/female	2nd day	Apnea, generalized stiffening with facial suffusion, followed by pallor and cyanosis	Sequential (autonomic, tonic)	KCNQ2 epileptic encephalopathy	Continuous multifocal and bilaterally synchronous epileptiform activity.
(NA)/female	3rd day	Stiffening, head and eye deviation and tonic posturing	Sequential (autonomic, tonic)	KCNQ2 epileptic encephalopathy	Centroparietal ictal rhythm evolving to high-voltage slowing (right-sided in 2 seizures and left-sided in 1)
(NA)/male	2nd day	Generalized tonic with clonic components, lip smacking, back arching, apnea	Sequential (tonic, clonic, automatism, autonomic)	KCNQ2 epileptic encephalopathy	Multifocal epileptic activity most frequently seen in left temporal and right frontal regions.
(NA)/female	3rd day	Tonic seizure, followed by myoclonic jerks and nystagmus	Sequential (tonic, myoclonic)	KCNQ2 epileptic encephalopathy	Burst-suppression <sup>a</sup>

(Continues)

TABLE 1 (Continued)

GA/sex	Seizure onset (d)	Semiology (seizure description by author)	Seizure classification	Etiology	EEG
(NA)/male	3rd day	Tonic extension with clonic movements left hemicorpus and eyelid myoclonia	Sequential (tonic, myoclonic)	KCNQ2 epileptic encephalopathy	Burst-suppression <sup>a</sup>
(NA)/female	2nd day	Tonic extension, high pitch cry, cyanosis and bradypnea, eventually with myoclonias (arms)	Sequential (tonic, myoclonic, autonomic)	KCNQ2 epileptic encephalopathy	Burst-suppression <sup>a</sup>
Blumkin et al <i>Eur J Pediatr Neurol</i> , 2012. N = 1/1					
Term/male	2nd	Multifocal clonic	Clonic	KCNQ2 mutation	Generalized spike and wave (2-2.5 Hz) with phase reversal in the rolandic area bilaterally.
Castro-Conde et al <i>Pediatrics</i> , 2012. N = 2/2					
Term/male	1st day	Eye opening, tachycardia, tonic eye deviation to the left, slow blinking, mouth movements, right arm abduction with clenched fist and eye deviation to the right followed by apnea	Sequential (autonomic, automatisms, tonic)	Ischemic stroke	Rhythmic sharp waves left temporal followed by generalized background suppression
Term/female					
2nd day	Apnea		Autonomic	Unknown	Focal occipital discharges
Hirata et al <i>Neuropediatrics</i> , 2011. N = 1/1					
Term/female	16th	Clonic seizures right arm and leg	Clonic	Coxsackie B2 Meningoencephalitis	Multifocal spikes
Milh et al <i>Epilepsia</i> , 2011. N = 4/5					
(NA)/(NA)	1st	Clonic asynchronous	Clonic	STXBPI (MUNC18-1) mutations	Burst-suppression <sup>a</sup>
(NA)/(NA)	1st	Clonic asynchronous	Clonic	STXBPI (MUNC18-1) mutations	Burst-suppression <sup>a</sup>
(NA)/(NA)	3rd	Epileptic spasms	Epileptic spasms	STXBPI (MUNC18-1) mutations	Burst-suppression <sup>a</sup>
(NA)/(NA)	1st	Epileptic spasms	Epileptic spasms	STXBPI (MUNC18-1) mutations	Burst-suppression <sup>a</sup>
Walsh et al <i>Dev Med Child Neurol</i> , 2011. N = 1/1					
Term/female	1st to 2nd day	Lip smacking and tonic-clonic	Sequential (automatisms, tonic, clonic)	Ischemic stroke	Bursts sharp waves left hemisphere
Millet et al <i>Eur J Pediatr Neurol</i> , 2011. N = 1/1					
Term/male	1st	Clonic	Clonic	Pyridoxine-dependent epilepsy with mutation in the <i>ALDH7A1</i> gene	Rhythmic spikes that predominated in the right or left hemisphere, in the temporal region. Burst-suppression background

(Continues)

TABLE 1 (Continued)

GA/sex	Seizure onset (d)	Semiology (seizure description by author)	Seizure classification	Etiology	EEG
Heron et al <i>Epilepsia</i> , 2010. N = 1/1 ok					
Term/male	4th day	Myoclonic	Myoclonic	QT prolongation mutation in SCN5A c.4868G>A (p.R1623Q)	Bilateral rhythmic epileptic discharges predominantly posterior (O1 and O2) with a right-sided emphasis.
Gibson & Bharti. <i>Temp Med</i> , 2010. N = 2/2 ok					
Term/female	1st	Focal clonic left leg	Clonic	Left MCA ischemic stroke	Rhythmic discharges left temporal spreading to frontal/central regions
Term/female	1st	Focal tonic clonic, smacking lips, tongue deviation	Sequential (tonic, clonic, automatism)	Right MCA ischemic stroke	Multifocal sharp waves
Schmitt et al <i>Dev Med Child Neurol</i> , 2010. N = 1/5 ok					
Term/female	7th	Focal clonic	Clonic	Pyridoxine-dependent epilepsy	Central spikes
Okumura et al <i>Brain Dev</i> , 2008. N = 3/9 ok					
Preterm/male	25th day	Autonomic 7	Autonomic	Severe hypotension hyperkalemia	Right temporal rhythmic slow voltage spikes
Preterm/female	1st day	Apnea	Autonomic	Neonatal encephalopathy	Rhythmic spikes, right temporal
Preterm/female	1st day	Apnea	Autonomic	Subarachnoid hemorrhage	Rhythmic spikes, left temporal
Nunes et al <i>Arq Neuropsiquiatr (São Paulo)</i> , 2008. N = 6/101					
Term/female	4th day	Clonic left arm, after left leg, chewing movements	Sequential (clonic, automatism)	Benign familial neonatal seizures	Rhythmic discharges theta range right central and temporal with propagation to left central
Term/male	1st day	Multifocal clonic	Clonic	Hypoxic-ischemic encephalopathy	Rhythmic spikes, right temporal and rolandic
Term/male	2nd day	Clonic left arm and face	Clonic	Abstinence	Rhythmic discharges, right occipital
Term/female	2nd day	Clonic focal left arm	Clonic	Right MCA ischemic infarct	Rhythmic spike and slow wave right rolandic, with propagation to right frontal
Term/female	2nd day	Apnea	Autonomic	Hypoxic-ischemic encephalopathy	Rhythmic discharges, left occipital
Term/female	1st day	Clonic focal right arm, blinking right eye	Clonic	Left MCA ischemic infarct	Rhythmic discharges, delta range, left rolandic
Kubota et al <i>Brain Dev</i> , 2008. N = 1/1ok					
Term/female	2nd day	Clonic left side, with open eyes deviating to the left, and automatism around the mouth	Sequential (clonic, tonic, automatism)	Hypoxic-ischemic encephalopathy	Semi-rhythmic, repetitive spikes predominantly in the right central region

(Continues)

TABLE 1 (Continued)

GA/sex	Seizure onset (d)	Semiology (seizure description by author)	Seizure classification	Etiology	EEG
Shah et al <i>N Engl J Med</i> , 2008. N = 1/1					
Term/female	1st	Apnea	Autonomic	Left MCA ischemic stroke	Sharp waves left temporal
Vecchi et al <i>Epileptic Dis</i> , 2007. N = 1/1					
Preterm/male	7th	Behavioral arrest, staring, apnea, deviation of the head and the eyes to the right, dystonic posture of the left hand and bilateral, automatic hand movements	Sequential (behavior arrest, autonomic, tonic)	Undetermined	Rapid rhythms of low voltage in the right temporal region followed by theta rhythmic activity and rhythmical sharp and wave complexes
Gorman & Soul. <i>Pediatr Neurol</i> , 2007. N = 1/1					
Term/male	3 rd	Tonic-clonic	Sequential (tonic, clonic)	Hypocalcemia	Left central and vertex sharp waves that spread to right side
Sirsi et al <i>Pediatr Neurol</i> , 2007. N = 3/3					
Term/male	1st	Apnea, conjugate eye deviation to the right, focal clonic (right-arm)	Sequential (autonomic, tonic, clonic)	Hemorrhage (left temporal lobe)	Left temporal sharp rhythmic delta activity, evolving into alpha with admixed theta sharp and slow-wave
Term/male	1st	Apnea	Autonomic	Intraparenchymal hemorrhage (right temporal) and subdural (right tentorium) hematoma	Focal activity (right hemisphere)
Term/male	1st day	Apnea	Autonomic	Right temporal hemorrhagic infarct	Right temporal rhythmic spike and wave activity
Lin et al <i>Arq Neuropsiquiatr (São Paulo)</i> , 2007. N = 1/1					
Term/female	1st	Focal myoclonic left arm and leg) tonic eye and head deviation to the right, eyelid blinking and oromandibular movements	Sequential (myoclonic, tonic, autonomic)	Pyridoxine-dependent epilepsy	High-voltage spike and polyspike-wave complexes lateralized to the right cerebral hemisphere
Hmaitess et al <i>Pediatr Neurol</i> , 2007. N = 1/1					
Term/male	1st	Lateral deviation of the head and eyes, fixed sight, clonic jerks on one side of the body followed by clonic jerks of the other side	Sequential (tonic, clonic)	Malignant migrating partial seizures (etiology unknown)	Low-voltage fast right central and occipital activity (9-10 Hz), anterior ipsilateral flattening, followed by increased amplitude and slowing to theta and delta rhythmic activity left side
Spinosa et al <i>Arq Neuropsiquiatr (São Paulo)</i> , 2006. N = 1/1					
Term/male	1st	Focal clonic (right hemiface and arm)	Clonic	X-linked lissencephaly with ambiguous genitalia (XLAG)	Right midtemporal, central and occipital discharges

(Continues)

**TABLE 1** (Continued)

GA/sex	Seizure onset (d)	Semiology (seizure description by author)	Seizure classification	Etiology	EEG
Cherian et al <i>Clin EEG Neurosci</i> , 2006. N = 1/1					
Term/(NA)	(NA)	Nystagmoid movements	Automatism	Hypoxic-ischemic encephalopathy	Focal bilateral occipital discharges
Schmitt et al <i>Epileptic Res</i> , 2005. N = 6/6					
Term/(NA)	1st day	Tonic followed by asymmetric clonic	Sequential (tonic, clonic)	Pyridoxine- dependent seizures	Bilateral synchronous spike-wave discharges followed by suppression
Term/(NA)	1st day	Multifocal myoclonic jerks, intermittent tonic posturing or spasms, eye deviations and abnormal oral and mimic movements	Sequential (myoclonic, tonic, epileptic spasms, automatism)	Pyridoxine- dependent seizures	Voltage suppression in EEG followed by bilateral synchronous spike-wave discharges
Term/female	1st day	Tonic clonic-myoclonic seizures	Sequential (tonic, clonic, myoclonic)	Undetermined	Rhythmic and sharp activity alternated from both hemispheres
Term/male	1st day	Tonic-clonic	Sequential (tonic, clonic)	KCNQ2	Voltage suppression, bilateral rhythmic alpha discharges
Term/female	1st day	Slow dystonic movements followed by focal clonic on right arm and leg	Sequential (tonic, clonic)	Undetermined	Voltage suppression rhythmic and sharp left hemisphere
Term/male	8th day	Tonic clonic	Sequential (tonic, clonic)	Undetermined	Multifocal
Al-Futaisi et al <i>Clin Neurophysiol</i> , 2005. N = 1/1					
Term/female	5 days	Tonic spasms	Epileptic spasms	EIEE (etiology unknown)	Burst-suppression (ictal)
Schulzke et al <i>J Perinatal Med</i> , 2005. N = 6/9					
Preterm/male	1st	Focal clonic	Clonic	Left MCA ischemic stroke	Focal left discharges
Term/male	1st	Apnea plus tonic and clonic	Sequential (autonomic, tonic, clonic)	Hemorrhage (left parietooccipital region)	Focal left discharges
Term/female	1st	Apnea plus tonic and clonic	Sequential (autonomic, tonic, clonic)	Left MCA ischemic stroke	PLEDS left
Term/female	2nd	Focal clonic	Clonic	Left MCA ischemic stroke	Focal left discharges
Term/male	3rd	Focal clonic	Clonic	Left MCA ischemic stroke	Focal left discharges and sharp/slow waves right
Term/female	2nd	Focal clonic	Clonic	Left MCA ischemic stroke	Focal left discharges
Tramonte & Goodkin. <i>J Perinatol</i> , 2004. N = 1/1					
Term/male	1st	Apnea	Autonomic	Intraparenchymal hemorrhage (right temporal)	Sharply contoured alpha activity evolving into periodic sharp and slow wave activity followed by rhythmic delta activity, right centrotemporal

AED, antiepileptic drug; EIEE, early infantile epileptic encephalopathy; GA, gestational age, seizure onset expressed in days of life; IVH, intraventricular hemorrhage; LMCA, left middle cerebral artery; N, number of patients included/number of patients available in the study; PLEDs, pseudoperiodic epileptiform discharges; RMCA, right middle cerebral artery; (NA), not available. In this table we have maintained the description of seizure semiology and EEG findings as it is cited in the original article.

\*Indicates when burst-suppression was not clearly defined as ictal or interictal pattern/background abnormality.

### 3 | RESULTS

Figure 1 demonstrates the steps of the systematic review and inclusion of the articles. From the initial search, there were 8507 titles. After applying filters (period 2004-2016, human studies, English language), the number decreased to 2910. After reviewing the titles and abstracts, we excluded review articles, editorial letters, and expert opinions. This left 177 full-text articles. Of these, 117 articles were excluded for the following reasons: there was no individual semiology description of the seizures; seizures did not occur during the neonatal period, or there were only descriptions of interictal EEG or no neonatal EEG description at all; and finally, there was no clinical-EEG correlation. Three articles were not available online. We therefore identified 57 articles that provided data to correlate the EEG patterns with clinical semiology of seizures and the description of the etiologic diagnosis (Table 1).

Although these studies included data on 282 neonates, several cases were duplicates or information was not available to compare individual semiology vs etiology vs EEG. Thus, 151 neonates were included in the final analysis. In each study, the number of patients included varied from 1 to 16 (median 1, mean  $\pm$  standard deviation [SD]  $2.78 \pm 3.20$ ).

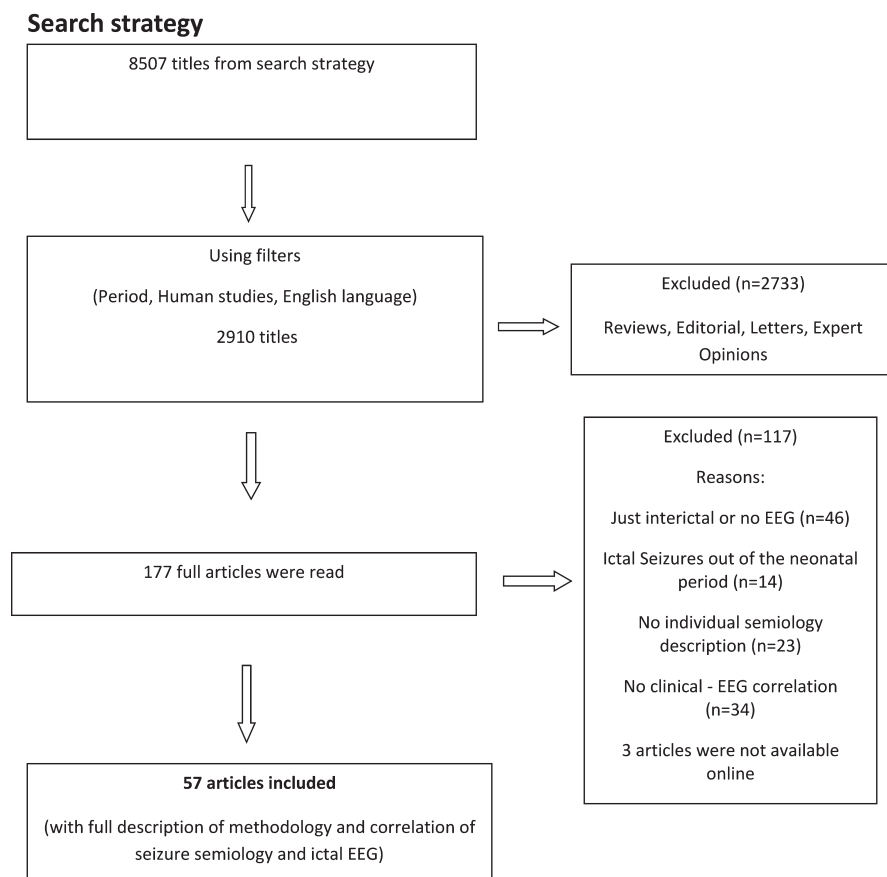
Of the neonates included, 37.7% were male and 45.0% female; 62.9% were born at term. Information regarding sex or

gestational age was not available in 17.2% and 24.5% of the cases, respectively. Table 2 summarizes the semiology, etiology, and EEG findings.

#### 3.1 | Etiology and seizure type

A genetic etiology was most frequently described among the cases included in this study (51.0%). This was followed by vascular (21.9%) and metabolic/vitamin-related disorders (12.6%). In the genetic group, the most prevalent seizure type was sequential, described in 48.0% of the cases, followed by tonic seizures (33.7%; Table 3). It should be noted that a tonic component was reported in many sequential seizures, irrespective of the etiology. However, it was more frequently reported in genetic etiologies (64.2% of the cases;  $P = 0.019$ ); it was reported in 12.5% of metabolic/vitamin-related disorders, in 10.7% of vascular cases, in 8.93% of seizures of unknown etiology, in 1.7% of HIE, and in 1.7% of cortical malformations. For the vascular etiology, the predominant seizure type was clonic (60.6%). For metabolic/vitamin-related disorders, we found sequential seizures in 42.1% of the cases, followed by myoclonic in 31.5%.

Analysis of the relationship between seizure semiology and etiology revealed that sequential seizures occurred with all etiologies as shown in Table 3. Some seizure types significantly correlated with specific etiologies: infection



**FIGURE 1** Search strategy

**TABLE 2** General characteristics of the 151 included neonates

Sex <sup>a</sup> (n = 125)	Male 37.7%	Female 45.0%	Missing 17.2%
Gestational age <sup>a</sup> (n = 114)	Term 62.9%	Preterm 12.6%	Missing 24.5%
N (%)			
Etiology (n = 151)			
Hypoxic-ischemic encephalopathy			6 (4.0)
Cortical malformations			3 (2.0)
CNS infections			4 (2.6)
Metabolic disorders			
Electrolyte imbalance			3 (2.0)
Inborn errors of metabolism			3 (2.0)
Vitamin-related disorders			11 (7.3)
Withdrawal seizures			2 (1.3)
Genetics			
Channelopathies			67 (44.4)
Chromosomal disorders			3 (2.0)
Other gene disorders			7 (4.6)
Vascular			
Stroke			25 (16.6)
Hemorrhage			8 (5.3)
Undetermined/unknown			9 (6.0)
Seizure type (n = 151)			
Sequential			62 (41.1)
Clonic			36 (23.8)
Tonic			26 (17.2)
Autonomic			14 (9.3)
Myoclonic			9 (6.0)
Spasms			3 (2.0)
Automatisms			1 (0.7)
EEG (n = 151) <sup>b</sup>			
Focal			56 (37.1)
Burst-suppression			48 (31.8)
Multifocal			46 (30.5)
Generalized			1 (0.7)

<sup>a</sup>Information not available for all newborns.

<sup>b</sup>Information related to ictal EEG except in some cases of burst-suppression (BS). Burst-suppression was described as an ictal pattern in 2 neonates and as an interictal in 8; in the remaining cases, it was not clearly defined as an ictal or interictal pattern/background abnormality.

and genetic disorders with clonic seizures ( $P = 0.042$  and  $P < 0.001$ ), metabolic/vitamin-related disorders with myoclonic seizures ( $P < 0.001$ ), and vascular with sequential seizures ( $P = 0.009$ ). When specific etiologies were analyzed among the groups, certain etiologies were significantly associated with specific seizure types: hemorrhage with autonomic seizures ( $P = 0.003$ ), stroke with clonic seizures

( $P < 0.001$ ), and inborn errors of metabolism with myoclonic seizures ( $P < 0.001$ ).

### 3.2 | Etiology and EEG features

Certain etiologies were clearly related to specific EEG patterns. Focal ictal discharges were more prevalent in vascular etiologies (87.8%,  $P < 0.001$ ), and burst-suppression in genetic cases (51.9%,  $P < 0.001$ ). Among the groups of etiologies, some specific disorders were also significantly correlated with ictal EEG patterns, such as electrolyte imbalance and focal discharges (100%,  $P = 0.049$ ), vitamin deficiency and multifocal (63.3%,  $P = 0.035$ ), and channelopathies and inborn errors of metabolism with burst-suppression (50.7%,  $P < 0.001$ ; and 100%,  $P < 0.001$ , respectively). Specific etiologies where the burst-suppression pattern was described either as an ictal or interictal pattern are shown in Table 4.

### 3.3 | Seizure type and EEG features

The predominant seizure type was sequential (41.1%), and the predominant EEG abnormality described was focal discharges (37.1%).

The frequency of each seizure type and related EEG features is presented in Table 5. Clonic seizures were mostly associated with focal ictal EEG abnormalities (61.1%,  $P = 0.001$ ), and tonic and myoclonic seizures were associated with burst-suppression (57.7%,  $P = 0.005$ ; and 77.8%,  $P = 0.005$ ). Autonomic seizures were also associated with focal EEG discharges in 85.7% of the cases ( $P < 0.001$ ). The single case of automatisms was associated with a focal EEG discharge, and the 2 cases of epileptic spasms had a burst-suppression pattern. Sequential seizures were equally associated with different EEG patterns (25.8% with focal, 45.2% with multifocal discharges, and 29.0% with burst-suppression).

### 3.4 | Emerging associations based on the report of etiology-specific electroclinical features of neonatal seizures

We were able to establish some associations based on data acquired from this systematic review.

Some etiologies, generally related to acute events, were associated with specific clinical features and ictal EEG alterations, for example, 72% of the 25 patients with stroke had clonic seizures and 88% focal EEG; of the 4 patients with CNS infection, 3 had clonic seizures and multifocal EEG (75%).

Genetic and metabolic/vitamin-related etiologies could also be associated with specific electroclinical features. The 3 cases of inborn errors of metabolism had myoclonic seizures and a burst-suppression pattern described in all the patients. From the 11 patients with vitamin deficiency,



**TABLE 3** Seizures etiology × semiology

	Clonic	Tonic	Myoclonic	Automatisms	Spasms	Sequential	Autonomic
Etiology/seizure classification, n (%)							
HIE (n = 6)	1 (16.7%)	0 (0.0%)	0 (0.0%)	1 (16.7%)	0 (0.0%)	1 (16.7%)	3 (50.0%)
Cortical malformations (n = 3)	0 (0.0%)	0 (0.0%)	0 (0.0%)	0 (0.0%)	0 (0.0%)	2 (66.7%)	1 (33.3%)
CNS infection (n = 4)	3 (75.0%)	0 (0.0%)	0 (0.0%)	0 (0.0%)	0 (0.0%)	1 (25.0%)	0 (0.0%)
Metabolic disorders							
Electrolyte imbalance (n = 3)	1 (33.3%)	0 (0.0%)	0 (0.0%)	0 (0.0%)	0 (0.0%)	1 (33.3%)	1 (33.3%)
Inborn errors of metabolism (n = 3)	0 (0.0%)	0 (0.0%)	3 (100%)	0 (0.0%)	0 (0.0%)	0 (0.0%)	0 (0.0%)
Vitamin-related disorders (n = 11)	2 (18.2%)	0 (0.0%)	2 (18.2%)	0 (0.0%)	0 (0.0%)	7 (63.6%)	0 (0.0%)
Withdrawal (n = 2)	1 (50.0%)	0 (0.0%)	1 (50.0%)	0 (0.0%)	0 (0.0%)	0 (0.0%)	0 (0.0%)
Genetic disorders							
Channelopathy (n = 67)	5 (7.5%)	26 (38.8%)	3 (4.5%)	0 (0.0%)	0 (0.0%)	33 (49.3%)	0 (0.0%)
Chromosomal disorder (n = 3)	1 (33.3%)	0 (0.0%)	0 (0.0%)	0 (0.0%)	0 (0.0%)	1 (33.3%)	1 (33.3%)
Other gene disorders (n = 7)	2 (28.6%)	0 (0.0%)	0 (0.0%)	0 (0.0%)	2 (28.6%)	3 (42.9%)	0 (0.0%)
Vascular disorders							
Stroke (n = 25)	18 (72.0%)	0 (0.0%)	0 (0.0%)	0 (0.0%)	0 (0.0%)	5 (20.0%)	2 (8.0%)
Hemorrhage (n = 8)	2 (25.0%)	0 (0.0%)	0 (0.0%)	0 (0.0%)	0 (0.0%)	2 (25.0%)	4 (50.0%)
Unknown Undetermined/ (n = 9)	0 (0.0%)	0 (0.0%)	0 (0.0%)	0 (0.0%)	1 (11.1%)	6 (66.7%)	2 (22.2%)

CNS, central nervous system.

7 (63.6%) had sequential seizures and multifocal EEG findings. Among the 67 patients diagnosed with channelopathies, 88.0% presented either tonic or sequential seizures (involving a tonic component), 83.5% had a multifocal or burst-suppression EEG, and 60 patients had mutations of the *KCNQ2* gene. An analysis of this population showed specific combinations of semiology and EEG features: 25.0% had tonic seizures associated to burst-suppression, 21.7% had sequential seizures with burst-suppression, 20.0% had sequential seizures with a multifocal EEG, and 13.3% had tonic seizures and a multifocal EEG.

## 4 | DISCUSSION

This systematic review aimed to establish a relationship between electroclinical features and etiology of neonatal seizures using existing studies published in the literature. The contribution of the present study to the extensive literature in this subject is the methodology applied. We have grouped the data of all the neonates from different authors and analyzed it as a large cohort, including specific information for each neonate. The observed associations may have a direct effect

on clinical practice, mainly in institutions where continuous video-EEG is not available or not obtainable at all times.

Continuous video-EEG monitoring is essential for the accurate diagnosis of neonatal seizures. Previous studies have demonstrated that the extent of subclinical/electrographic seizures in neonates that can be missed in over 65% of seizures with only clinical detection.<sup>11,14,23,24</sup> However, in many countries and in population-based studies, this technique is not readily available in all neonatal units.<sup>6-9</sup> We agree with previous reports that it is often difficult to accurately differentiate between seizure-related and nonseizure movements in infants using clinical evaluation alone.<sup>11,14,23,24</sup> However, the combination of etiology, semiology, and EEG findings that we present in this review could help in classifying seizures in neonates.

We have observed that certain etiologies have a significant correlation with semiology (eg, stroke and CNS infection with clonic seizures, hemorrhage with autonomic seizures, inborn errors of metabolism, and the whole group of metabolic/vitamin-related disorders with myoclonic seizures, channelopathies, and sequential or tonic seizures).

In contrast to previous studies of neonatal seizures where the predominant etiology was HIE,<sup>5,6,8,9,25,26</sup> we have observed an atypical distribution of etiologies, as the majority

**TABLE 4** Etiology vs EEG

	EEG n (%)			
	Focal	Multifocal	Burst-suppression	Generalized
Etiology (n)				
Hypoxic-ischemic encephalopathy (n = 6)	4 (66.7%)	2 (33.3%)	0 (0.0%)	0 (0.0%)
Cortical malformations (n = 3)	2 (66.7%)	1 (33.3%)	0 (0.0%)	0 (0.0%)
CNS infection (n = 4)	1 (25.0%)	3 (75.0%)	0 (0.0%)	0 (0.0%)
Metabolic/vitamins disorders (n = 19)				
Electrolyte imbalance (n = 3)	3 (100%)	0 (0.0%)	0 (0.0%)	0 (0.0%)
Inborn errors of metabolism (n = 3)	0 (0.0%)	0 (0.0%)	3 (100%)**	0 (0.0%)
Vitamin-related disorders (n = 11)	1 (9.1%)	7 (63.6%)	3 (27.3%)*	0 (0.0%)
Withdrawal (n = 2)	2 (100%)	0 (0.0%)	0 (0.0%)	0 (0.0%)
Genetic disorders				
Channelopathies (n = 67)	10 (14.9%)	22 (32.8%)	34 (50.7%)	1 (1.5%)
Chromosomal disorder (n = 3)	0 (0.0%)	3 (100%)	0 (0.0%)	0 (0.0%)
Other gene disorders (n = 7)	1 (14.3%)	0 (0.0%)	6 (85.7%)**	0 (0.0%)
Vascular disorders				
Stroke (n = 25)	22 (88.0%)	2 (8.0%)	1 (4.0%)	0 (0.0%)
Hemorrhage (n = 8)	7 (87.5%)	1 (12.5%)	0 (0.0%)	0 (0.0%)
Undetermined/unknown (n = 9)	3 (33.3%)	5 (55.6%)	1 (11.1%)*	0 (0.0%)

CNS, central nervous system. Burst-suppression was described as an ictal pattern \*in 2 neonates (one with vitamin-related disorder and one with unknown etiology) and as an interictal pattern \*\*in eight (3 with inborn errors of metabolism, 3 with other gene disorders, and 2 with vitamin-related disorders); in the remaining cases, it was not clearly defined as an ictal or interictal pattern/background abnormality.

of cases with complete description of seizure semiology and EEG findings were related to a genetic etiology (either channelopathies or other gene disorders). This is likely due to a reporting bias, as a large number of case reports of genetic syndromes have appeared in the literature in the last few years. However, it is important to note that over the past several decades, the reported etiologies of neonatal seizures have significantly changed and that some etiologies (eg, hypocalcemia and other electrolytes imbalances)<sup>27–29</sup> have decreased due to improved neonatal care. At the same time, the improvement and availability of genetic testing has led to more investigation of genetic etiologies of seizures and epilepsies in the neonate. This increased interest has led authors to focus their publications on the detailed description of these syndromes.<sup>30–41</sup> In a recent paper, Shellhaas and collaborators reported the findings from “The National Seizure Registry” of 611 newborns. They observed a predominance of acute-onset seizures (87.0%) in comparison to neonatal-onset epilepsy. In those newborns epilepsy (n = 79), 46.8% had a genetic etiology and only 3.7% had HIE as a comorbidity.<sup>42</sup>

Because *KCNQ2* mutations were the single most common cause of neonatal seizures identified in this review, we were able to confirm an electroclinical pattern highly suggestive of this diagnosis: sequential seizures (with a tonic

component) or exclusively tonic seizures associated with a burst-suppression or a multifocal EEG.

The seizure semiology description in the articles reviewed herein did not necessarily follow any of the previously proposed classifications.<sup>1,5</sup> Some authors simply described the observed motor phenomena in their own words and this made data comparison difficult to achieve. The Task Force on Neonatal Seizures, established by the ILAE in 2014, aimed to integrate current concepts in neonatal seizures and epilepsies into the 2017 ILAE Classification of Seizures and Epilepsies,<sup>17,18</sup> with a modification of this scheme, adapted to neonatal particularities. Widespread use of this proposal might be helpful for collecting data in future studies.

Some limitations of this study were related to issues of reliance on the quality of reported studies, unclear or incomplete description of seizure semiology, and inconsistent methods of reading and reporting EEG patterns. Many authors have used the term burst-suppression to describe their EEG data without specifying if this pattern was consistent throughout the recording (and thus indicative of severe encephalopathy) or only during the motor seizure resembling an electrodecremental response. Future studies are needed to accurately describe the semiology of seizures that may be associated with an electrodecremental response or ictal burst-attenuation. In addition, some authors did not specify the background activity or clearly

TABLE 5 Seizure semiology x EEG

Seizure semiology/EEG	Focal	Multifocal	Generalized	Burst-suppression
Clonic (n = 36)	22 (61.1%)	8 (22.2%)	1 (2.8%)	5 (13.9%)
Tonic (n = 26)	3 (11.5%)	8 (30.8%)	0 (0.0%)	15 (57.7%)
Myoclonic (n = 9)	2 (22.2%)	0 (0.0%)	0 (0.0%)	7 (77.8%)***
Automatisms (n = 1)	1 (100%)	0 (0.0%)	0 (0.0%)	0 (0.0%)
Spasms (n = 3)	0 (0.0%)	0 (0.0%)	0 (0.0%)	3 (100%)*
Sequential (n = 62)	16 (25.8%)	28 (45.2%)	0 (0.0%)	18 (29.0%)**
Autonomic (n = 14)	12 (85.7%)	2 (14.3%)	0 (0.0%)	0 (0.0%)

Burst-suppression was described as an ictal pattern\* in one neonate with myoclonic seizures and in one with spasms; as an interictal pattern\*\* in 4 with myoclonic and four with sequential seizures; for the others it was not clearly defined as ictal or interictal pattern/background abnormality.

differentiate ictal from interictal findings. We would recommend that a standardized reporting system for EEG studies, including description of the background activity, focality, as well as ictal and interictal patterns, be described to improve such systematic reviews. Due to the small percentage of preterm neonates in the sample, our findings might be more consistent for term neonates. Another limitation was that we were unable to develop a proportional meta-analysis, since many of the studies reported fewer than 3 patients. Because of this, we had to group all neonates, as they belonged to one single study.<sup>19</sup> On the other hand, this limitation gave us the opportunity to analyze all the data together as a large cohort.

Finally, due to reporting bias in the literature, we were not able to find papers describing electroclinical patterns for the most prevalent etiology of neonatal seizures, HIE, or any specific patterns characteristic for preterm neonates.

Recommendations for future studies may include the publication of complete clinical data of the neonates (including sex and gestational age) using a systematic approach to describe EEG findings and a consistent classification of neonatal seizures, using, for example, the proposed classification of neonatal seizures referenced by the ILAE Task Force<sup>17</sup> when approved by the ILAE.

In conclusion, specific combinations of etiology, semiology, and EEG findings of neonatal seizures may be beneficial for an empirical approach to neonatal seizures. In this systematic review, we have shown that some etiologies have a specific correlation with semiology and ictal EEG patterns. These patterns may be helpful in making treatment decisions in countries with limited resources.

## DISCLOSURE OF CONFLICTS OF INTEREST

Magda L Nunes was supported by CNPq-Brazil, PQ grant 306338/2017-3. Solomon L. Moshé was funded by grants from NIH U54NS100064 and NS43209, and from the Heffer Family, the Segal Family Foundations, and the Abbe

Goldstein/Joshua Lurie and Laurie March/Dan Levitz families. Serves as an associate editor of *Neurobiology of Disease* and is on the editorial boards of *Brain and Development*, *Pediatric Neurology*, and *Physiological Research*. He receives from Elsevier an annual compensation for his work as associate editor of *Neurobiology of Disease* and royalties from books he coedited. He received a consultant fee from Mallinckrodt and UCB and is a member of a UCB Data Safety Monitoring Board (for work unrelated to this publication). Ronit M Pressler receives consultant fees from UCB (for work unrelated to this publication). The remaining authors have no conflicts of interest to declare. We confirm that we have read the Journal's position on issues involved in ethical publication and affirm that this report is consistent with those guidelines.

## REFERENCES

- Mizrahi EM, Kellaway P. Characterization and classification of neonatal seizures. *Neurology*. 1987;37:1837–44.
- Mizrahi EM. Neonatal seizures: problems in diagnosis and classification. *Epilepsia*. 1987;28(suppl 1):S46–55.
- WHO. Guidelines on neonatal seizures. Geneva, Switzerland: World Health Organization; 2011.
- Scher MS. Controversies regarding neonatal seizure recognition. *Epileptic Disord*. 2002;4:139–58.
- Tekgul H, Gauvreau K, Soul J, et al. The current etiologic profile and neurodevelopmental outcome of seizures in term newborn infants. *Pediatrics*. 2006;117:1270–80.
- Garcias Da Silva LF, Nunes ML, da Costa JC. Risk factors for developing epilepsy after neonatal seizures. *Pediatr Neurol*. 2004;30:271–7.
- Ronen GM, Buckley D, Penney S, Streiner DL. Long-term prognosis in children with neonatal seizures: a population-based study. *Neurology*. 2007;69:1816–22.
- Kumar A, Gupta A, Talukdar B. Clinico-etiological and EEG profile of neonatal seizures. *Indian J Pediatr*. 2007;74:33–7.
- Holanda MR, Melo AN. Comparative clinical study of preterm and full-term newborn neonatal seizures. *Arq Neuropsiquiatr*. 2006;64:45–50.
- Pisani F, Piccolo B, Cantalupo G, et al. Neonatal seizures and postneonatal epilepsy: a 7-y follow-up study. *Pediatr Res*. 2012;72:186–93.

11. Nagarajan L, Palumbo L, Ghosh S. Classification of clinical semiology in epileptic seizures in neonates. *Eur J Paediatr Neurol*. 2012;16:118–25.
12. Nagarajan L, Ghosh S, Palumbo L. Ictal electroencephalograms in neonatal seizures: characteristics and associations. *Pediatr Neurol*. 2011;45:11–6.
13. Pisani F, Barilli AL, Sisti L, et al. Preterm infants with video-EEG confirmed seizures: outcome at 30 months of age. *Brain Dev*. 2008;30:20–30.
14. Pisani F, Copioli C, Gioia CD, et al. Neonatal seizures: relation of ictal video-encephalography (EEG) findings with neurodevelopmental outcome. *J Child Neurol*. 2008;23:394–8.
15. Volpe JJ. Neonatal seizures: current concepts and revised classification. *Pediatrics*. 1989;84:422–8.
16. Scheffer IE, Berkovic S, Capovilla G, et al. ILAE classification of the epilepsies: position paper of the ILAE Commission for Classification and Terminology. *Epilepsia*. 2017;58:512–21.
17. Report of ILAE task Force on Neonatal Seizures [Cited 2018 Dec 10]. Available from <https://www.ilae.org/guidelines/definition-and-classification/neonatal-seizure-classification>
18. Fisher RS, Cross JH, D'Souza C, et al. Instruction manual for the ILAE 2017 operational classification of seizure types. *Epilepsia*. 2017;58:531–42.
19. Moher D, Liberati A, Tetzlaff J, et al. Reprint-Preferred reporting items for systematic reviews and meta-analyses: the PRISMA statement. *Phys Ther*. 2009;89:873–80.
20. Liberati A, Altman DG, Tetzlaff J, et al. The PRISMA statement for reporting systematic reviews and meta-analyses of studies that evaluate healthcare interventions: explanation and elaboration. *BMJ*. 2009;339:b2700.
21. Shea BJ, Grimshaw JM, Wells GA, et al. Development of AMSTAR: a measurement tool to assess the methodological quality of systematic reviews. *BMC Med Res Methodol*. 2007;7:1–7.
22. Kelley GA, Kelley KS. Statistical models for meta-analysis: a brief tutorial. *World J Methodol*. 2012;2:27–32.
23. Murray DM, Boylan GB, Ali I, et al. Defining the gap between electrographic seizure burden, clinical expression and staff recognition of neonatal seizures. *Arch Dis Child Fetal Neonatal Ed*. 2008;93:F187–91.
24. Malone A, Ryan CA, Fitzgerald A, et al. Interobserver agreement in neonatal seizure identification. *Epilepsia*. 2009;50:2097–101.
25. Ronen GM, Penney S, Andrews W. The epidemiology of clinical neonatal seizures in Newfoundland: a population-based study. *J Pediatr*. 1999;134:71–5.
26. Gebremariam A, Gutema Y, Leuel A, et al. Early-onset neonatal seizures: types, risk factors and short-term outcome. *Ann Trop Paediatr*. 2006;26:127–31.
27. Borkenhagen JF, Conner EL, Stafstrom CE. Neonatal hypocalcemic seizures due to excessive maternal calcium ingestion. *Pediatr Neurol*. 2013;48:469–71.
28. Okumura A, Hayakawa F, Kato T, et al. Ictal electroencephalographic findings of neonatal seizures in preterm infants. *Brain Dev*. 2008;30:261–8.
29. Gorman MP, Soul JS. Neonatal hypocalcemic seizures in siblings exposed to topiramate in utero. *Pediatr Neurol*. 2007;36:274–6.
30. Pisano T, Numis AL, Heavin SB, et al. Early and effective treatment of KCNQ2 encephalopathy. *Epilepsia*. 2015;56:685–91.
31. Saitu H, Yamashita S, Tanaka Y, et al. Compound heterozygous BRAT1 mutations cause familial Ohtahara syndrome with hypertonia and microcephaly. *J Hum Genet*. 2014;59:687–90.
32. Zerem A, Lev D, Blumkin L, et al. Paternal germline mosaicism of a SCN2A mutation results in Ohtahara syndrome in half siblings. *Eur J Paediatr Neurol*. 2014;18:567–71.
33. Numis AL, Angriman M, Sullivan JE, et al. KCNQ2 encephalopathy: delineation of the electroclinical phenotype and treatment response. *Neurology*. 2014;82:368–70.
34. Weckhuysen S, Ivanovic V, Hendrickx R, et al. Extending the KCNQ2 encephalopathy spectrum: clinical and neuroimaging findings in 17 patients. *Neurology*. 2013;81:1697–703.
35. Serino D, Specchio N, Pontrelli G, et al. Video/EEG findings in a KCNQ2 epileptic encephalopathy: a case report and revision of literature data. *Epileptic Disord*. 2013;15:158–65.
36. Muhl M, Boutry-Kryza N, Sutura-Sardo J, et al. Similar early characteristics but variable neurological outcome of patients with a de novo mutation of KCNQ2. *Orphanet J Rare Dis*. 2013;8:2–8.
37. Allen NM, Mannion M, Conroy J, et al. The variable phenotypes of KCNQ-related epilepsy. *Epilepsia*. 2014;55:e99–105.
38. Kato M, Yamagata T, Kubota M, et al. Clinical spectrum of early onset epileptic encephalopathies caused by KCNQ2 mutation. *Epilepsia*. 2013;54:1282–7.
39. Vatta M, Tennison MB, Aylsworth AS, et al. A novel STXBPI mutation causes focal seizures with neonatal onset. *J Child Neurol*. 2012;27:811–4.
40. Weckhuysen S, Mandelstam S, Suls A, et al. KCNQ2 encephalopathy: emerging phenotype of a neonatal epileptic encephalopathy. *Ann Neurol*. 2012;71:15–25.
41. Blumkin L, Suls A, Deconinck T, et al. Neonatal seizures associated with a severe neonatal myoclonus like dyskinesia due to a familial KCNQ2 gene mutation. *Eur J Paediatr Neurol*. 2012;16:356–60.
42. Shellhaas RA, Wusthoff CJ, Tsuchida TN, et al. Profile of neonatal epilepsies. Characteristics of a prospective US cohort. *Neurology*. 2017;89:893–9.

**How to cite this article:** Nunes ML, Yozawitz EG, Zuberi S, et al. Neonatal seizures: Is there a relationship between ictal electroclinical features and etiology? A critical appraisal based on a systematic literature review. *Epilepsia Open*. 2019;4:10–29. <https://doi.org/10.1002/epi4.12298>