

See discussions, stats, and author profiles for this publication at: <https://www.researchgate.net/publication/326569685>

Conservative Orthodontic Retreatment in a Patient with Class III Malocclusion and Root Resorption in Maxillary Teeth

Article · September 2019

DOI: 10.5005/jp-journals-10031-1261

CITATIONS

0

READS

139

4 authors, including:



Tatiana Siqueira Gonçalves

Pontificia Universidade Católica do Rio Grande do Sul

30 PUBLICATIONS 201 CITATIONS

[SEE PROFILE](#)



Bruno Nehme Barbo

Pontificia Universidade Católica do Rio Grande do Sul

5 PUBLICATIONS 3 CITATIONS

[SEE PROFILE](#)



Eduardo Martinelli Santayana de Lima

Pontificia Universidade Católica do Rio Grande do Sul

142 PUBLICATIONS 617 CITATIONS

[SEE PROFILE](#)

Some of the authors of this publication are also working on these related projects:



Class II treatment [View project](#)



Clinical Cases [View project](#)

CASE REPORT

Conservative Orthodontic Retreatment in a Patient with Class III Malocclusion and Root Resorption in Maxillary Teeth

Vanessa KS Schenck¹, Tatiana S Gonçalves², Bruno N Barbo³, Eduardo M de Lima⁴

ABSTRACT

Aim: To report a conservative orthodontic retreatment in a 23-year-old woman with class III malocclusion and root resorption in maxillary teeth.

Background case description: The patient was diagnosed with angle class III subdivision malocclusion with edge-to-edge incisor bite and mild crowding of the lower anterior teeth. Treatment consisted of the use of miniplates as skeletal anchorage for distalization of mandibular teeth and no intervention in the maxilla. At debonding, the patient showed attractive dentofacial esthetics and a functional occlusion. Class I canine and molar relationship was obtained, with normal overjet and overbite. Cephalometric analysis demonstrated a retraction of the mandibular incisors and a distalization of the mandibular first molars (3 mm). One-year follow-up records exhibited stability of the treatment outcomes in the short term.

Conclusion: Conservative orthodontic retreatment of a class III malocclusion associated with severe resorption of maxillary incisors was accomplished successfully using miniplates in the mandible and no appliance in the maxilla.

Keywords: Class III malocclusion, Miniplates, Orthodontic retreatment.

Journal of Contemporary Dentistry (2019): 10.5005/jp-journals-10031-1261

BACKGROUND

Root resorption is a possible and undesirable effect of the orthodontic treatment. Risks of root resorption have been related to root morphology, previous trauma, dental anomalies, malocclusion type, patient age, gender, and long treatment time with fixed appliances. Superficial root resorption is present in most orthodontic patients. However, severe root resorption is a clear limitation when orthodontic retreatment is necessary.^{1,2}

Orthodontic retreatment is challenging in cases with root resorption because of the risks of additional damage to the teeth. Moreover, a second intervention may leave the patient unsure about the treatment outcomes.³⁻⁵ Usually, retreatment objectives are easier to accomplish with the aid of temporary anchorage devices, (TADs) which discharge dental anchorage, reducing risks and maximizing benefits in the shorter time. For instance, TADs allow distalization and intrusion of mandibular molars, which is hard to achieve with traditional mechanics.^{6,7} In mild class III malocclusions, TADs can eliminate the need for tooth extractions or orthognathic surgery.^{8,9}

This case report describes a conservative orthodontic retreatment in a 23-year-old woman with class III malocclusion and root resorption in the maxillary teeth. Bilateral miniplates provided skeletal anchorage for distalization of the mandibular teeth. No treatment was performed in the maxilla, in order to prevent additional damage to maxillary incisors.

CASE DESCRIPTION

Diagnosis and Etiology

A 23-year-old woman came to the Department of Orthodontics of the Pontifical Catholic University of Rio Grande do Sul (PUCRS), Brazil, with the primary complaint of orthodontic relapse. She had undergone orthodontic treatment for 6 years in an attempt to correct a class III malocclusion. She had a straight profile, slightly protruded lower lip, and no facial asymmetry. Intraoral examination revealed a class III canine and molar relationship on the right side,

¹⁻⁴Department of Orthodontics, Pontifícia Universidade Católica do Rio Grande do Sul, Porto Alegre, Rio Grande do Sul, Brazil

Corresponding Author: Vanessa KS Schenck, Department of Orthodontics, Pontifícia Universidade Católica do Rio Grande do Sul, Porto Alegre, Rio Grande do Sul, Brazil, Phone: +1 515 865 9717, e-mail: vakern@gmail.com

How to cite this article: Schenck VKS, Gonçalves TS, Barbo BN, et al. Conservative Orthodontic Retreatment in a Patient with Class III Malocclusion and Root Resorption in Maxillary Teeth. *J Contemp Dent* 2019;XX(X):1-6.

Source of support: This study was financed in part by the Coordenação de Aperfeiçoamento de Pessoal de Nível Superior- Brasil (CAPES)- Finance Code 001

Conflict of interest: None

class I on the left side, and the incisors having an edge-to-edge bite. The dental midline was deviated 1.5 mm to the right side in the maxilla and 2 mm to the left side in the mandible. Arch length discrepancy was -3 mm in the mandible (Figs 1 and 2). Functional evaluation indicated coincidence of centric occlusion in centric relation and no canine contact during lateral excursions of the mandible.

Panoramic and periapical radiographs revealed extensive root resorption in the maxillary teeth, which was more severe in the central incisors and in the right lateral incisor (Fig. 3). The patient experienced spontaneous pain in the maxillary left lateral incisor, and she was started on an endodontic treatment in this tooth before the orthodontic records were taken. Lateral cephalometric analysis showed a skeletal class III (Wits, -5 mm; unit difference Mx/Md diff, 22 mm) with a high mandibular plane angle (Go-Gn.SN, 44°) and proclined incisors both in the maxilla (1.NA, 31°; 1-NA, 6 mm) and in the mandible (1.NB, 34°; 1-NB, 8 mm; IMPA, 90°) (Table 1).

Treatment Objectives

The treatment objectives were to improve the facial esthetics, the correction of class III molar and canine relationships, correction of

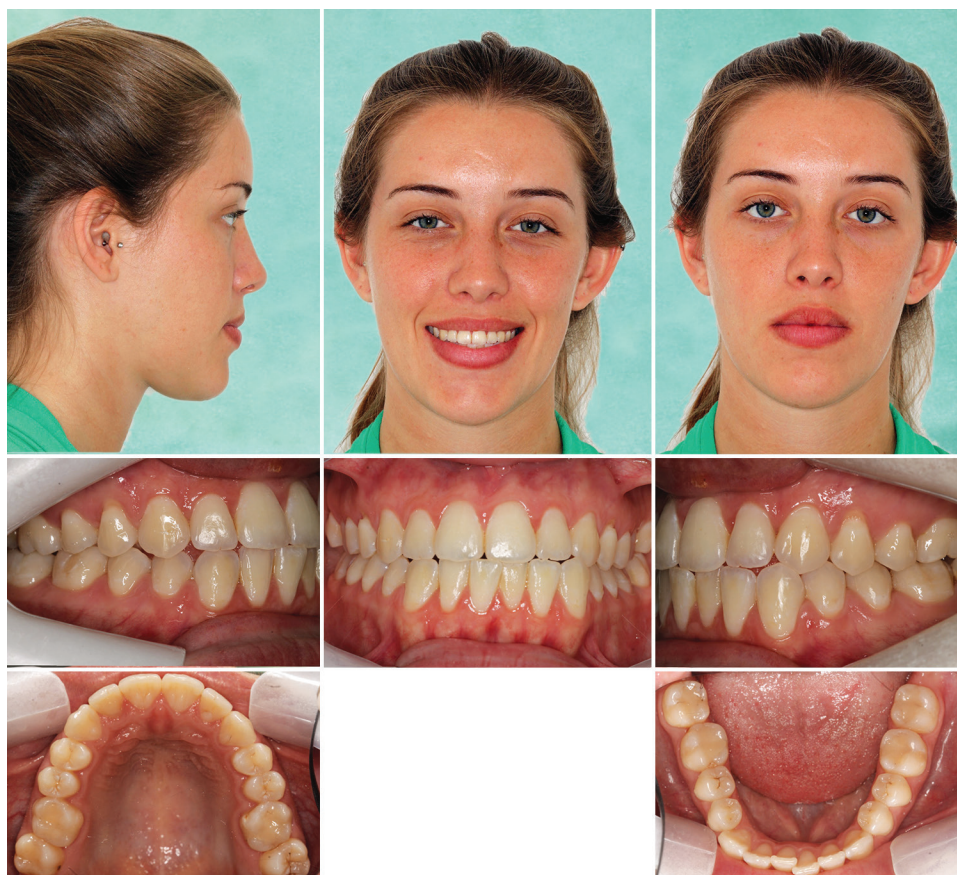

Fig. 1: Pretreatment facial and intraoral photographs

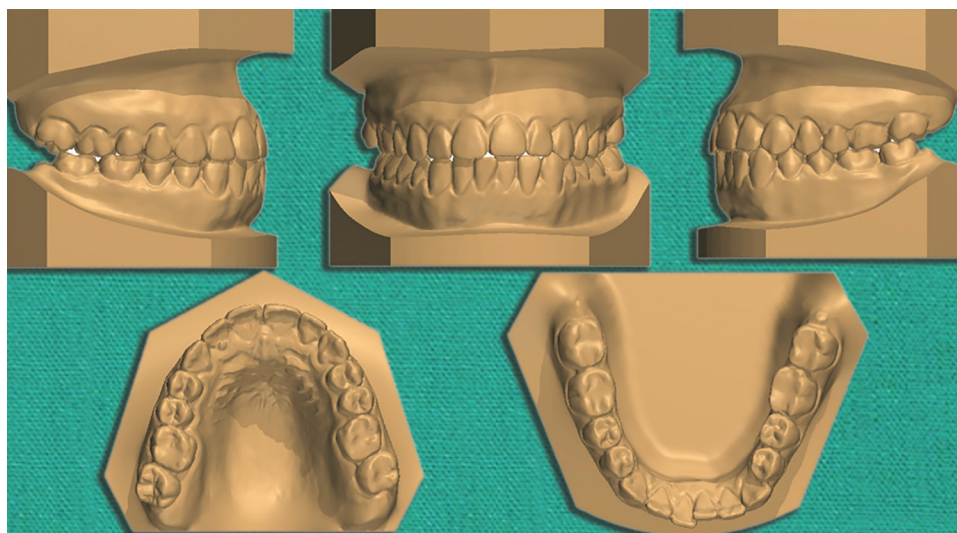


Fig. 2: Pretreatment dental casts

edge-to-edge incisor bite, dissipation of mandibular dental crowding, establishment of a functional occlusion, and preservation of maxillary teeth. Treatment objectives relied on distalization of the entire mandibular dentition. No treatment was performed on the maxilla because central and lateral incisors had severe root resorption.

Treatment Alternatives

The primary treatment option was the use of skeletal anchorage for distalization of the mandibular teeth and achievement of

class I molar and canine relationships, normal overjet and normal overbite.⁷⁹ A treatment alternative was the extraction of mandibular first premolars to create spaces for retraction of the anterior teeth.¹⁰ However, intercuspation of posterior teeth is unfavorable in a class III molar relationship. Furthermore, the patient refused dental extractions and agreed to a conservative orthodontic retreatment using skeletal anchorage in the mandible and no appliances in the maxilla.

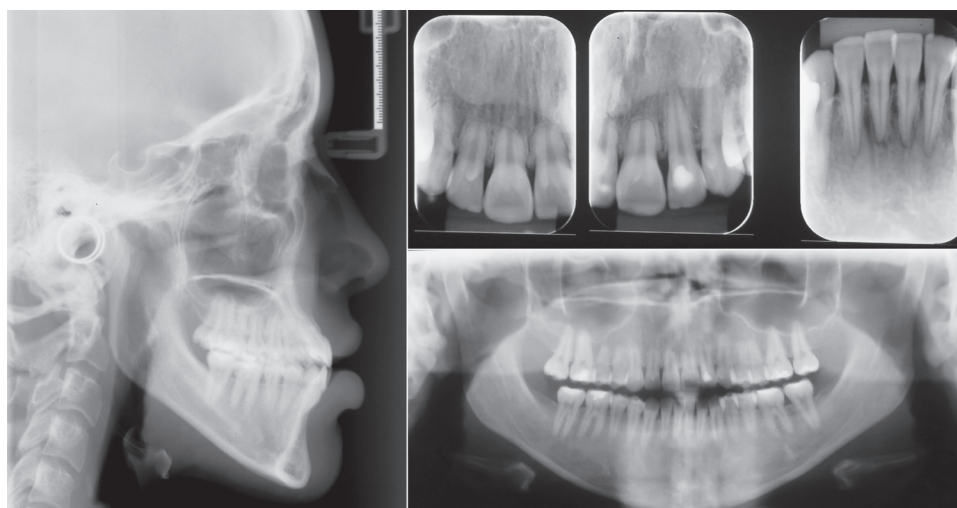


Fig. 3: Pretreatment radiographs

Table 1: Cephalometric measures

Measure	Norm	Initial	Posttreatment
SNA (°)	82	80	80
SNB (°)	80	79	79
ANB (°)	2	1	1
GoGn.SN (°)	32	44	43
1.NA (°)	22	31	31
1-NA (mm)	4	6	6
1.NB (°)	25	34	28
1-NB (mm)	4	8	6
FMA (°)	25	32	30
FMIA (°)	65	57	65
IMPA (°)	90	90	84
Wits (mm)	0	-5	-2
Mx/Md diff (mm)	10	22	22
Low lip E-plane (mm)	0	2	-0.5

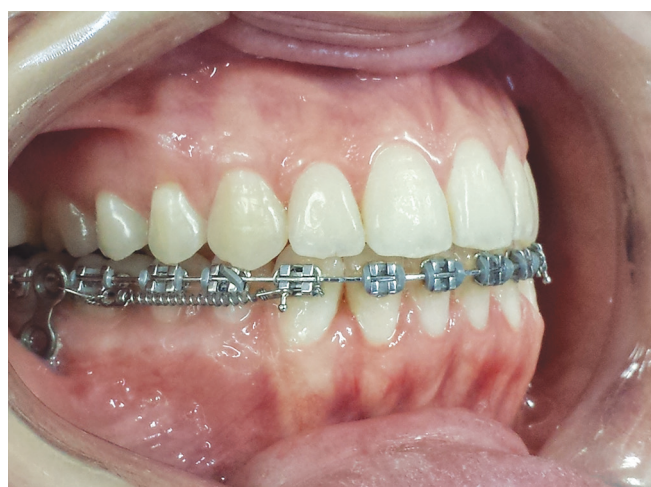

Fig. 4: Intraoral photographs of the mechanics. Mandibular canines tied to the miniplates with nickel-titanium closed coil springs for distalization

Treatment Progress

Initial records revealed that mandibular third molars were absent and there was enough space for distalization of the lower dentition. Edgewise standard brackets 0.022 × 0.028-in (American Orthodontics, Sheboygan, WI, USA) were bonded to all mandibular teeth, and no appliances were placed in the maxilla. Leveling and alignment were carried out using a sequence of nickel-titanium (0.014, 0.16-in) and stainless steel (SS) (0.016, 0.018-in) archwires. Miniplates (Engimpan, São Paulo, Brazil) were placed on both sides of the mandible, in the buccal cortical bone, in the second-molar region.⁶ After a 3-week period, the right miniplate failed and was immediately replaced.¹¹ Mandibular canines, premolars, and molars were distalized en masse using sliding mechanics on rectangular 0.016 × 0.022 in SS archwires. Both elastomeric chains (Memory Chain, American Orthodontics, Sheboygan, WI, USA) and nickel-titanium closed coil springs (Orthometric, Marília, SP, Brazil) were attached from the miniplates to the bracket hooks of the mandibular canines (Fig. 4). Forces of around 150 gf ran parallel to occlusal plane and passed above the center of the resistance of the teeth. As class I molar and canine relationships were achieved, mandibular

canines were tied to the miniplates with wire ligatures. Retraction of mandibular incisors was performed with an elastomeric chain (American Orthodontics) that was adapted tooth-by-tooth from the right to the left canine. On the right side, class III molar and canine relationships required distalization of mandibular teeth to a greater extent, which resulted in a greater space mesial to the canine. Due to this, correction of mandibular dental midline occurred along with retraction of incisors. Finishing was accomplished with a rectangular 0.016 × 0.022-in SS archwire. Retention was a 3-3 lingual bar (SS 0.6 mm) bonded to the mandibular canines. The miniplate on the left side was removed and the miniplate on the right side was left partially in place, due to osseointegration.

Treatment Results

At debonding, the patient showed attractive dentofacial esthetics and a functional occlusion. Mandibular teeth were aligned and leveled, a class I canine and molar relationship was achieved, mandibular dental midline was corrected, and the overjet and the overbite were normal (Figs 5 and 6). The panoramic radiograph revealed that mandibular teeth had parallel roots with no signs

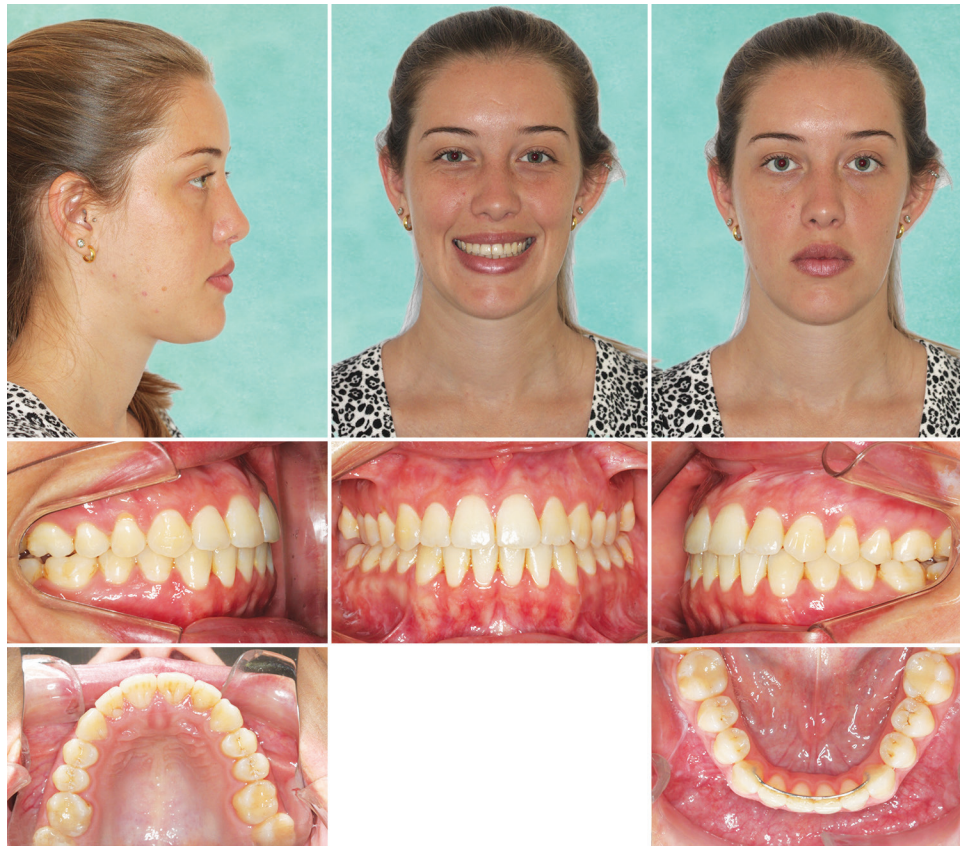

Fig. 5: Posttreatment facial and intraoral photographs

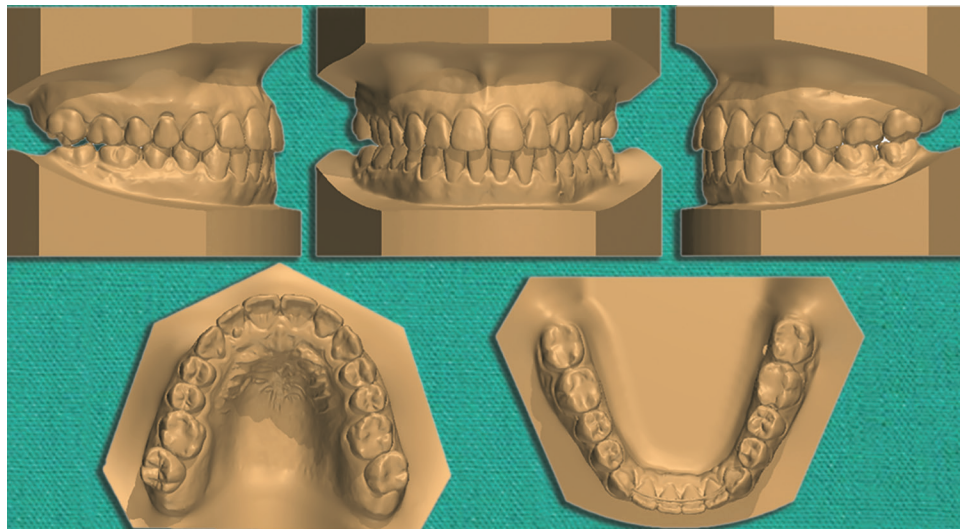


Fig. 6: Posttreatment dental casts

of resorption (Fig. 7). Cephalometric analysis and superimposition demonstrated a retraction of the mandibular incisors (1-NB, 2 mm; 1.NB, 6°; IMPA, 6°) and a distalization of the mandibular first molars (3 mm) (Fig. 8 and Table 1). One-year follow-up records exhibited stability of the treatment outcomes in the short term (Fig. 9, Videos 1 and 2).

DISCUSSION

This conservative orthodontic retreatment has improved the patient's dentofacial esthetics and occlusion by working around

the primary complaint of orthodontic relapse. Health conditions of the mandibular teeth and periodontal support tissues favored their distalization and allowed a conservative approach in the maxilla. Extensive root resorption in the maxillary incisors was probably a consequence of individual susceptibility, edge-to-edge bite, and perhaps long orthodontic treatment time.^{12,13}

The use of miniplates for skeletal anchorage enabled 3-dimensional mechanical control during distalization of the mandibular teeth.⁹ Superimpositions of cephalograms demonstrated a 3 mm distalization of mandibular molars (Fig. 6),

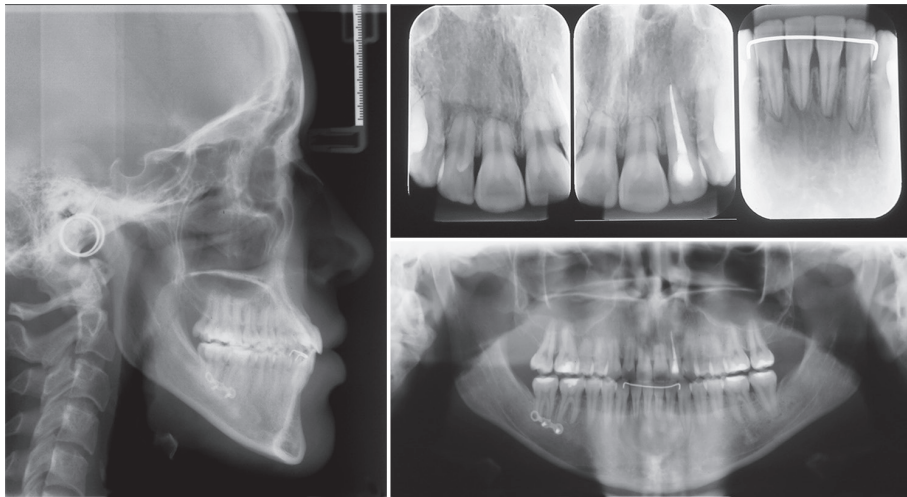


Fig. 7: Posttreatment radiographs

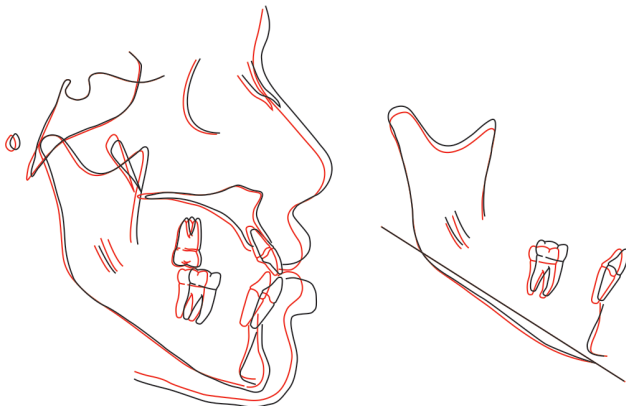


Fig. 8: Superimposition of cephalometric tracings before treatment (black) and after treatment (red)

which is close to that of 3.5 mm reported by Sugawara et al.⁷ Position of miniplates rarely interferes with orthodontic tooth movement, which is an advantage in relation to other TADs.

Successful absolute anchorage following failure in one miniplate reflects the controversial high and low success rates reported in different studies.¹¹ Screw loosening could be due to the insertion technique, the force magnitude and duration, oral hygiene, and cortical bone thickness.¹⁴ Patients report of pain, and discomfort is compatible with local infection, which was a possible cause of miniplate loss.

One-year follow-up records showed stability of retreatment outcomes and no orthodontic relapse in the short term (Fig. 9). Sugawara et al. reported a 0.3 mm mesial relapse of mandibular molars after 1 year.⁷ The stability of treatment outcomes has a good prognosis because distalization of the mandibular teeth was carried out through translation rather than teeth inclination. Additionally,

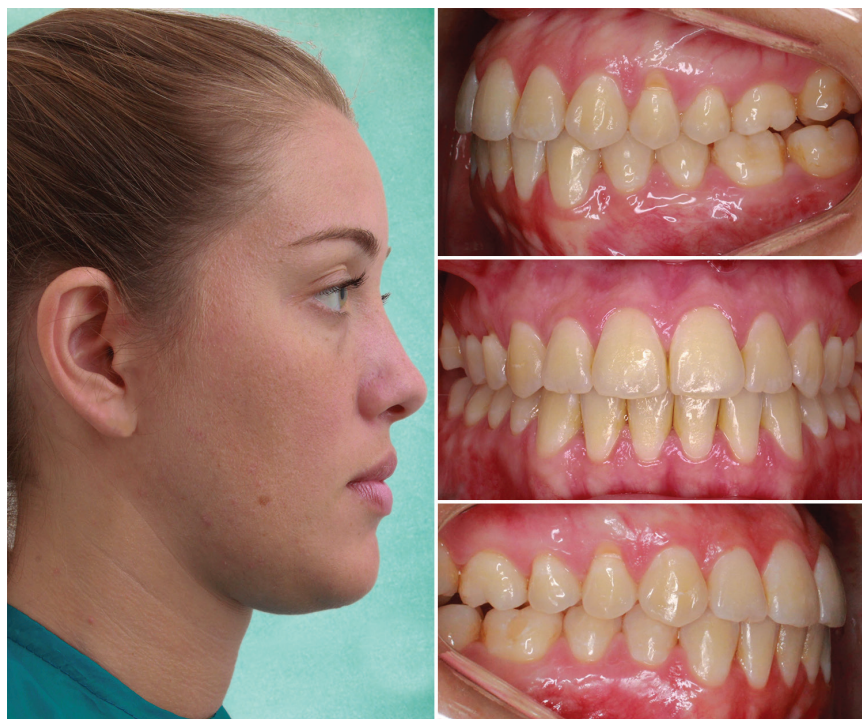

Fig. 9: One-year follow-up photographs

mandibular dental arch form did not change, enabling the balance between the perioral muscles and the tongue.

Decision-making with regard to a conservative approach in the maxilla did not include the correction of the dental midline. That limitation was also a weakness of this treatment option. However, a 2-mm midline deviation is within the range of not being perceptible by lay people and general dentists, and accepted by orthodontists.¹⁵ Indeed, the patient and the orthodontic team understood that dental midline deviation was acceptable. Overall, the present case report reinforced the usefulness of miniplates as an anchorage for controlled distalization of mandibular teeth. Moreover, a clinically significant distalization of mandibular teeth allowed a conservative approach in the maxilla.

CONCLUSION

Conservative orthodontic retreatment of a class III malocclusion associated with severe resorption of maxillary incisors was accomplished successfully in a 23-year-old woman, using skeletal anchorage in the mandible and no appliances in the maxilla. Miniplates were useful for distalization of all mandibular teeth and maxillary incisors were preserved.

Video 1: Patient's pre-treatment 3D model

Video 2: Patient's post-treatment 3D model

REFERENCES

1. Roscoe MG, Meira JBC, Cattaneo PM. Association of orthodontic force system and root resorption: a systematic review. *Am J Orthod Dentofac Orthop* 2015;147(5):610–626.
2. Weltman B, Vig KWL, Fields HW, et al. Root resorption associated with orthodontic tooth movement: a systematic review. *Am J Orthod Dentofac Orthop* 2010;137(4):462–476.
3. Ren Y, Boxum C, Sandham A. Patients' perceptions, treatment need, and complexity of orthodontic re-treatment. *Eur J Orthod* 2009;31(2):189–195.
4. Klages U, Bruckner A, Guld Y, et al. Dental esthetics, orthodontic treatment, and oral-health attitudes in young adults. *Am J Orthod Dentofac Orthop* 2005;128(4):442–449.
5. Kearney M-K, Pandis N, Fleming PS. Mixed-methods assessment of perceptions of mandibular anterior malalignment and need for orthodontic retreatment. *Am J Orthod Dentofac Orthop* 2016;150(4):592–600.
6. Ruiz RL, Petrone J, Sohn J. Temporary Skeletal Anchorage Devices for Orthodontics. *Oral Maxillofac Surg Clin North Am* 2010;22(1):91–105.
7. Sugawara J, Daimaruya T, Umemori M, et al. Distal movement of mandibular molars in adult patients with the skeletal anchorage system. *Am J Orthod Dentofac Orthop* 2004;125(2):130–138.
8. Suh H-Y, Lee S-J, Park HS, et al. Use of mini-implants to avoid maxillary surgery for class III mandibular prognathic patient: a long-term post-retention case. *Korean J Orthod* 2014;44(6):342.
9. Kook Y-A, Park JH, Bayome M, et al. Distalization of the mandibular dentition with a ramal plate for skeletal class III malocclusion correction. *Am J Orthod Dentofac Orthop* 2016;150(2):364–377.
10. Farret MMB, Farret MM, Farret AM. Strategies to finish orthodontic treatment with a class III molar relationship: three patient reports. *World J. Orthod.* 2009;10(4):323–333.
11. Schätzle M, Männchen R, Zwahlen M, et al. Survival and failure rates of orthodontic temporary anchorage devices: a systematic review. *Clin Oral Implants Res* 2009;20(12):1351–1359.
12. Marques LS, Chaves KCT, Rey AC, et al. Severe root resorption and orthodontic treatment: clinical implications after 25 years of follow-up. *Am J Orthod Dentofac Orthop* 2011;139(4):S166–S169.
13. Nigul K, Jagomagi T. Factors related to apical root resorption of maxillary incisors in orthodontic patients. *Stomatologija* 2006;8(3):76–79.
14. Choi BH, Zhu SJ, Kim YH. A clinical evaluation of titanium miniplates as anchors for orthodontic treatment. *Am J Orthod Dentofac Orthop* 2005;128(3):382–384.
15. Kokich VO, Asuman Kiyak H, Shapiro PA. Comparing the perception of dentists and lay people to altered dental esthetics. *J Esthet Restor Dent* 1999;11(6):311–324.

NOTE: Video file 1: Patient's pre-treatment 3D model (available online only)
Video file 2: Patient's post-treatment 3D model (available online only)