



Contents lists available at ScienceDirect

Prostate International

journal homepage: <https://www.journals.elsevier.com/prostate-international>

## Research Article

# The role of <sup>68</sup>Gallium-prostate-specific membrane antigen positron emission tomography on staging of high-risk localized prostate cancer: for all high-risk patients or would it be better to select them?



Fernando Sabino M. Monteiro <sup>1,2,5,\*</sup>, Juçara Motta Serafim Eliam <sup>2</sup>,  
 Rafaela Gomes de Jesus <sup>1</sup>, Pedro Cavalcante <sup>3</sup>, Gustavo do Vale Gomes <sup>3</sup>,  
 Bruno Hochhegger <sup>4</sup>, Vinicius K. Gonçalves <sup>5</sup>, Laura Von Wallwitz Freitas <sup>5</sup>,  
 Diego H. Roman <sup>4</sup>, Andre Poisl Fay <sup>1,4,5</sup>

<sup>1</sup> Latin American Cooperative Oncology Group (LACOG), Genito-Urinary Section, Brazil

<sup>2</sup> Hospital Santa Lucia, Oncology and Hematology Department, Brazil

<sup>3</sup> Nucleos, Nuclear Medicine Department, Brazil

<sup>4</sup> Hospital São Lucas da PUCRS, Radiology and Nuclear Medicine Department, Brazil

<sup>5</sup> Pontificia Universidade Catolica do Rio Grande do Sul (PUCRS), School of Medicine, Oncology Department, Brazil

## ARTICLE INFO

## Article history:

Received 28 May 2020

Received in revised form

23 June 2020

Accepted 28 July 2020

Available online 13 August 2020

## Keywords:

<sup>68</sup>Ga-PSMA

high-risk

localized prostate cancer

PET/CT

primary staging

## ABSTRACT

**Background:** According to pathologico-clinical features, patients diagnosed with localized prostate cancer (PCa) are stratified into distinct risk groups (low-risk, intermediate-risk or high-risk). Data have demonstrated that <sup>68</sup>Gallium-prostate-specific membrane antigen positron emission tomography (<sup>68</sup>Ga-PSMA PET/CT) is superior to conventional radiological exams (CT or MRI and bone scintigraphy) in the primary staging of high-risk localized PCa. However, it is still unknown if in a population of high-risk PCa, there would be a subgroup of patients with a higher probability of identifying metastatic disease by the <sup>68</sup>Ga-PSMA PET/CT.

**Materials and Methods:** Data from patients with localized PCa who underwent <sup>68</sup>Ga-PSMA PET/CT for primary staging from four institutions were retrospectively collected. We selected patients with at least one D'Amico classification risk factor (International Society of Urological Pathology  $\geq$  IV and/or prostate-specific antigen  $>$  20 ng/ml). To detect an association between extent of disease and number of risk factors as well as International Society of Urological Pathology prostate cancer grade, contingency tables were used, and Fisher Exact Test was performed.

**Results:** Between 2016 and 2020, 60 patients underwent a <sup>68</sup>Ga-PSMA PET/CT for primary staging of high-risk localized PCa. Regarding the number of risk factors, 37 patients (62%) had one risk factor, and 23 (38%) had two risk factors. In the subgroup of patients with metastatic disease (n = 22), those with two risk factors had higher incidence of metastatic disease, and it was statistically significant (p = 0.011).

**Conclusion:** This retrospective analysis demonstrated that <sup>68</sup>Ga-PSMA PET/CT was able to identify advanced disease in more than one-third of patients with high-risk disease especially those with two adverse risk factors.

© 2020 Asian Pacific Prostate Society. Publishing services by Elsevier B.V. This is an open access article under the CC BY-NC-ND license (<http://creativecommons.org/licenses/by-nc-nd/4.0/>).

## 1. Introduction

Aside from nonmelanoma skin cancers, prostate cancer (PCa) is the second malignancy in men and the seventh leading cause of

cancer-related death worldwide[1]. At diagnosis, about 90% of patients have localized or locoregional disease, and potentially curative intent treatments are available[2]. According to serum prostate-specific antigen (PSA) levels, the extent of local disease, and Gleason score patients are stratified into distinct prognostic risk groups (low, intermediate, and high-risk) that will guide the complementary staging workup as well as treatment options[3, 4]. Recently, a new prognostic stratification has been proposed

\* Corresponding author. Oncology and Hematology Department, Hospital Santa Lucia, SHLS 716 Cj. C, 70390-700, Brasilia, DF, Brazil.

E-mail address: [fsabinocba@gmail.com](mailto:fsabinocba@gmail.com) (F.S.M. Monteiro).

defining six different stratification subgroups (very low-, low-, favorable intermediate-, unfavorable intermediate-, high- and very high-risk). Briefly, this more specific risk stratification takes into account the volume of disease and the impact of International Society of Urological Pathology (ISUP) classifications in prognosis[5]. In this context for very low and low-risk disease, no staging workup is recommended, and for favorable and unfavorable intermediate-risk disease, a bone scan and an abdominopelvic CT or magnetic resonance imaging (MRI) could be indicated[5]. For high-risk and very high-risk disease, considering the higher probability of regional lymph node (LN) involvement and distant metastasis, all patients should undergo an abdominopelvic CT or MRI and a bone scan[5].

In recent years, <sup>68</sup>Gallium-prostate-specific membrane antigen positron emission tomography (<sup>68</sup>Ga-PSMA PET/CT) has emerged as an excellent staging tool in biochemical relapse (BCR) scenario after local primary treatment (surgery or radiation therapy), with more specificity and sensitivity than traditional staging tools and a good disease detection rate even in the presence of low PSA[6, 7]. Considering the <sup>68</sup>Ga-PSMA PET/CT sensibility and specificity to detect recurrent disease in the BCR scenario and a higher probability to identify advanced and/or metastatic disease in high-risk localized PCa, the interest of investigating the role of <sup>68</sup>Ga-PSMA PET/CT on staging independently of prognostic risk groups classification has emerged. Recently, a multicenter phase III randomized clinical trial has evaluated the accuracy of <sup>68</sup>Ga-PSMA PET/CT on primary staging in patients with high-risk localized PCa. This study showed that <sup>68</sup>Ga-PSMA PET/CT has higher accuracy than conventional imaging exams (92 vs. 65%)[8].

Despite the encouraging data suggesting an advantage of using <sup>68</sup>Ga-PSMA PET/CT in the staging of high-risk patients, it is still unknown whether there could be a subgroup of patients with any characteristics that would increase the possibility of identifying metastatic disease by the <sup>68</sup>Ga-PSMA PET/CT and, therefore, change treatment plans.

In this study, we sought to analyze the impact of <sup>68</sup>Ga-PSMA PET/CT use in the staging of high-risk localized PCa and explore clinical factors to guide patient selection for this exam.

## 2. Materials and methods

This was a multicenter retrospective study including four Brazilian centers (Villas-Boas Institute, Nucleos Institute, Hospital São Lucas da PUCRS, and Hospital Mae de Deus). Data from patients with PCa diagnostic who underwent <sup>68</sup>Ga-PSMA PET/CT between 2016 and 2020 were retrospectively collected. We selected patients with at least one of two D'Amico classification risk factors (ISUP  $\geq$  IV and/or PSA  $>$  20 ng/ml) who underwent <sup>68</sup>Ga-PSMA PET/CT for primary staging. No other traditional radiologic tools (CT, MRI, or bone scan) for extrapelvic primary staging was performed. Considering the <sup>68</sup>Ga-PSMA PET/CT results, the patients were divided according to the extent of disease: localized (primary tumor  $\pm$  pelvic LNs) or metastatic (primary tumor and extra-pelvic LNs  $\pm$  bone disease  $\pm$  visceral disease) and also stratified according to the number of risk factors (1 vs. 2) and the ISUP prostate cancer grade (IV vs. V). The study was approved by regional ethic board and was carried out in accordance with the Declaration of Helsinki and Good Clinical Practice.

### 2.1. <sup>68</sup>Ga-PSMA PET/CT image acquisition and analysis

Radiolabeling of <sup>68</sup>Ga-PSMA, acquisition of <sup>68</sup>Ga-PSMA PET/CT, and image evaluations were performed at the four centers according to the Society of Nuclear Medicine and Molecular

Imaging and the European Association of Nuclear Medicine procedure guideline[9].

In all centers, experienced nuclear medicine and radiology specialists read each image individually. If the findings were discordant, the final decision was achieved by consensus. The <sup>68</sup>Ga-PSMA PET/CT scans were analyzed visually, and the findings were classified as (1) primary tumor only, (2) pelvic LN metastasis, (3) extrapelvic LN metastasis only, (4) bone metastasis only, (5) LN and bone metastasis, and (6) visceral lesions.

### 2.2. Statistical analysis

To detect an association between extent of disease and number of risk factors, as well as ISUP prostate cancer grade, contingency tables were used, and Fisher Exact Test was performed. All analyses were performed using the SAS statistical software (version 9.4; SAS Institute, Inc. Cary, NC). A significance level of 5% was applied.

## 3. Results

Between 2016 and 2020, the selected centers performed 914 <sup>68</sup>Ga-PSMA PET/CT exams. Excluding scans for primary staging of low or intermediate-risk localized PCa, BCR, and metastatic disease and patients with nonadenocarcinoma histology or without ISUP prostate cancer grade information, there were 62 patients who underwent <sup>68</sup>Ga-PSMA PET/CT for primary staging of high-risk localized PCa. Out of high-risk population, there were two patients classified as high-risk localized PCa because prostate MRIs have found T3a and T3b but with PSA  $\leq$  20 ng/ml and ISUP  $<$  IV, so these patients were excluded from the final analysis (Fig. 1). The clinical characteristics of the 60 selected patients are summarized in Table 1.

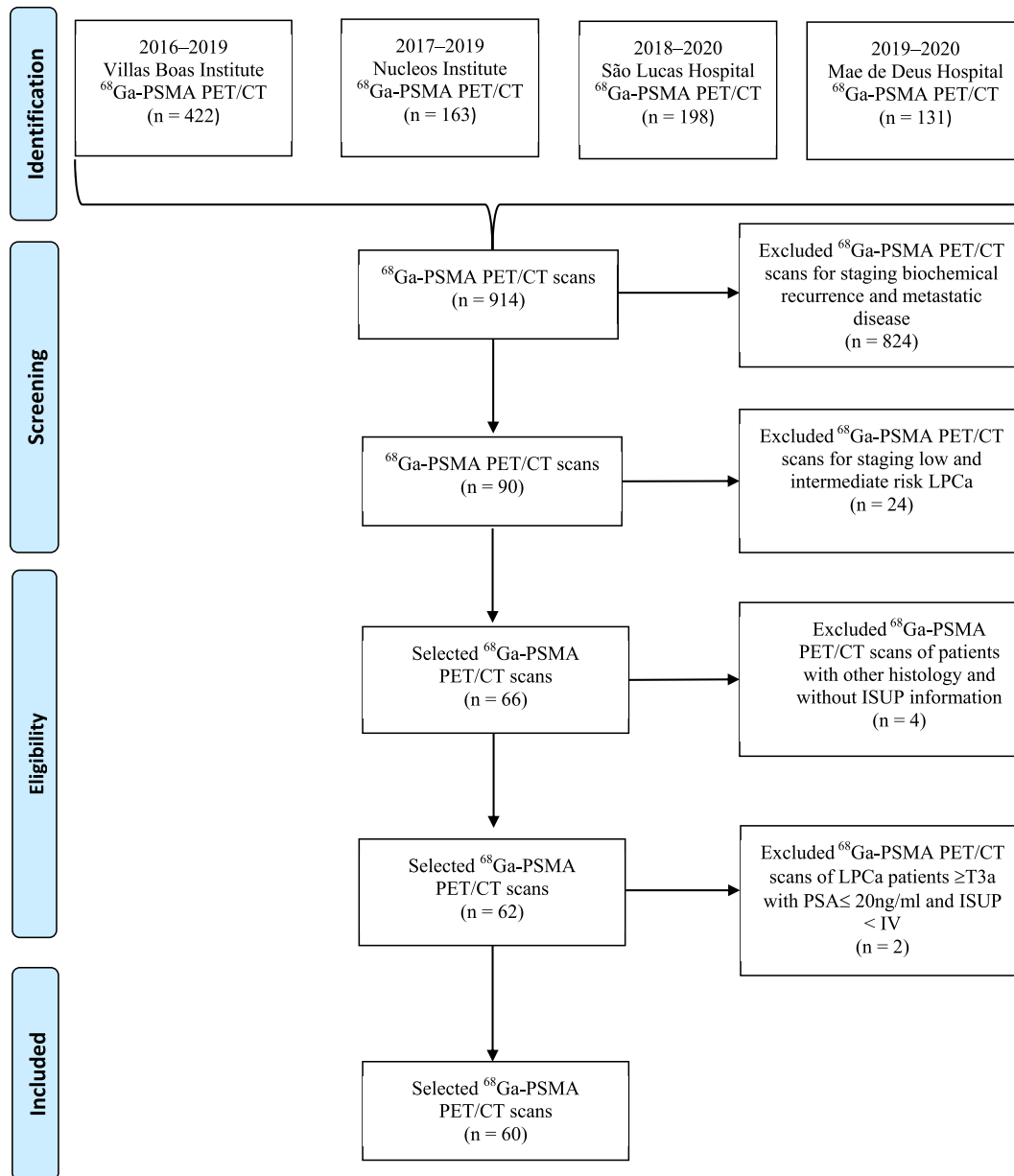
Among these 60 patients, 26 (43%) had localized primary tumor only, 12 (20%) had locoregional node disease, and 22 (37%) had metastatic disease. In the subgroup of patients with metastatic disease, 7 (12%) had extrapelvic nodes, 7 (12%) had bone disease, 8 (13%) had extrapelvic nodes and bone disease, and none had visceral metastasis. Regarding the number of risk factors, 37 patients (62%) had only one adverse risk factor, and 23 patients (38%) had two adverse risk factors. In the subgroup of patients with metastatic disease, nine had one adverse risk factor and 13 had two adverse risk factors. The information about risk factors and sites of disease are summarized in Table 2.

The association between the number of risk factors and metastatic disease identified by the <sup>68</sup>Ga-PSMA PET/CT is shown in Fig. 2. Out of the 22 patients with metastatic disease, 6 patients had ISUP  $\geq$  IV, 3 patients had PSA  $>$  20 ng/ml, and 13 patients had both ISUP  $\geq$  IV and PSA  $>$  20 ng/ml. The presence of 2 adverse risk factors was associated with a higher incidence of metastatic disease compared with those with one risk factor ( $P = 0.011$ ).

Regarding the ISUP prostate cancer grade, nine patients (15%) had ISUP  $<$  IV, 32 patients (53%) had ISUP IV, and 19 patients (32%) had ISUP V. The association between ISUP IV or V and metastatic disease is shown in Fig. 3. In this context, out of the 51 patients with ISUP  $\geq$  IV, 18 patients had metastatic disease. There was a non-statistically significant trend of presence of metastatic disease in patients with ISUP grade IV or V ( $P = 0.07$ ).

## 4. Discussion

This study evaluated the value of <sup>68</sup>Ga-PSMA PET/CT in primary staging of high-risk localized PCa before any local treatment of prostate primary tumor (radical prostatectomy or radiation therapy) and explore pathological-clinical features that may be associated with clinical benefit of this new technology. In this analysis,



**Fig. 1.**  $^{68}\text{Ga}$ -PSMA PET/CT scans identification and selection.  $^{68}\text{Ga}$ -PSMA PET/CT,  $^{68}\text{Ga}$  Gallium-prostate-specific membrane antigen positron emission tomography; ISUP, International Society of Urological Pathology.

37% of high-risk localized PCa patients had metastatic disease identified by  $^{68}\text{Ga}$ -PSMA PET/CT, reflecting a higher incidence of advanced disease in this specific population of patients. These data go in the same direction to recent one from large retrospective trial that identified metastatic disease in 43% of patients with PSA >20 ng/ml [10]. On the other hand, these data have shown a slightly higher incidence of metastatic disease compared with previously published retrospective series and one prospective trial that included both intermediate and high-risk localized PCa that identified metastatic disease rates varying from 17 to 30% [11–15]. This difference could probably be explained by the inclusion of patients with intermediate-risk localized PCa in these trials. However, the recent multicentric phase III randomized clinical trial evaluating the primary staging with  $^{68}\text{Ga}$ -PSMA PET/CT in 302 patients, all of them with localized high-risk PCa, identified metastatic disease in 20% of the patients [8]. Therefore, identifying a selected subgroup of patients within the high-risk population may help to define the

best setting for the use of  $^{68}\text{Ga}$ -PSMA PET/CT and probably the identification of metastatic disease. In this context, our data suggest that patients with two adverse risk factors have higher probability to have extra-pelvic metastatic disease rather than patients with one adverse risk factor (22 vs. 15%,  $p = 0.011$ ). Considering that  $^{68}\text{Ga}$ -PSMA PET/CT is an expensive exam with limited availability without reimbursement by the majority of health insurance companies, this finding is relevant because it allows a better selection of the patients that may benefit the most from this technology. This information may be also important in the design of other future prospective trial evaluating the role of this exam in subgroups of high-risk localized PCa patients (for instance: high-risk vs. very high-risk patients). Interestingly, our analysis failed to demonstrate difference in the risk of metastasis according to the ISUP prostate cancer grade IV or V (16 vs. 22%,  $p = 0.07$ ).

The identification of metastatic disease is important because all patients with evidence of extra-pelvic metastatic disease had their

**Table 1**  
Trial population clinical characteristics—n (%).

Clinical characteristics (n = 60)	Extension of disease	
	Localized (n = 38)	Metastatic (n = 22)
Age, yrs		
Median	70	70
Interquartil range	65-79	63-79.5
PSA, ng/ml		
Median	16.53	56
Interquartil range	7.09-31	14.54-137.3
ISUP*		
I	1 (2)	0
II	1 (2)	1 (2)
III	3 (5)	3 (5)
IV	24 (40)	8 (13)
V	9 (15)	10 (16)
Prostate MRI		
T3a	1 (2)	0
T3b	2 (3)	4 (6)
T4	0	3 (5)
Risk Factors (ISUP ≥ 4 and/or PSA >20ng/ml)		
One	28 (47)	9 (15)
Two	10 (16)	13 (22)

PSA, prostate-specific antigen; MRI, magnetic resonance imaging.  
\* International Society of Urological Pathology Prostate Cancer Grade.

initial treatment planning modified. For example, the two Australian prospective trials demonstrated clinical management intent changed in 14 and 26% of the patients [8, 15]. These patients were ruled out for any local treatment for the prostate primary tumor

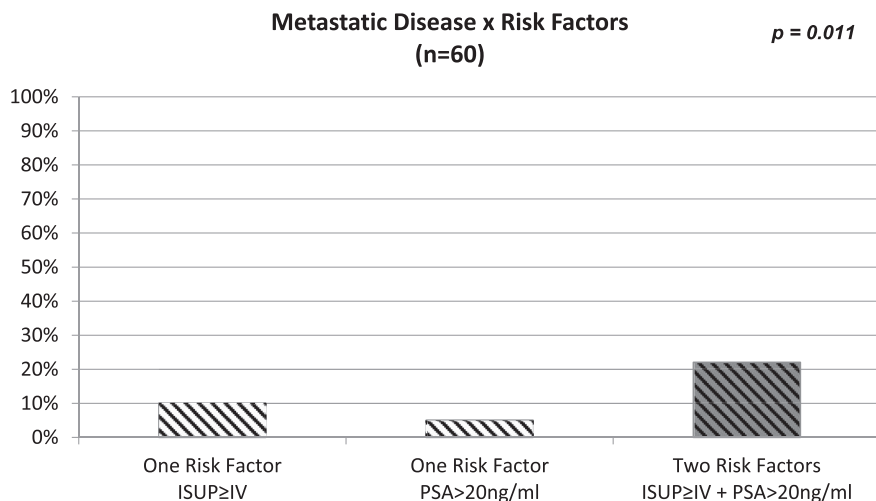
(radical prostatectomy or RT) and started systemic treatment. In this context, the early diagnosis of metastatic disease is important, considering that in the last decade, several new systemic treatments, including docetaxel plus androgen deprivation therapy or novel hormonal agents plus androgen deprivation therapy, have been approved to the treatment of advanced hormone-sensitive PCa resulting in longer overall survival and improved clinical outcome, especially in patients with “*de novo*” metastatic disease [16-21].

Although this is a relevant data from a real-world scenario, this study has several limitations. First, this is a retrospective analysis, and selection bias may be affected our conclusions. An example of this possible selection bias is the fact that 57% of our sample of patients showed at least on positive finding in addition to the primary tumor (20% of N1 and 37% of M1 staging). This finding is quite high considering the low sensitivity of <sup>68</sup>Ga-PSMA PET/CT on LN staging even in high-risk disease [22]. In our study, there was no histopathological confirmation of <sup>68</sup>Ga-PSMA PET/CT findings that were called as positive LNs or distant metastasis, limiting the determination of sensitivity and specificity of this imaging exam in this cohort. Furthermore, we were not able to capture the changes in the clinical management and the impact in clinical outcome, and this should be addressed in further prospective studies to confirm our findings. Finally, other limitation was the lack of traditional radiologic exams (CT, MRI or bone scan) on the primary disease staging to establish a comparison between the different methods in an important limitation considering that conventional imaging exams may be able to detect some changes that were detected by <sup>68</sup>Ga-PSMA PET/CT.

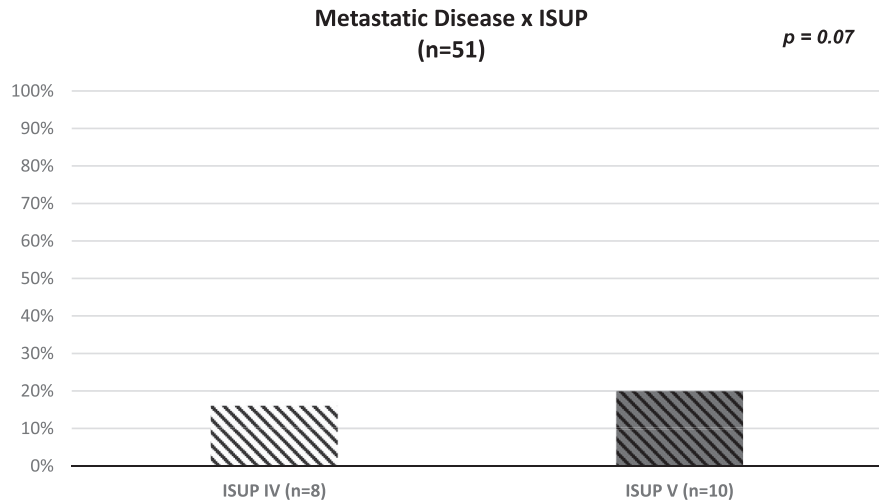
**Table 2**  
High risk factors and sites of disease—n (%)

Site of Disease	N	High Risk Factors		
		ISUP ≥ 4	PSA > 20ng/ml	ISUP ≥ 4 and PSA > 20ng/ml
Localized Disease	38 (63)			
Primary Tumor Only	26 (43)	18 (30)	4 (6.5)	4 (6.5)
Pelvic Nodes	12 (20)	4 (7)	2 (3)	6 (10)
Metastatic Disease	22 (37)			
Extra-Pelvic Nodes Only	7 (12)	0	1 (2)	6 (10)
Bone Only	7 (12)	5 (8)	0	2 (4)
Extra-Pelvic Nodes + Bone	8 (13)	1 (2)	2 (3)	5 (8)
Visceral	0	0	0	0
Total no. of patients—n (%)	60	28	9	23

PSA, prostate-specific antigen; ISUP, International Society of Urological Pathology.



**Fig. 2.** Association between D’Amico risk factors and metastatic disease. ISUP, International Society of Urological Pathology; PSA, prostate-specific antigen.



**Fig. 3.** Association between ISUP prostate cancer grade and metastatic disease. ISUP, International Society of Urological Pathology.

Another issue is the lack of information about the clinical T or N staging of the primary tumor (T3a, T3b or T4, and N0 or N1) with pelvic CT scan or multiparametric prostate MRI were not available for the majority of patients. Thus, we decided to not use this criteria in the predefined inclusion criteria to define prognostic risk score for this analysis. This may underestimate the high-risk population and the impact of  $^{68}\text{Ga}$ -PSMA PET/CT.

## 5. Conclusion

In conclusion, this large retrospective analysis suggests that  $^{68}\text{Ga}$ -PSMA PET/CT was able to identify more than one-third of advanced disease in the staging of a high-risk population of PCa patients. This result could help our colleagues to optimize the clinical management in that specific population. In addition, the number of adverse risk factors appear to help in the selection of patients who may benefit of this new technology. Further prospective trials are warranted to define the role of  $^{68}\text{Ga}$ -PSMA PET/CT in the staging of prostate cancer patients.

## Ethical approval and informed consent

This retrospective study involving human participants was in accordance with the ethical standards of the regional ethic board. The ethics and research board of Distrito Federal University (UDF) approved this study. Informed consent was waived with knowledge and agreement of the ethics and research board.

## Conflicts of interest

The authors declare that they have no conflict of interest.

## Acknowledgments

All the authors would like to acknowledge Dr. Carlos Henrique Pancini V. De Cerqueira for his help with the data from Villas-Boas Institute.

## References

1. Ferlay J, Colombet M, Soerjomataram I, Mathers C, Parkin DM, Pineros M, et al. Estimating the global cancer incidence and mortality in 2018: GLOBOCAN sources and methods. *Int J Canc* 2019;144(8):1941–53.
2. Siegel RL, Miller KD, Jemal A. Cancer statistics, 2019. *CA A Cancer J Clin* 2019;69(1):7–34.
3. D'Amico AV, Whittington R, Malkowicz SB, Schultz D, Blank K, Broderick GA, et al. Biochemical outcome after radical prostatectomy, external beam radiation therapy, or interstitial radiation therapy for clinically localized prostate cancer. *JAMA* 1998;280(11):969–74.
4. Mottet N, Bellmunt J, Bolla M, Briers E, Cumberbatch MG, De Santis M, et al. EAU-ESTRO-SIOG Guidelines on Prostate Cancer. Part 1: Screening, Diagnosis, and Local Treatment with Curative Intent. *Eur Urol* 2017;71(4):618–29.
5. NCCN guidelines on prostate cancer, version 1.2020. National Comprehensive Cancer Network Website; 2020.
6. Afshar-Oromieh A, Avtzi E, Giesel FL, Holland-Letz T, Linhart HG, Eder M, et al. The diagnostic value of PET/CT imaging with the ( $^{68}\text{Ga}$ )-labelled PSMA ligand HBED-CC in the diagnosis of recurrent prostate cancer. *Eur J Nucl Med Mol Imag* 2015;42(2):197–209.
7. Eiber M, Maurer T, Souvatzoglou M, Beer AJ, Ruffani A, Haller B, et al. Evaluation of Hybrid ( $^{68}\text{Ga}$ )-PSMA Ligand PET/CT in 248 Patients with Biochemical Recurrence After Radical Prostatectomy. *J Nucl Med* 2015;56(5):668–74.
8. Hofman MS, Lawrentschuk N, Francis RJ, Tang C, Thomas P, Rutherford N, et al. Prostate-specific membrane antigen PET-CT in patients with high-risk prostate cancer before curative-intent surgery or radiotherapy (proPSMA): a prospective, randomised, multi-centre study. *Lancet* 2020;395(10231):1208–16.
9. Fendler WP, Eiber M, Beheshti M, Bomanji J, Ceci F, Cho S, et al.  $^{68}\text{Ga}$ -PSMA PET/CT: Joint EANM and SNMMI procedure guideline for prostate cancer imaging: version 1.0. *Eur J Nucl Med Mol Imag* 2017;44(6):1014–24.
10. Yaxley JW, Raveenthiran S, Nouhaud FX, Samaratunga H, Yaxley WJ, Coughlin G, et al. Risk of metastatic disease on ( $^{68}\text{Ga}$ ) gallium-prostate-specific membrane antigen positron emission tomography/computed tomography scan for primary staging of 1253 men at the diagnosis of prostate cancer. *BJU Int* 2019;124(3):401–7.
11. Kabasakal L, Demirci E, Ocak M, Akyel R, Nematyazar J, Aygun A, et al. Evaluation of PSMA PET/CT imaging using a  $^{68}\text{Ga}$ -HBED-CC ligand in patients with prostate cancer and the value of early pelvic imaging. *Nucl Med Commun* 2015;36(6):582–7.
12. Uprimny C, Kroiss AS, Decristoforo C, Fritz J, von Guggenberg E, Kendler D, et al. ( $^{68}\text{Ga}$ )-PSMA-11 PET/CT in primary staging of prostate cancer: PSA and Gleason score predict the intensity of tracer accumulation in the primary tumour. *Eur J Nucl Med Mol Imag* 2017;44(6):941–9.
13. Ferraro DA, Garcia Schüler HI, Muehlemaier UJ, Eberli D, Müller J, Müller A, et al. Impact of  $^{68}\text{Ga}$ -PSMA-11 PET staging on clinical decision-making in patients with intermediate or high-risk prostate cancer. *Eur J Nucl Med Mol Imag* 2020;47(3):652–64.
14. Cytawa W, Seitz AK, Kircher S, Fukushima K, Tran-Gia J, Schirbel A, et al. ( $^{68}\text{Ga}$ )-PSMA I&T PET/CT for primary staging of prostate cancer. *Eur J Nucl Med Mol Imag* 2020;47(1):168.
15. Roach PJ, Francis R, Emmett L, Hsiao E, Kneebone A, Hruby G, et al. The Impact of ( $^{68}\text{Ga}$ )-PSMA PET/CT on Management Intent in Prostate Cancer: Results of an Australian Prospective Multicenter Study. *J Nucl Med* 2018;59(1):82–8.
16. Sweeney CJ, Chen YH, Carducci M, Liu G, Jarrard DF, Einsenberger M, et al. Chemohormonal Therapy in Metastatic Hormone-Sensitive Prostate Cancer. *N Engl J Med* 2015;373(8):737–46.
17. James ND, Sydes MR, Clarke NW, Mason MD, Dearnaley DP, Spears MR, et al. Addition of docetaxel, zoledronic acid, or both to first-line long-term hormone therapy in prostate cancer (STAMPEDE): survival results from an adaptive, multiarm, multistage, platform randomised controlled trial. *Lancet* 2016;387(10024):1163–77.
18. James ND, de Bono JS, Spears MR, Clarke NW, Mason MD, Dearnaley DP, et al. Abiraterone for Prostate Cancer Not Previously Treated with Hormone Therapy. *N Engl J Med* 2017;377(4):338–51.

- 19.. Fizazi K, Tran N, Fein L, Matsubara N, Rodriguez-Antolin A, Alekseev BY, et al. Abiraterone acetate plus prednisone in patients with newly diagnosed high-risk metastatic castration-sensitive prostate cancer (LATITUDE): final overall survival analysis of a randomised, double-blind, phase 3 trial. *Lancet Oncol* 2019;20(5):686–700.
- 20.. Davis ID, Martin AJ, Stockler MR, Begbie S, Chi KN, Chowdhury S, et al. Enzalutamide with Standard First-Line Therapy in Metastatic Prostate Cancer. *N Engl J Med* 2019;381(2):121–31.
- 21.. Chi KN, Agarwal N, Bjartell A, Chung BH, Pereira de Santana Gomes AJ, Given R, et al. Apalutamide for Metastatic, Castration-Sensitive Prostate Cancer. *N Engl J Med* 2019;381(1):13–24.
- 22.. Budaus L, Leyh-Bannurah SR, Salomon G, Michl U, Heinzer H, Huland H, et al. Initial Experience of (68)Ga-PSMA PET/CT Imaging in High-risk Prostate Cancer Patients Prior to Radical Prostatectomy. *Eur Urol* 2016;69(3):393–6.